



11-1-2022

## Subchondroplasty for treating bone marrow lesions in osteoarthritic knee – initial experience

Hazem Elhusainy

*Department of orthopedic surgery, Al azhar university hospital, hazemelhusainy@gmail.com*

Adnan Elsebaie

*Professor of Orthopaedics Faculty of Medicine, Al-Azhar University, adnansebaie@hotmail.com*

Faisal Zayed

*Orthopaedic departement- faculty of medicine- Al-azhar Univeristy, faisalzayed@yahoo.com*

Follow this and additional works at: <https://aimj.researchcommons.org/journal>



Part of the [Medical Sciences Commons](#), [Obstetrics and Gynecology Commons](#), and the [Surgery Commons](#)

### How to Cite This Article

Elhusainy, Hazem; Elsebaie, Adnan; and Zayed, Faisal (2022) "Subchondroplasty for treating bone marrow lesions in osteoarthritic knee – initial experience," *Al-Azhar International Medical Journal*: Vol. 3: Iss. 11, Article 5.

DOI: <https://doi.org/10.21608/aimj.2022.131156.1893>

This Original Article is brought to you for free and open access by Al-Azhar International Medical Journal. It has been accepted for inclusion in Al-Azhar International Medical Journal by an authorized editor of Al-Azhar International Medical Journal. For more information, please contact [dryasserhelmy@gmail.com](mailto:dryasserhelmy@gmail.com).

## Subchondroplasty for treating bone marrow lesions in osteoarthritic knee – initial experience

Hazem Mostafa Elhusainy,<sup>1</sup> MSc, Adnan Abdel Aleem Elsebaie,<sup>1</sup> MD, Faisal Hassan Zayed,<sup>1</sup> MD.

### \* Corresponding Author:

Hazem Mostafa Elhusainy

[haithemhassan2012@gmail.com](mailto:haithemhassan2012@gmail.com)

Received for publication April 9, 2022; Accepted November 7, 2022; Published online November 7, 2022.

doi: 10.21608/aimj.2022.131156.1893.

Citation: Hazem ME., Adnan AE and Faisal HZ. Subchondroplasty for treating bone marrow lesions in osteoarthritic knee – initial experience. AIMJ. 2022; Vol.3-Issue11 .30-34.

<sup>1</sup>Orthopedic Surgery Department, Faculty of Medicine, Al-Azhar University, Cairo, Egypt.

### ABSTRACT

**Background:** Osteoarthritis is a condition that impacts all of the tissues in a joint. Evidence suggests that the subchondral bone is the most important component in both pain genesis and disease progression

**Aim of the study:** Prospective outcome research to see how effective is subchondroplasty surgery at relieving pain and improving knee function in patients having osteoarthritis-related bone marrow lesions of the knee.

**Patients and Methods:** The study included 30 patients between the ages of 40 and 75 who had been suffering from atraumatic knee pain for at least three months, had failed conservative treatment for at least three months, had BML on MRI imaging in a loading area, and had localized pain in the BML area. The Western Ontario and McMaster Universities Osteoarthritis Index (WOMAC) score and visual analog scale (VAS) pain scores have been acquired preoperatively, at 2 weeks, 3 months, 6 months, and 12 months after surgery. Under fluoroscopic guidance, subchondroplasty was conducted by injecting nanocrystal hydroxyapatite cement into the bone marrow lesion's location.

**Results:** Following a one-year follow-up, the WOMAC scores improved considerably, from 62.03+- 11.19 to 21.83 +- 8.18 (p < 0.001). All of the patients' pain, stiffness, and physical functions improved significantly. Furthermore, after surgery, the mean VAS values showed a considerable improvement. At the end of the year, the patient improved from 6.98 +- 1.16 to 1.81 +- 1.00 (p < 0.01), which is highly statistically significant.

**Conclusion:** Subchondroplasty is a promising approach for treating osteoarthritis-related bone marrow lesions of the knee, providing significant pain relief and functional results with low rates of complications in the short term results.

**Keywords:** Subchondroplasty · Bone marrow lesions · Osteoarthritis · Hydroxyapatite cement.

**Disclosure:** The authors have no financial interest to declare in relation to the content of this article. The Article Processing Charge was paid for by the authors.

**Authorship:** All authors have a substantial contribution to the article.

**Copyright** The Authors published by Al-Azhar University, Faculty of Medicine, Cairo, Egypt. Users have the right to read, download, copy, distribute, print, search, or link to the full texts of articles under the following conditions: Creative Commons Attribution-Share Alike 4.0 International Public License (CC BY-SA 4.0).

### INTRODUCTION

Osteoarthritis (OA) is a condition that impacts all of the tissues in a joint<sup>1,2</sup>. Evidence suggests that the subchondral bone is the most important component in both pain genesis and disease progression<sup>3,4</sup>. Magnetic resonance imaging (MRI) findings of bone marrow lesions (BMLs), or alterations in subchondral bone, are becoming more well-known in stress injuries, trauma, and osteoarthritis<sup>5</sup>. Studies on the natural history of arthritis show a strong link between BMLs and pain (both the presence and severity)<sup>6,7,8</sup>, as well as a faster advancement to total knee arthroplasty (TKA),<sup>9,10</sup>. Arthroscopic surgery used to be the most widely performed surgical procedure for degenerative knee disease<sup>11,12</sup>. Even

with many guidelines showing that there is little short-term improvement still<sup>13,14</sup>, there are many indications for arthroscopy as displaced torn meniscus, loose body, microfracture, abrasion chondroplasty<sup>11</sup>.

Although total knee arthroplasty has proven to be a long-lasting treatment that provides consistent pain alleviation and enhanced function, it's a significant surgical procedure that is costly, and it can be associated with severe complications and the need for revision in younger patients<sup>15-16</sup>. Therefore, there is an interest in therapies aiming at the subchondral bone as the main target of the treatment of knee osteoarthritis<sup>17</sup>. Subchondroplasty is a procedure for treating bone marrow lesions that involves injecting a bone substitute material like calcium phosphate cement or hydroxyapatite (HA) into the

compromised subchondral bone under fluoroscopic guidance to provide mechanical support and initiate osseous remodeling to relieve pain and change the course of OA.<sup>17,18</sup> The literature reports in the previous few years have demonstrated that the procedure is non-invasive and efficacious with minimal complications.<sup>17-24</sup> the goal of this prospective outcome study is to evaluate the efficiency of subchondroplasty in osteoarthritic individuals having BMLs. It was believed that Subchondroplasty would reduce pain and improve function while delaying TKA. This is the first study in Egypt to review patient-related Subchondroplasty outcomes and provide guidelines for the procedure's introduction into clinical practice.

## PATIENTS AND METHODS

### Study design:

This prospective one-year follow-up case study included 30 patients who were enrolled between February 2019 and February 2021. The institutional review board authorized the study, and every participant provided written informed permission.

### Inclusion criteria

Age 40–75 years, for at least 3 months, atraumatic knee pain and impaired functioning, failures of conservative therapy for at least 3 months, moderate to severe osteoarthritis (Kellgren-Lawrence grading 3– early grade 4<sup>(26)</sup>, BML (femoral condyles and tibial plateau) on MRI scanning, localized pain in the BML region, and a signed informed agreement to participate in this research were the inclusion criteria for this study.

### Exclusion criteria

Patients with knee pain and functional limitations caused by other conditions such as fractures, osteonecrosis, infection, tumors, or inflammatory arthritis have been excluded from the study, as have those with gross ligamentous instability, and coronal axis malalignment > 8 degrees in varus/valgus, ( tri-compartmental grade 4 arthritis with complete bone contact)

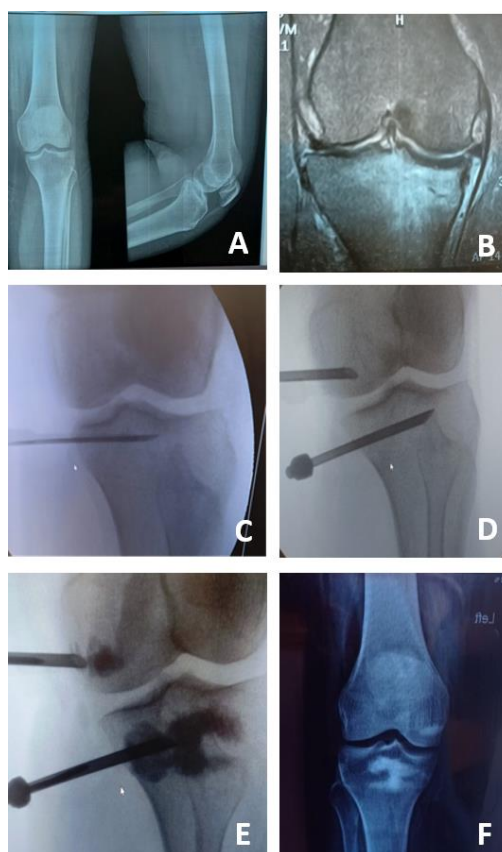
### Endpoints:

All of the patients were evaluated clinically, radiologically, and with an MRI. Preoperatively, and at two weeks, three months, six months, and twelve months postoperatively, they were assessed using the WOMAC score, and the pain was recorded using the VAS score. X-rays were taken of all of the patients immediately following therapy, as well as 3, 6, and 12 months afterward. Complications during and after surgery were also documented.

### Surgical Technique:

After prior planning, the SCP technique was done on the patient in a supine posture under spinal anesthesia.

According to preoperative planning, the cannula entry point was indicated on the skin using fluoroscopy in both frontal and lateral views. The majority of the studied patients have large BMLs that are not confounded to points requiring precise identification and triangulation. Unlike standard SCR techniques, no jigs were used, instead, awls or guidewires were applied, and drilling was done 1-2 cm away from the joint line, either parallel or oblique to the joint line, or through the epiphyseal scar from the opposite side of the knee to avoid overpressurizing the subchondral bone as well as prevent extravasation into soft tissues. Using curved awls, reamers, and various dilatation devices, expanding and dilatation of the injection site to optimize subchondral bone. After that, the cannula was inserted, and drilling proceeded till the lesion was approached. The bone substitute substance which is nanocrystal hydroxyapatite cement,( QOssHeal IHA .G.SURGIWEAR LTD, Shahjahanpur, India), was then prepared and injected into the area, with fluoroscopy used to check its distribution.



**Fig 1:** Subchondroplasty technique. A: preoperative x-ray, AP and lat., views. B: MRI, Subchondral bone marrow lesions in the medial tibial & femoral sides. C: Localization of injection area with guidewire under fluoroscope D: Introducing injection cannula :  
E: Drilling F: Postoperative x-ray

Injection is completed F: Postoperative x-ray: injectable material is in place

**Postoperative care:**

involved controlling postoperative pain (which could be severe) and partial weight-bearing with crutches for two weeks. Following that, full weight with no restrictions on the range of motion was permitted. Returning to everyday routines as soon as tolerated was recommended, which could take anywhere from 2-4 months.

**Statistical Analysis:** The Statistical Package for Social Science (IBM SPSS) version 23 was used. The mean, standard deviations, and ranges of parametric data have been reported. The median and inter-quartile range (IQR) have been used to present nonparametric data. The Chi-square test, as well as the Fisher exact test, have been employed to compare groups with qualitative data. The Paired t-test has been employed to compare two groups that have a parametric distribution. Willcoxon test has been used to make a comparison between the two paired groups with the nonparametric distribution. In addition, the Friedman test and Spearman correlation coefficients have been employed to evaluate the relationship between two quantitative parameters in the same group. The significance of the p-value has been determined as follows: P < 0.01: Highly significant, P < 0.05: Significant.

**RESULTS**

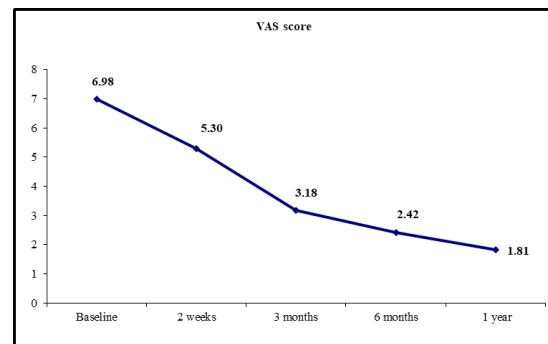
Table (1) summarises the following: 70% of the patients (21 of 30) were females with an average age of 58 years (range 40.0–70.0) and a BMI of 29.7 kg/m<sup>2</sup> (range 22.5–37.7 kg/m<sup>2</sup>). Patients had been experiencing symptoms for an average of 38 months (range 10–180 months) before surgery, with osteoarthritis KL grading of 21 patients KL grade 3 and 9 patients KL grade 4. The site of bone marrow lesion was combined tibial & femoral lesions, with the affection of medial tibial plateau in (100 %) of cases, medial femoral lesions in (86.6 %), lateral femoral in(6.7 %) and both lateral and medial femoral lesions in (6.7 %). The majority of the studied patients have extensive BMLs. Patients rated their preoperative pain on a VAS scale of 6.9 out of 10 (range 5–9). At the start of the study, the average WOMAC score was 62.03. (range 41–81).

Patients n= 30		
Gender	Female	21 (70.0%)
	Male	9 (30.0%)
Age (Year)	Mean ± SD	58.27± 10.15
	Range	40– 70
BMI (Kg/m <sup>2</sup> )	Mean ± SD	29.72 ± 3.49
	Range	22.5 – 37.7
Duration of pain (m)	Median (IQR)	38 (25 - 50)
	Range	10 – 120
Range of movement	Mean ± SD	96.33 ± 5.40
	Range	90 – 110
Fixed deformity	Mean ± SD	10.53 ± 4.68
	Range	5 – 20

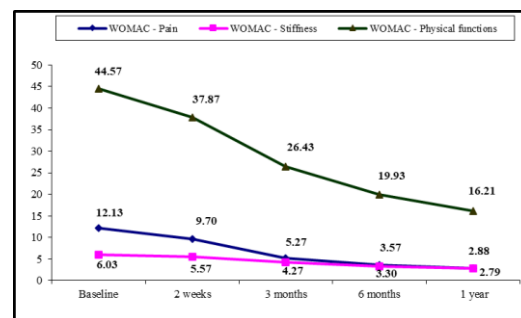
Previous intervention	No HTO, MR. Arth. debridement ACL recons.	(% <sup>86.7</sup> ) 20 (% <sup>6.9</sup> ) 2 (% <sup>3.4</sup> ) 1 1 (3.4%)
	KL grade	III 21 (70.0%) IV 9 (30.0%)
	Femoral-Tibial angle	Median (IQR) -6 (-7 - -5) Range -8 – 8
	Tibial BMLS	lateral 0(0 %) medial 30 (100 %)
Femoral BMLS	lateral 2 (6.7%) Medial 26 (86.6 %) Medial & lateral 2 (6.7%)	

**Table 1:** Comparison of the two groups evaluated. IQR: interquartile range, SD: standard deviation.

Changes in pain score (VAS) Overall, the average VAS scores improved significantly after surgery. By the conclusion of the year's follow-up, the patient had improved from 6.98 +/-1.16 to 1.81 +/-1.00 (p<0.01)



**Fig 2:** Follow up for VAS score at different times of measurement.



**Fig 3:** Comparison between WOMAC score at different times of measurement. Function:black line.stiffness :pink ,pain:blue.

There was no statistically significant correlation between the outcome measures (VAS and WOMAC) scores and: Patient demographics: except for a positive correlation with BMI and a positive correlation with the duration of pain. There is a negative correlation between KL scores and improved outcome scores, especially for pain and stiffness.

	VAS		WOMAC –pain		WOMAC –stiffness		Physical functions		WOMAC –total	
	r	p-value	r	p-value	r	p-value	R	p-value	r	p-value
Age (Year)	0.331	0.114	0.124	0.562	0.167	0.437	0.360	0.084	0.300	0.154
Weight (kg)	0.222	0.297	0.303	0.150	0.316	0.132	0.050	0.815	0.165	0.442
Height (cm)	0.245	0.250	0.085	0.692	-0.117	0.588	0.101	0.639	0.139	0.517
BMI (Kg/m <sup>2</sup> )	0.416*	0.043	0.441*	0.031	0.175	0.414	0.477*	0.019	0.496*	0.014
Duration of pain(m)	0.686**	0.000	0.767**	0.000	0.320	0.127	0.668**	0.000	0.674**	0.000

**Table 2:** Correlation of the studied scores at one year with the other variables. Spearman correlation coefficients.

No intraarticular extravasation was encountered in our study. Soft tissue extravasation occurred in six patients but gradually resorbed within 3 months with no need for re-operation. Aseptic discharge was noted in 8 patients, not associated with manifestations of osteomyelitis. It was self-limiting without any intervention in a month or so. No other significant complications related to the procedure or graft material such as osteomyelitis, deep venous thrombosis, avascular necrosis, or injury to vessels or nerves. The need for conversion to TKA: has been encountered in one female patient, 68 years at the date of surgery, the 2<sup>nd</sup> case of this series. She refused to undergo TKA.

## DISCUSSION

This prospective trial's major result was that SCP improved pain and knee functioning in individuals with OA-related BMLs of the knee who had not responded to previous conservative therapies. With a p-value of 0.001, the VAS score reduced from 6.98 1.16 at baseline to 1.81 1.00 after one year. In terms of knee function, the total WOMAC score fell from 62.03 11.19 at baseline to 21.83 8.18 after one year, with a p-value of 0.001.

OA is a progressive and degenerative condition with unlikely regression. Traditionally, treatment of OA knee includes conservative measures, and several arthroscopic and open surgical techniques, but eventually needs joint replacement. Recently, subchondroplasty has been developed as a minimally invasive, joint-preserving technique to manage bone marrow lesions; a bone substitute substance is injected under fluoroscopic guidance into the subchondral bone<sup>15,16,17</sup>.

This study's findings are consistent with those of other research that has looked into this procedure. In 2012, Sharkey et al.<sup>16</sup> became the first to report the use of SCP in a 51-year-old woman suffering from OA-related BML. Clinical and functional results were excellent during the 31-month follow-up.

Cohen & Sharkey<sup>17</sup>, in 66 patients who presented with advanced knee OA, indicated knee arthroplasty, and those who had subchondroplasty combined with arthroscopy. Through two years of postsurgical follow-up, statistically and clinically significant enhancements in pain and function were observed after subchondroplasty. In addition, at two years

postoperatively, joint preservation survivorship (non-arthroplasty conversions) was 70% in the research participants.

Farr and Cohen<sup>19</sup> have expanded the indication of SCP for other areas of the knee with BML. In addition, at the last follow-up, functional and pain scores improved significantly.

David et al.<sup>20</sup> Studied the short-term outcome of SCP for treating knee OA. The authors experienced an 88% reduction in pain, a 72% increase in pain-free walking distance, as well as four (8%) conversions to whole knee arthroplasty.

Five cases were studied prospectively by Bonadio et al.<sup>21</sup> Based on the VAS score, pain decrease was accomplished 24 weeks after surgery.

Astur et al.<sup>22</sup>, 164 patients with bone marrow lesions recovered with the significant functional improvement of the knee after subchondral calcium phosphate treatment. Chua et al.<sup>23</sup> found that WOMAC and VAS scores improved significantly. Thus, they concluded that lesions of subchondral bone marrow in the arthritic knee can be effectively treated by subchondroplasty.

In a prospective cohort study involving 30 cases, Randelli et al.<sup>24</sup> found that all assessed scores improved six months post-surgical when compared to baseline.

Levy et al.<sup>25</sup> looked at 179 patients who had a work-related knee injury and were diagnosed with arthritis, BME, and then subchondroplasty. At six months, 86% indicated significant enhancement, 74% at three years, and 83% at five years.

In a one-year follow-up study of 12 patients who underwent subchondroplasty,

Study limitations: despite the positive outcomes, the current research includes some restrictions. Firstly, it's a case study with only 30 individuals, which could contribute to selection bias and a lack of generalizability. The low number of patients is because subchondroplasty surgery is a relatively new procedure. It was tough to persuade them about the surgery and its expense. Second, there is no control group against which the intervention group may be compared. Third, there is only a one-year follow-up

period; any symptom alleviation or pain reduction noticed may not have been lasting. Fourth, due to patients missing appointments, there is patient variability in OA severity (from mild to severe OA) and postoperative data collection.

### CONCLUSION

The present data for subchondroplasty reveals possible benefits in pain, functional results, and low rates of complications; the SCP technique is a true minimally invasive intervention that looks to be a safe, efficient, and joint-preserving procedure for knee osteoarthritis caused by BMLs.

Conflict of interest : none

### REFERENCES

- 1 Felson DT. An update on the pathogenesis and epidemiology of osteoarthritis. *Radiol Clin North Am.* 2004;42(01):1-9
2. Loeser RF, Goldring SR, Scanzello CR, et al. Osteoarthritis: a disease of the joint as an organ. *Arthritis Rheum.* 2012;64(06): 1697-707
3. Madry H, van Dijk CN, Mueller-Gerbl M. The basic science of the subchondral bone. *Knee Surg Sports Traumatol Arthrosc.* 2010; 18(4):419-433.
4. Madry H, Orth P, and Cucchiari M. Role of the subchondral bone in articular cartilage degeneration and repair. *Journal of the American Academy of Orthopaedic Surgeons.* 2016;24(4):45-6.
5. Roemer FW, Guermazi A, Javaid MK, et al. Change in MRI-detected subchondral bone marrow lesions is associated with cartilage loss: the MOST study. A longitudinal multicentre study of knee osteoarthritis. *AnnRheum Dis.* 2009;68(9):1461-5.6
6. Felson DT, McLaughlin S, Goggins J, et al. Bone marrow edema and its relation to progression of knee osteoarthritis. *Ann Intern Med.* 2006, 54.5: 1529-35.
7. Tanamas SK, Wluka AE, Pelletier JP, et al. Bone marrow lesions in people with knee osteoarthritis predict disease progression and joint replacement: a longitudinal study. *Rheumatology (Oxford)* 2010;49(12):2413-9
8. Wluka AE, Wang Y, Davies-Tuck M, et al. Bone marrow lesions predict the progression of cartilage defects and loss of cartilage volume in healthy middle-aged adults without knee pain over 2 yrs. *Rheumatology (Oxford).* 2008;47(9): 1392-6
9. Felson DT, Chaisson CE, Hill CL, et al. The association of bone marrow lesions with pain in knee osteoarthritis. *Ann Intern Med.* 2001;134(7):541-9
10. Scher C, Craig J and Nelson F. Bone marrow edema in the knee in osteoarthrosis and association with total knee arthroplasty within a three-year follow-up. *Skeletal Radiol.* 2008;37(07):609-17
11. O'Connor D, Johnston RV, Brignardello-Petersen R, et al. Arthroscopic surgery for degenerative knee disease (osteoarthritis including degenerative meniscal tears). *Cochrane Database of Systematic Reviews* 2022, 3.
12. Thorlund JB, Juhl CB, Roos EM, et al. Arthroscopic surgery for degenerative knee: Systematic review and meta-analysis of benefits and harms. *BMJ.* 2015;350.
13. Kirkley A, Birmingham TB, Litchfield RB, et al. A randomized trial of arthroscopic surgery for osteoarthritis of the knee. *N Engl J Med.* 2008;359(11):1097-07.
14. Moseley JB, O'Malley K, Petersen NJ, et al. A controlled trial of arthroscopic surgery for osteoarthritis of the knee. *N Engl J Med.* 2002;347(2):81-88.
15. Halawi MJ, Jongbloed W, Baron S, et al. Patient Dissatisfaction After Primary Total Joint Arthroplasty: The Patient Perspective. *The Journal of Arthroplasty.* 2019;34(6):1093-6.
16. SharkeyPF, Cohen SB, Leinberry CF, et al. Subchondral Bone Marrow LesionsAssociated With Knee. *Osteoarthritis Am J Orthop.* 2012;41(9):413-7
17. Cohen SB, and Sharkey PF. Surgical treatment of osteoarthritis pain related to subchondral bone defects or bone marrow lesions: subchondroplasty. *Tech Knee Surg.* 2012;11(04):170-5
- 18 . Cohen SB, Sharkey PF. Subchondroplasty for treating bone marrow lesions. *J Knee Surg* 2016;29(07):555-563
- 19 . Farr J, and Cohen SB. Expanding applications of the subchondroplasty procedure for the treatment of bone marrow lesions were observed on magnetic resonance imaging. *Oper Tech SportsMed.* 2013;21(02): 138-43
20. Davis AT, Byrd JM, Zenner JA, et al. Short-Term Outcomes of the Subchondroplasty Procedure for the Treatment of Bone Marrow Edema Lesions in Patients with Knee Osteoarthritis. *Orthopaedic Journal of Sports Medicine.* 2015; 3:2325967115S0012.
21. Bonadio MB, Giglio PN, Helito CP, et al. Demange MK. Subchondroplasty for treating bone marrow lesions in the knee - initial experience. *Rev Bras Ortop.* 2017;52 (03):325-30
22. Astur DC, de Freitas EV, Cabral PB, et al. Evaluation and management of subchondral calcium phosphate injection technique to treat bone marrow lesion. *CARTILAGE.* 2018;10(4):395-401.
23. Chua K, Kang JYB, Ng FDJ, et al. Subchondroplasty for bone marrow lesions in the arthritic knee results in pain relief and improvement in function. *J Knee Surg.* 2021;34(06):665-71
24. Randelli P, Martina R, and Riccardo C. Bone marrow lesions in the knee: early results of patients treated with subcondroplasty. *AMSUM.* 2020; 1(1):2-8
25. Levy AS and Cousins K. The rationale for and efficacy of subchondroplasty in the injured worker. *J Orthop.* 2020; 22:48-52.
26. Kellgren JK and Lawrence JS. Radiological assessment of osteoarthritis. *Ann Rheum Dis* 1957;16:494-501.