



10-1-2022

FRAME-BASED STEREOTACTIC SURGERY IN THALAMIC LESIONS

Rageh Elsiagy

Neurosurgery department, Faculty of medicine, Al-Azhar university, Cairo, Egypt., ragehys@yahoo.com

Mohamed Mansour

Department of Neurosurgery, Faculty of Medicine for boys, Al-Azhar University. Cairo, Egypt., mohamedhasanmansour@gmail.com

Mostafa Elmaghraby

Department of Neurosurgery, Faculty of Medicine for boys, Al-Azhar University, Cairo, Egypt., mostafaelmaghraby.me@gmail.com

Follow this and additional works at: <https://aimj.researchcommons.org/journal>



Part of the [Medical Sciences Commons](#), [Obstetrics and Gynecology Commons](#), and the [Surgery Commons](#)

How to Cite This Article

Elsiyag, Rageh; Mansour, Mohamed; and Elmaghraby, Mostafa (2022) "FRAME-BASED STEREOTACTIC SURGERY IN THALAMIC LESIONS," *Al-Azhar International Medical Journal*: Vol. 3: Iss. 10, Article 5.

DOI: <https://doi.org/10.21608/aimj.2022.126815.1875>

This Original Article is brought to you for free and open access by Al-Azhar International Medical Journal. It has been accepted for inclusion in Al-Azhar International Medical Journal by an authorized editor of Al-Azhar International Medical Journal. For more information, please contact dryasserhelmy@gmail.com.

Frame-Based Stereotactic Surgery in Thalamic Lesions

Rageh Yasser El-Siagy^{1,*} M.B.B.Ch., Mostafa Elmaghraby¹ MD. and Mohamed Hasan Mansour¹ MD.

** Corresponding Author:*

Rageh Yasser El-Siagy
ragehys@yahoo.com

Received for publication March 11, 2022; Accepted October 22, 2022;
 Published online October 22, 2022.

Citation: Rageh Y., Mohamed H. and Mostafa E. *Frame-Based Stereotactic Surgery in Thalamic Lesions.* AIMJ. 2022; Vol.3-Issue 10: 29-34.

doi: 10.21608/aimj.2022.126815.1875

¹Department of Neurosurgery, Faculty of Medicine, Al-Azhar University, Cairo, Egypt.

ABSTRACT

Background: Stereotactic surgery is recommended over dramatic excision for the management of thalamic malignancies because the thalamus is a vital structure surrounded by essential white matter pathways.

Aim of the work: Assessment of the benefits and safety of the frame-based stereotactic surgery in thalamic lesions.

Patients and Methods: Retrospective study conducted on 15 patients suffering from different thalamic lesions, recruited from Neurosurgery Department, Al-Azhar University and Ministry of Health Hospitals over the period from 2016 to 2021.

Result: Patients mean age were 39.53 ± 15.58 years old. 40% of them were males and 60% were females. Majority (81.8%) of patients presenting with headache preoperatively had improved postoperatively, no statistically significant difference. patients with Dysphasia, 44.4% improved as a result of the operation. Regarding patients presenting with symptoms of increased intracranial pressure; the 3 patients who presented with repeated vomiting had improved. For consciousness level, 50% of patients presenting with DCL had improved. Patients presenting with bilateral hyperreflexia, showing clinical improvement in 100% of patients. Pneumocephalus was the most common complications met, which was prevalent in 66.7% of patients followed by intralesional hematoma which performed 20% of the population. Obstructive hydrocephalus came into the least order.

Conclusion: Thalamic lesions treated by frame-based stereotactic surgery showed postoperative improvement of headache, symptoms of increased intracranial pressure, and bilateral hyper-reflexia with no statistically significant difference between pre. and post-operative symptoms, on the other side no improvement were documented regarding unilateral hyperreflexia, Right and left hemiparesis, ataxia and vision.

Keywords: *Frame-based stereotactic surgery, Stereotactic biopsy, Thalamic lesions.*

Disclosure: *The authors have no financial interest to declare in relation to the content of this article. The Article Processing Charge was paid for by the authors.*

Authorship: *All authors have a substantial contribution to the article.*

Copyright *The Authors published by Al-Azhar University, Faculty of Medicine, Cairo, Egypt. Users have the right to read, download, copy, distribute, print, search, or link to the full texts of articles under the following conditions: Creative Commons Attribution-Share Alike 4.0 International Public License (CC BY-SA 4.0).*

INTRODUCTION

Stereotactic procedures, which were originally designed for lesion creation, allow for accurate insertion of a cannula or electrode tip to a predefined target region inside the brain with the least amount of danger.¹

To guide treatment and avoid needless procedures, tissue specimens for pathological diagnosis are required. Stereotaxy using computed tomography (CT) or magnetic resonance imaging (MRI) has made it possible to sample tissue from minor or deeply-seated brain lesions for histologic investigation. Empiric treatment without histopathologic confirmation is seldom advised when

this approach is used in the neurosurgical arsenal. The uses of novel procedures including brachytherapy, stereotactic radiosurgery, and intratumoral chemotherapy have been expanded thanks to technological breakthroughs in surgical instruments, neuroimaging techniques, and computation.²

Because the thalamus is surrounded by essential white matter pathways and the thalamus itself is a key structure, conservative techniques such as stereotactic biopsy or radiation are favored over dramatic excision for the treatment of thalamic malignancies.³

We aimed in this study, on patients with different thalamic lesions, to assess the benefits and safety of the frame-based stereotactic surgery procedures.

PATIENTS AND METHODS

Fifteen patients suffering from different thalamic lesions are randomly included.

The inclusion criteria: Suffering from thalamic lesion.

The exclusion criteria: Abnormal bleeding profile and patients under the age of 15 and those beyond the age of 65.

All patients are subjected to a proposed neurological sheet upon administration, the sheet includes: Personal data, current symptoms and problems, present history, past history, general examination and full neurological examination.

All patients are subjected to the following investigations: Routine Lab investigations: Complete blood count, coagulation profile, liver and kidney functions are done especially for children who need general anesthesia. Radiological investigations: All patients had a computed tomography (CT) scan and a magnetic resonance imaging (MRI) of the brain.

Technique:

The stereotactic frame is normally applied to the patient the morning before surgery under local anesthetic, with or without sedation, depending on the patient's general health. It's possible that some people with severe aberrant movement abnormalities may need general anesthesia.

Imaging: The stereotactic frame and CT localizers are used to acquire volumetric imaging. It is necessary to use T1-weighted magnetic resonance imaging (MRI) with contrast agent to view venous architecture. Before applying the frames, an MRI is performed. When an MRI is not an option, a stereotactic CT brain scan might be utilized instead.

Targeting and preparing for entry: Preparation: (Lesion location):CT localizers are used for imaging and X, Y and Z coordinates are measured manually. Entry planning: (Burr hole site): A pre-coronal entry site to prevent venous, sulcal, or ventricular penetration.

Stereotactic frame adjustment: Stereotactic frame co-ordinates (X Y Z) are adjusted according to the target.

Patient positioning: To avoid sliding, the patient is positioned supine with modest neck flexion and leg counter-flexion. To improve vision, transparent curtains are advised.

Procedure: Skin incision and burr hole guided by stereotactic technology. The frame arc is affixed to the frame base and used to designate the skin incision's location after frame adjustment, skin preparation, and draping. For a burr hole, a straight skin incision in the coronal or sagittal plane is adequate. After stereotactically mapping the skull, the dura, pia, and arachnoid are opened to create a burr hole craniostomy.

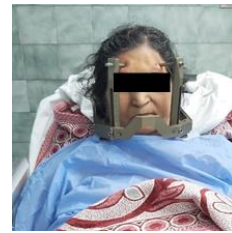

Fig. 1: Stereotactic frame affixed to the patient preoperative

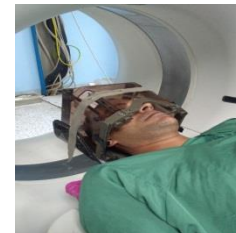


Fig. 2: Preoperative volumetric CT brain imaging with stereotactic frame

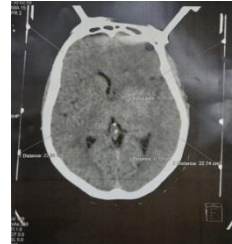


Fig. 3: Thalamic lesion stereotactic co-ordinates on CT image

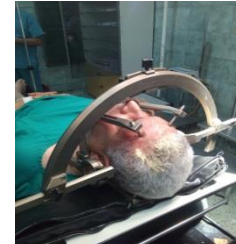

Fig. 4: Stereotactic arc installed to the frame

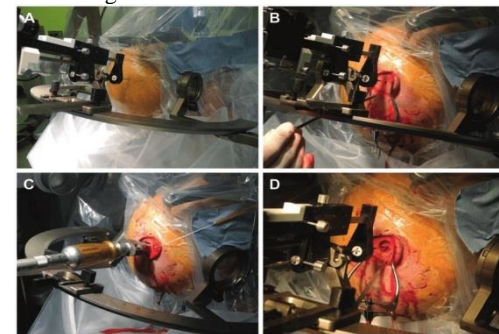


Fig. 5: Entry marking and Burr hole making

Statistical Analysis: For data analysis, we utilized version 24 of the Statistical Package for Social Sciences (SPSS) software. Frequencies and percentages were used to characterize categorical data. Means and standard deviations were used to describe numerical data. The Shapiro-Wilk test was used to determine if the distribution was normal. The McNemar test was used to examine the relationship between two category variables. Statistical relevance was defined as a P value of less than 0.05.

RESULTS

Variable	N (%)
Age	39.53 ± 15.58*
Gender	
Male	6 (40)
Female	9 (60)
DM	0
HTN	4 (26.7)
* Mean ± SD	

Table 1: describing the socio demographic characteristics of whole patients (n=15)

We found that 15 participants were eligible to perform the operation. Their mean age was 39.53 ± 15.58 years old. 40% of them (6 participants) were males and 9 participants (60%) were females. No one of participants was diabetic. On the other hand,

26.7% of participants (4 patients) were already hypertensive on treatment.

Variable	Post-operative		P value
Preoperative	Same	improved	
Headache	2 (18.2)	9 (81.8)	0.065
Motor power			
Full	2 (100)	0	NA
Right hemiparesis	7 (100)	0	
Left hemiparesis	6 (100)	0	
Sensation			
Normal	9 (100)	0	NA
Right hypoesthesia	2 (100)	0	
Left hypoesthesia	2 (100)	0	
Bilateral hypoesthesia	0	2 (100)	
Speech			
Normal	4 (100)	0	NA
Dysarthria	2 (100)	0	
Dysphasia	5 (55.6)	4 (44.4)	
ICP			
No symptoms	12 (100)	0	NA
Repeated vomiting	0	3 (100)	
Consciousness			
Fully conscious	7 (77.8)	0	0.112
DCL	2 (50)	2 (50)	
Short term memory disturbance	0	2 (100)	
Ataxia	8 (100)	0	
Normal vision	15 (100)	0	NA
Reflexes			
Right hyperreflexia	sided 7 (100)	0	NA
Left hyperreflexia	sided 6 (100)	0	
Bilateral hyperreflexia	0	2 (100)	

Table 2: the association between pre and post-operative clinical findings

We compared the clinical presentation pre and post operatively and found the following: 81.8% of patients presenting with headache preoperatively had improved postoperatively. However, this was statistically not significant (p=0.065). On the other hand, hemiparesis did not improve as a result of the operation. The 7 patients presenting with right hemiparesis remained the same postoperatively. In addition, the 6 patients presenting with left hemiparesis remained also the same postoperatively. For sensation, there was also no change postoperatively. Patients presenting with either right hypoesthesia or left hypoesthesia did not change post operatively. Unlike those who presented with Dysphasia, of whom 44.4% (4 patients) already improved as a result of the operation, this was also the case in patients presenting with symptoms of increased intracranial pressure. The 3 patients presented with repeated vomiting had improved. For consciousness level, 50% of patients presenting with DCL (2 patients) had improved. However, this was statistically insignificant (p=0.112) as shown in table 2. For ataxia and vision presentation in those patients, we also found no change post operatively among those cases as shown in the table. On the

other hand, patients presenting with either right or left sided hyperreflexia did not improve postoperatively. Unlike patients presenting with bilateral hyperreflexia, we found clinical improvement in 100% of patients (2 patients).

Finding	N (%)
Left thalamic Cyst	2 (13.3)
Left thalamic SOL	2 (13.3)
Left thalamic SOL with midline shift	5 (33.3)
Previously operated left thalamic SOL	2 (13.3)
Right thalamic Cyst	2 (13.3)
Right thalamic multi-cystic SOL	2 (13.3)

Table 3: preoperative radiologic findings for all participants (n=15)

Preoperatively, we found that left thalamic cyst with midline shift was the most common finding preoperatively which was found in 33.3% of participants (5 patients). Left thalamic cyst, left thalamic SOL, right thalamic cyst and right thalamic multi-cystic SOL were already prevalent in 13.3% of participants (2 patients) as shown in table 3.

Complications	N (%)
Intralesional hematoma	3 (20%)
Pneumocephalus	10 (66.7)
Obstructive hydrocephalus	2 (13.3)

Table 4: postoperative complications for all participants (n=15)

We found that postoperatively, pneumocephalus was the most common complication which was prevalent in 10 patients (66.7%) followed by intralesional hematoma which performed 20% of the population. Obstructive hydrocephalus came into the last order as shown in table 4.

Post-operative radiological examples for stereotactic intervention in thalamic lesions

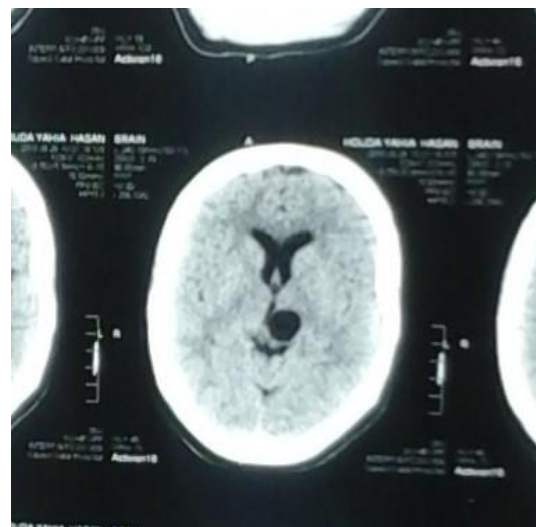


Fig. 6: Post-operative intra-lesional pneumocephalus (hypo-dense sign)

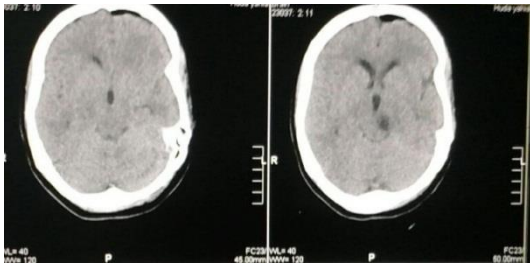


Fig. 7: Post-operative pneumocephalus

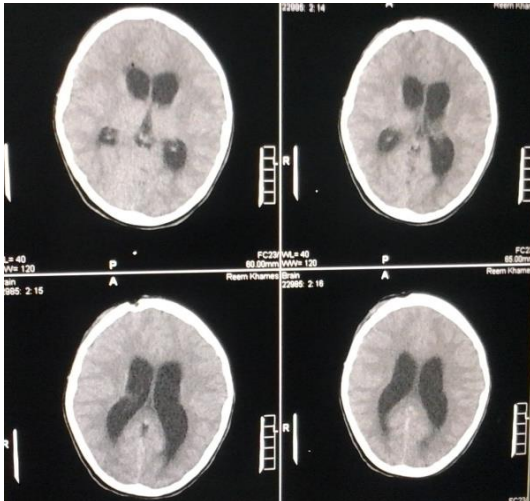


Fig. 8: Post-operative obstructive hydrocephalus

DISCUSSION

In this study we aimed to assess the benefits and safety of the frame-based stereotactic surgery procedures on patients with different thalamic lesions. We enrolled 15 patients suffering from thalamic lesions.

The thalamus may be affected by neoplastic, viral, vascular, toxic, metabolic, or congenital diseases.⁴

In our study, the most prevalent clinical manifestations of thalamic SOL were hemiparesis and unilateral hyper-reflexia, appearing in 86% of the patients enrolled in the study, 71% of patients presented by headache which comes equal to the presentation by speech symptoms. Patients presented by ataxia were 57%, then comes presentation by sensory symptoms and disturbed conscious level with 43% of patients for each. Lastly, repeated vomiting, memory loss and bilateral hyper-reflexia appeared in 14% of the patients each.

The common signs were motor deficits and headache as a result of engagement of the motor pathways and CSF affection; the thalamus represents a major relay center for integrating sensory and motor pathways that originate from distinct cortical and cerebellar regions; as expected and due to their deep location, symptomatology in our study was markedly relative to lesions site; major signs were motor deficits and headache as a result of involvement of the motor pathways and CSF affection; the thalamus represents a major relay. It also plays a role in language and memory, and earlier research in patients with thalamic malignancies, according to Esquenazi et al., shows that disease in distinct thalamic areas may cause unique abnormalities in neuropsychological profiles.⁶

The most prevalent clinical signs linked with thalamic space-occupying lesions, according to Puget et al., are indications of elevated ICP and/or motor impairments. Obstructive hydrocephalus is more likely to occur when medial or dorsal thalamic lesions protrude into the ventricular system. It's rare for a patient to present with sensory deficiencies.⁵

Hemiparesis (61 percent), confusion (49 percent), headache (47 percent), memory loss (42 percent), nausea/emesis (23 percent), and seizure (7%), according to Esquenazi et al., who studied the natural history and variables related with survival in individuals with thalamic glioblastoma in 57 patients. In 35, 20, 12, and 14 patients, respectively, motor (weakness), sensory (numbness/tingling), linguistic (naming difficulty, apraxia, and slowness of speech), and visual (blurry/double vision) symptoms were detected.⁶

Fayed et al., who investigate various therapeutic techniques for thalamic space-occupying lesions. There were 35 patients in all. Stereotaxy was used in 18 cases; the most common clinical presentation was hemiparesis in 21 cases (60 percent), followed by manifestation of increased ICP (headache, nausea, and vomiting) in 13 cases (37 percent), hemiparesis in 3 cases (8.5 percent), signs of meningeal irritation in 1 case (3%), and convulsions in 1 case (3%).⁷

As for post-operative clinical results in our study, majority (81.8%) of patients presenting with headache preoperatively had improved postoperatively, as for those presented by dysphasia, 44% (4 patients) of them already improved as a result of the operation.

Regarding patients presenting with symptoms of increased intracranial pressure; the 3 patients who presented with repeated vomiting had improved. For those presented by disturbed consciousness level, 50% of patients (2 patients) had improved, Patients presenting with bilateral hyperreflexia, showing clinical improvement in 100% of patients (2 patients).

On the other hand, none of the patients presenting with unilateral hyperreflexia improved postoperatively. Same goes for those presented by right or left hemiparesis, sensory symptoms or ataxia. For ataxia and vision presentation in those patients, we also found no change post operatively.

Our clinical findings are comparable to those of Moshel Y. A. et al.,⁸ who found that 18 of the 72 patients who underwent stereotactic volumetric resection of thalamic pilocytic astrocytomas were neurologically intact on preoperative neurological examinations, while 54 had preoperative neurological deficits. On neurological exams done one week after surgery, 16 (33 percent) of the 48 patients with preoperative hemiparesis were greatly better, 25 (52 percent) were unchanged, and six (13 percent) were worse. Preoperative dystonia was resolved in five out of seven patients (71 percent). Seven individuals had new neurological impairments after surgery. One of them had a moderate postoperative hemiparesis that had resolved by her 1-month follow-up exam, as well as a mild expressive dysphasia that had persisted. Another of the seven patients experienced temporary short-term memory problems that went away by the time they were discharged from the hospital. Two patients experienced considerable improvements in

their preoperative hemiparesis but additional postoperative deficits: one had a concurrent postoperative expressive dysphasia that disappeared on follow-up testing and the other had moderate hemidystaxia. Five of the patients were given a new visual field.

On long-term follow-up, 27 (56%) of the 48 patients with hemiparesis before stereotactic resection had greatly improved; 20 (40%) had remained constant. During the follow-up period, one more patient whose hemiparesis had worsened after surgery had not improved beyond the preoperative level. Preoperative dystonic posture was resolved in six out of seven patients (86 percent). Other postoperative neurological abnormalities persisted in six patients, including visual field deficits in five (hemiparesis improved in one), limb dystaxia in one, and moderate expressive dysphasia in one.⁽⁸⁾

According to Fayed et al., Six instances improved after six months of monitoring the 18 stereotactic cases (33 percent). The disease and the method were both major variables in the result. The findings revealed that the presence of cystic pathology was associated with a significant variation in clinical outcome in stereotactic patients. There was a cystic component to many instances, whether it was low-grade cystic gliomas or abscesses. No lesions indicated remembrance during the 6-month follow-up; nevertheless, this length of clinical follow-up is insufficient to determine recollection and the return of symptoms. Furthermore, as $p = 0.01$ shows, the method of stereotactic aspiration is linked to a positive clinical result. During the 6-month follow-up, however, two stereotactic patients (11%) worsened and/or died. These two lesions were high-grade gliomas, which might explain the worsening but is impossible to verify statistically.⁷

Esquenazi et al., mentioned that despite normal postoperative imaging and the absence of tumoral bleeding, postoperative impairments in deeply localized lesions may emerge. In the case of tumor edema, the intimate linkage of the thalamus to important functional regions might result in neurological impairments after biopsy or surgical debulking.⁶

Regarding postoperative complication in our present study; pneumocephalus was the most common complications, which was found in 10 patients (66.7%) followed by intralesional hematoma which performed 20% of the population. Obstructive hydrocephalus came into the least order 13.3%.

According to Matias et al., The degree of pneumocephalus following a burr hole (with opening of the dura mater and arachnoid) depends on a variety of variables, including the volume of the brain, the location of the patient's head, and the use of glue or bone wax to close the dural defect intraoperatively. In addition, the quantity of CSF leaked due to gravity's influence on brain structures.⁹ Unlike our results, it was mentioned in Lara-Almunia and Hernandez-Vicente's study that Seizures, de novo neurological impairments, infections, and hemorrhages are the most prevalent problems linked with this technique.¹⁰

Post-biopsy cerebral hemorrhages are both the most significant and the most commonly reported complication in the literature, with a presentation rate of 1.4–9.6 percent, according to numerous different research.^{11, 12, 13}

According to Esquenazi et al., In 9 patients (16%), acute postoperative surgical problems occurred: Following stereotactic biopsy, 7 (15%) patients had permanent neurological abnormalities (worsened hemiparesis in 5, hemiplegia in 1, and visual field reduction in 1), while 2 occurrences of asymptomatic intra-tumoral bleeding occurred.⁶

There is a lot of variation amongst research when it comes to whether or not post-biopsy bleeding is deemed a problem. We detected higher values for intralesional hematoma (20%) in the present research, indicating that the location of the lesion, particularly its depth, may influence the occurrence of hemorrhagic consequences during or after operation.

According to Mohamed et al., who studied 200 cases of intracranial lesions operated by stereotactic procedures to evaluate the occurrence of miss targeting in stereotactic brain surgery using frames, intralesional hematoma and pneumocephalus (hyperdense and hypodense intralesional signs) must be evaluated in all cases post-operatively for the confirmation of targeting accuracy and avoid mistargeting. Thus, considering them as confirmation signs rather than post-operative complications.¹⁴

Researchers like McGirt et al. discovered that the incidence of symptomatic post-biopsy bleeding of the basal ganglions or thalamus was 4.1 and 3.3 times higher, respectively, than if tissue samples were collected from other cerebral locations.¹⁵ Other author as Livermore et al., obtained similar findings.¹³

CONCLUSION

Thalamic lesions treated by frame-based stereotactic surgery showed postoperative improvement of headache, symptoms of increased intracranial pressure, and bilateral hyper-reflexia, on the other side no improvement were documented regarding unilateral hyperreflexia, right and left hemiparesis, ataxia and vision. The main postoperative complication was pneumocephalus followed by intralesional hematoma and then obstructive hydrocephalus came.

Conflict of interest : none

REFERENCES

1. Lindsay KW, Fuller G. Neurology and Neurosurgery Illustrated (Fifth Edition), 2010.
2. Shahzadi S, Andalibi R, Sharifi G. Biopsy of thalamic lesions using computed imaging-assisted stereotaxis: report of 15 years of experience. *Arch Iranian Med.* 2005; 8 (3): 188 – 191.
3. Bilginer B, Narin F, Işıkay I, Oguz KK, Söylemezoglu F, Akalan N. Thalamic tumors in children. *Childs Nerv Syst.* 2014; 30:1493-8.
4. Tuttle C, Boto J, Martin S. Neuroimaging of acute and chronic unilateral and bilateral thalamic lesions. *Insights into imaging.* 2019; 1(10): 24.

5. Puget S, Crimmins DW, Garnett MR. Thalamic tumors in children: a reappraisal. *Journal of Neurosurgery: Pediatrics*. 2007; 5 (106): 354-362.
6. Esquenazi Y, Moussazadeh N, Link TW. Thalamic glioblastoma: clinical presentation, management strategies, and outcomes. *Neurosurgery*. 2018; 1(83): 76-85.
7. Fayed A, Abdel Aziz O, Eshra M. Different strategies in the management of thalamic space-occupying lesions. *Egyptian Journal of Neurosurgery*. 2020; 1(35): 8.
8. Moshel YA, Link MJ, Kelly PJ. Stereotactic Volumetric Resection of Thalamic Pilocytic Astrocytomas. *Neurosurgery*. 2007; 61(1): 66-75.
9. Matias CM, Frizon LA, Asfahan F. Brain Shift and Pneumocephalus Assessment During Frame-Based Deep Brain Stimulation Implantation with Intraoperative Magnetic Resonance Imaging. *Oper Neurosurg (Hagerstown)*. 2018; 6(14): 668-74.
10. Lara-Almunia M, Hernandez-Vicente J. Symptomatic intracranial hemorrhages and frame-based stereotactic brain biopsy. *Surgical neurology international*. 2020; (11): 218-218.
11. Field M, Witham TF, Flickinger JC. Comprehensive assessment of hemorrhage risks and outcomes after stereotactic brain biopsy. *J Neurosurg*. 2001; 4 (94): 545-51.
12. Grossman R, Sadetzki S, Spiegelmann R. Haemorrhagic complications and the incidence of asymptomatic bleeding associated with stereotactic brain biopsies. *Acta Neurochir (Wien)*. 2005; 6 (147): 627-31; discussion 631.
13. Livermore LJ, Ma R, Bojanic S. Yield and complications of frame-based and frameless stereotactic brain biopsy--the value of intra-operative histological analysis. *Br J Neurosurg*. 2014; 5(28): 637-44.
14. Mohamed HM. Incidence of Miss Targeting in Frame-based Stereotactic Brain Surgery. *The Egyptian Journal of Hospital Medicine*. 2018; 73(9): 7454-7457.
15. Mcgirt MJ, Woodworth GF, Coon AL. Independent predictors of morbidity after image-guided stereotactic brain biopsy: a risk assessment of 270 cases. *J Neurosurg*. 2005; 5(102): 897-901.