



10-1-2022

Surgical Management of Cervical Myelopathy Anterior Versus Posterior Approaches

Abou soud Mahmoud

Department, abou.soud.tawfek@gmail.com

Abdulkafy Sharafuddin

Neurosurgery, Faculty of Medicine, Al-Azhar University, Egypt, Cairo, asharafuddin@hotmail.com

Usama El-Shokhaiby

Neurosurgery, Faculty of Medicine, Al-Azhar University, Egypt, Cairo, elshokhaiby@yahoo.com

Follow this and additional works at: <https://aimj.researchcommons.org/journal>



Part of the [Medical Sciences Commons](#), [Obstetrics and Gynecology Commons](#), and the [Surgery Commons](#)

How to Cite This Article

Mahmoud, Abou soud; Sharafuddin, Abdulkafy; and El-Shokhaiby, Usama (2022) "Surgical Management of Cervical Myelopathy Anterior Versus Posterior Approaches," *Al-Azhar International Medical Journal*: Vol. 3: Iss. 10, Article 4.

DOI: <https://doi.org/10.21608/aimj.2022.124273.1855>

This Original Article is brought to you for free and open access by Al-Azhar International Medical Journal. It has been accepted for inclusion in Al-Azhar International Medical Journal by an authorized editor of Al-Azhar International Medical Journal. For more information, please contact dryasserhelmy@gmail.com.

Surgical Management of Cervical Myelopathy Anterior Versus Posterior Approaches

Abou Soud Tawfik^{1*} M.B.B.Ch., Abdulkafy Sharafuddin² MD. and Usama El-Shokhaiby² MD.

*** Corresponding Author:**

Abou Soud Tawfik

abou.soud.tawfik@hotmail.com

Received for publication April 09,

2022; Accepted October 17, 2022;

Published online October 17, 2022.

Citation: Abou Soud T., Abdulkafy S. and Usama E. Surgical Management of Cervical Myelopathy Anterior Versus Posterior Approaches. AIMJ. 2022; Vol.3-Issue 10 : 20-29.

doi: 10.21608/aimj.2022.124273.1855

¹Department of Neurosurgery, Arab Organization for Industrialization Hospital.

²Department of Neurosurgery, Faculty of Medicine, Al-Azhar University, Cairo, Egypt.

ABSTRACT

Background: The most prevalent cause of spinal cord impairment is cervical spondylotic myelopathy (CSM). In the older, it is also the primary cause of spinal-cord-related impairment. Spinal cord compression can result from ventral pathologies or from dorsal compression causing progressive disability and impairing the quality of life.

Aim of the work: This study aims to compare anterior cervical discectomy and fusion using inter body fusion cages with posterior laminectomy in the management of one or multiple level cervical spon dylotic myelopathy.

Patients and Methods: 20 patients had cervical spondylotic myelopathy were identified in our research. There were 16 men and 4 women. Aged from (25 to 70 years) 10 patients operated upon by anterior cervical discectomy and fusion using interbody fusion cages and the other 10 patients were operated upon by posterior laminectomy.

Result: 20 patients with cervical spon dylotic myelopathy were identified in our research. 10 patients operated upon by anterior cervical discectomy and fusion using interbody fusion cages and the other 10 patients were operated upon by posterior laminectomy.

Conclusion: In this study, there is no significant difference between both groups in terms of myelopathy improvement. Postoperative pain is much less in the anterior group than in the posterior group. The average hospital stay is greater in the posterior group. However, the anterior group patients have nearly double the operative time and increased the risk of reversible dysphagia while the posterior group has more rate of C5 palsy and infection.

Keywords: Cervical; Spondylosis; Myelopathy; ACDF; Laminectomy.

Disclosure: The authors have no financial interest to declare in relation to the content of this article. The Article Processing Charge was paid for by the authors.

Authorship: All authors have a substantial contribution to the article.

Copyright The Authors published by Al-Azhar University, Faculty of Medicine, Cairo, Egypt. Users have the right to read, download, copy, distribute, print, search, or link to the full texts of articles under the following conditions: Creative Commons Attribution-Share Alike 4.0 International Public License (CC BY-SA 4.0).

INTRODUCTION

Cervical myelopathy (CSM) is the most common cause of spinal cord dysfunction. It is also the leading cause of spinal-cord-related disability in the elderly. It results from the degenerative narrowing of the spinal canal, causing spinal cord compression in a slow, progressive manner.¹

There is no well-defined pattern of neurologic deficits in cervical myelopathy. Patients present with varying signs and symptoms that can include: neck pain, numbness or paresthesia in the arms, gait disturbance, sensory deficits, weakness in the lower extremities with upper motor neuron characteristics, bladder dysfunction. Symptoms usually begin insidiously. Gait impairment is a common early symptom.²

The diagnosis requires a careful correlation between findings from the history, physical examination, and imaging studies. Both magnetic resonance imaging

(MRI), computed tomography (CT) and X-rays can be used to diagnose cervical myelopathy, providing a quantitative assessment of central canal. narrowing MRI is superior in providing intramedullary detail of spinal cord pathology, but CT provides better images of bone and other calcified tissues.³

Treatment options for cervical myelopathy, specifically when and if to operate, remain controversial. These alternatives include non-surgical and surgical methods that are both conservative and effective. The clinical and radiological aspects of each patient should be considered before choosing a surgical technique. There are several surgical methods to choose from, all of which are either anterior or posterior in nature.

Direct decompression of diseases in the anterior cervical spine, a muscle sparing dissection to decrease postoperative discomfort, lower infection rates, and the ability to decompress and treat cervical kyphosis are all advantages of an anterior approach. The posterior technique allows for a more extensive

decompression and relies on the cord's capacity to migrate away from prior lesions. Because the cord may not move posteriorly with considerable cervical kyphosis, it's crucial to examine cervical sagittal alignment.⁴

This study aims to compare anterior cervical discectomy and fusion using interbody fusion cages with posterior laminectomy in the treatment of one or multiple level cervical myelopathy

PATIENTS AND METHODS

From June 2019 to June 2020, this study was conducted prospectively and retrospectively on 20 patients with one or multiple levels of cervical myelopathy who were operated on in the Neurosurgery departments of AL-Azhar University hospitals, Arab Organization for Industrialization Hospital (A.O.I Hospital), and who were diagnosed clinically and radiologically as not responding to conservative medical treatment.

Patients were divided randomly into two groups:

Group (A): Included 10 patients operated upon by anterior cervical discectomy and fusion using interbody fusion cages (ACDF group).

Group (B): Included 10 patients operated upon by posterior laminectomy (laminectomy group).

Patients included in our study met the following inclusion criteria:

Age 25-70 years.

CSM caused by multi-segmental spinal stenosis (1 - 4 segments).

Preserved cervical curvature (cervical lordosis).

Failure of conservative medical treatment.

There is no previous history of cervical surgery.

Surgically fit.

The patient's willingness to follow up on the appointments.

The following patients were excluded from our study:

Age < 25 and > 70 years.

CSM caused by more than 4 segmental spinal stenosis.

Straightened or kyphotic cervical spine (loss of cervical lordosis).

Patients who improved with conservative treatment.

Cases undergoing combined anterior and posterior approaches.

Medically unable to undergo surgery.

An ossified posterior longitudinal ligament is also present (OPLL).

Corpectomy is required for lesions that extend posterior to the vertebral body..

Pre-operatively: All patients were subjected to the following:

History taking: Including the following:

Personal history: Including name, age, sex, occupation, address, marital status and any special habits of medical importance (e.g. smoking).

Complaint: In the patient own words and its duration.

Present history: With stressing on the onset, course and duration of the illness. What aggravates and what relieves the pain and analysis of the associated symptoms.

Past and family history: Of any previous operations or similar conditions in the family. Any history of systemic illness such as diabetes mellitus, vasculopathy, atherosclerosis, etc.

Clinical examination: A complete thorough general and neurological examination was performed and included the following:

Motor system examination

Sensory system examination

RESULTS

Sex distribution	Group A (Anterior)		Group B (Posterior)	
	No.	%	No.	%
Males	7	70 %	9	90 %
Females	3	30 %	1	10 %

Age distribution	Group A (Anterior)		Group B (Posterior)	
	No.	%	No.	%
25-39	2	20 %	2	20 %
40-49	3	30 %	3	30 %
50-59	5	50 %	4	40 %
60-70	0	0 %	1	10 %

Table 1: Showing sex and age distribution in the study groups.

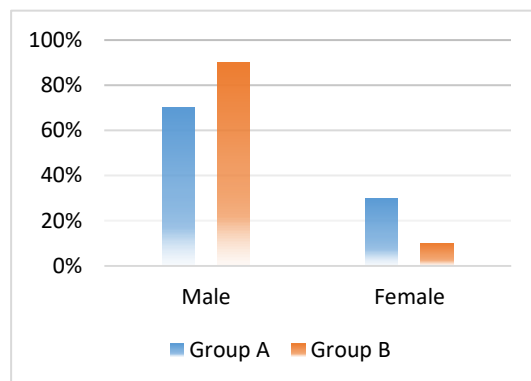


Fig. 1: Showing sex distribution in the study groups.

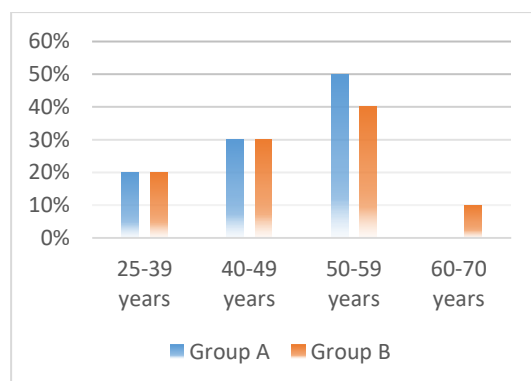


Fig. 2: Showing age group distribution in the study groups.

Symptoms	Group A (Anterior)		Group B (Posterior)	
	No.	%	No.	%
Neck pain	8	80 %	8	80%
Numbness	7	70%	5	50%
Heaviness in U.L or L.L	6	60%	8	80%
Brachialgia	7	70%	4	40%
Sphincteric disturbance	6	60 %	6	60 %
Signs	Group A (Anterior)		Group B (Posterior)	
	No.	%	No.	%
UL Weakness	10	100 %	8	80 %
UL & LL weakness	5	50 %	8	80 %
Sensory disturbance	6	60 %	4	40 %
Spasticity	3	30 %	6	60 %
Hyperreflexia	8	80 %	9	90 %
Positive Babinski sign	8	80 %	8	80 %
Positive Hoffmann reflex	4	40 %	3	30 %
Ankle clonus	7	70 %	8	80 %

Table 2: Showing the presenting symptoms and signs in the study groups:

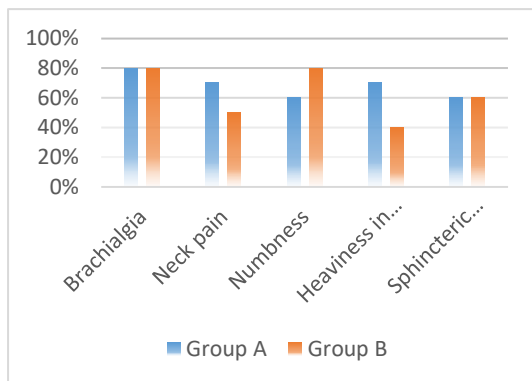


Fig. 3: Showing the presenting symptoms in the study groups.

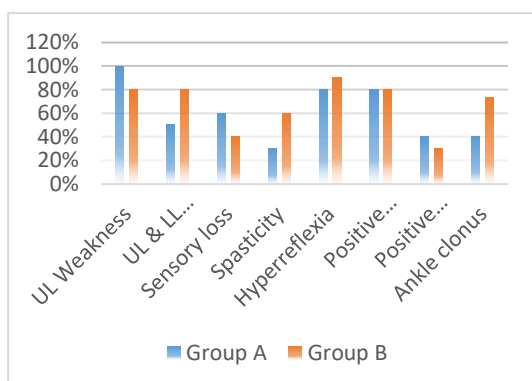


Fig. 4: Showing the clinical signs in the study groups.

Radiological findings	Group A (Anterior)		Group B (Posterior)	
	No.	%	No.	%
One or more level stenosis	10	100 %	10	100 %
Instability in Fx. & Ex.	0	0 %	0	0 %
High T2 signal (single)	7	70 %	6	60 %
High T2 signal (multiple)	3	30 %	4	40 %

Table 3: Showing the radiological findings in the study groups:

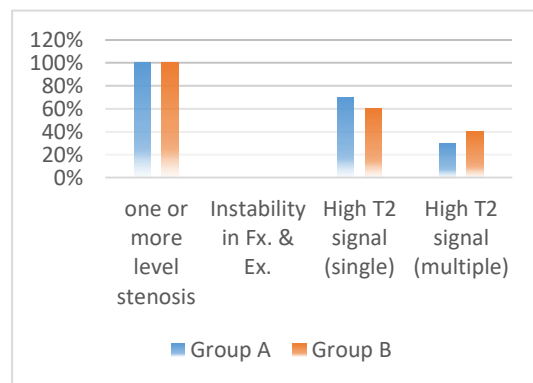


Fig. 5: Showing the radiological findings in the study group

Levels number	Group A		Group B	
	No.	%	No.	%
1 levels	6	60 %	0	0 %
2 levels	3	30 %	3	30 %
3 levels	1	10 %	6	60 %
4 levels	0	0 %	1	10 %

Table 4: Showing the operative segment in the study group:

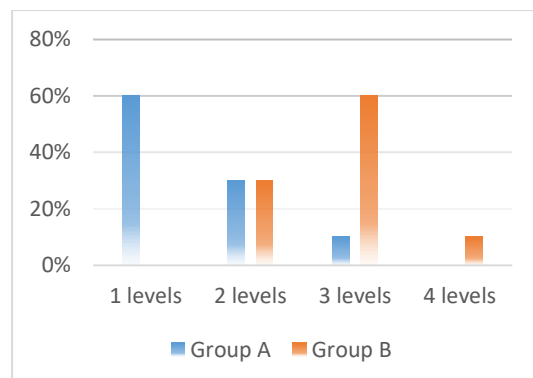


Fig. 6: Showing the operative segment in the study group.

Nurick's myelopathy grade	Pre-operative				Post-operative			
	Group A		Group B		Group A		Group B	
	N o.	%	N o.	%	N o.	%	N o.	%
Grade 0	-	-	-	-	-	-	-	-
Grade 1	1	10 %	1	10 %	3	30 %	2	20 %
Grade 2	5	50 %	3	30 %	4	40 %	4	40 %
Grade 3	3	30 %	3	30 %	2	20 %	2	20 %
Grade 4	1	10 %	2	20 %	1	10 %	1	10 %
Grade 5	-	-	1	10 %	-	-	1	10 %

Table 5: Showing pre and post-operative Nurick's myelopathy grade in the study group:

Neck Disability Index	Pre-operative		Post-operative	
	No.	%	No.	%
0 - 4 = no disability	1	10 %	1	10 %
5 - 14 = mild	3	30 %	5	50 %
15 - 24 = moderate	3	30 %	3	30 %
25 - 34 = severe	2	20 %	1	10 %
34 = > complete.	1	10 %	-	-

Table 6: Showing pre and post-operative Neck Disability Index grade in the study group:

Odom's criteria	Post-operative			
	Group A		Group B	
	No.	%	No.	%
Excellent	2	20 %	0	0 %
Good	4	40 %	5	50 %
Fair	3	30 %	4	40 %
Poor	1	10 %	1	10 %
Postoperative complications	Group A		Group B	
	No.	%	No.	%
C5 palsy	0	0 %	1	10 %
Superficial infection	0	0 %	1	10 %
Dysphagia	2	20 %	0	0 %
Transient weakness	1	10 %	1	10 %
Hoarseness of voice	1	10 %	0	0 %
Dural tear	1	10 %	0	0 %
Deep infection	0	0 %	0	0 %
Hematoma	0	0 %	0	0 %
Vascular injury	0	0 %	0	0 %
Mortality	0	0 %	0	0 %

Table 7: Showing post-operative Odom's criteria and postoperative complications assessment in the study group.

Cases

Case (1)

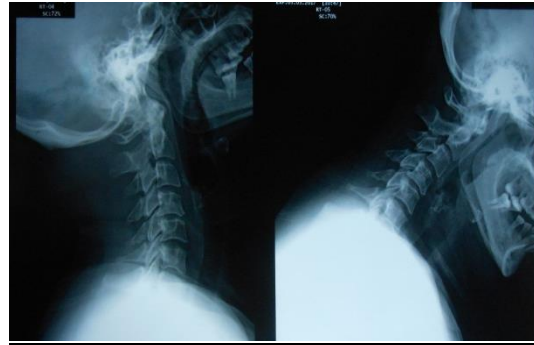

Fig. 7: Preoperative X-ray cervical spine, flexion and extension views showing no instability

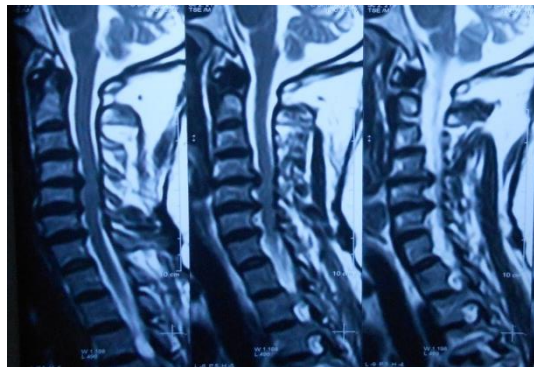


Fig. 8: Preoperative MRI Cervical spine T2 sagittal view showing C4, 5 and C5, 6 disc prolapse

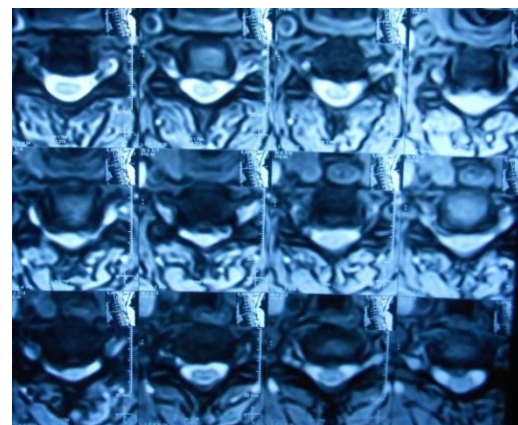

Fig. 9: Preoperative MRI cervical spine T2 axial view showing compression of the nerve roots more on the right side

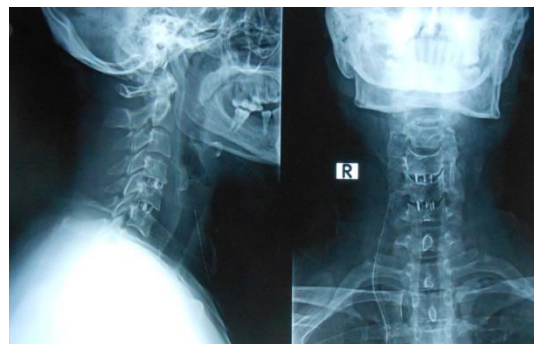


Fig. 10: Postoperative X-ray Cervical spine AP and lateral views showing C4, 5 and C5, 6 cages in position

Case (2)

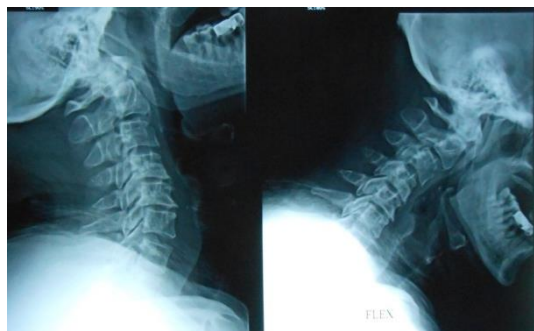


Fig. 11: Preoperative X-ray cervical spine, flexion and extension views showing no instability

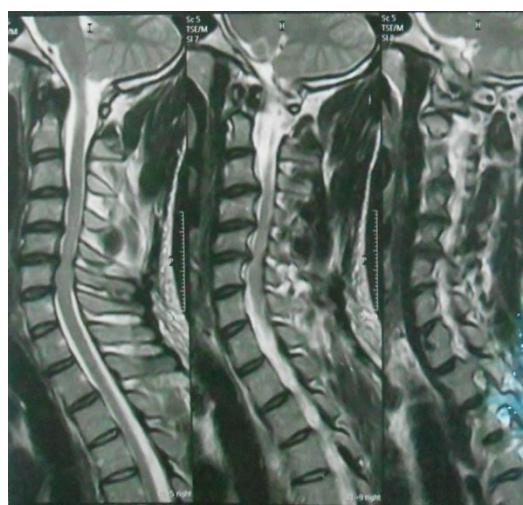

Fig. 12: Preoperative MRI. Cervical spine T2 sagittal view showing C3, 4, C4, and C5, 6 disc prolapse

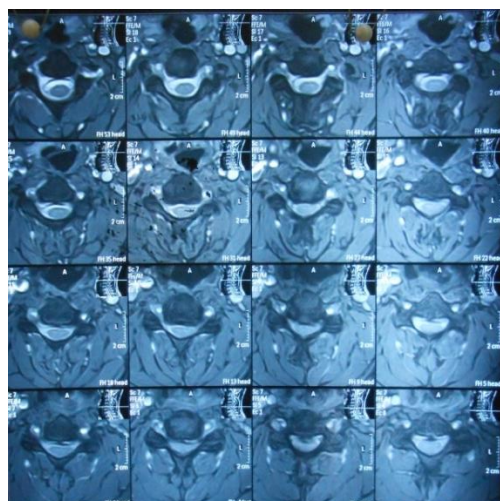


Fig. 13: Preoperative MRI cervical spine T2 axial view showing central disc herniation

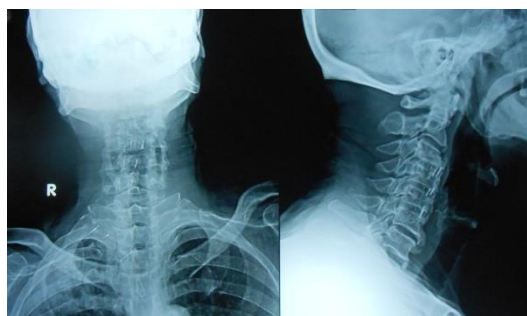

Fig. 14: Postoperative X-ray Cervical spine AP and lateral views showing cage subsidence one year postoperative.

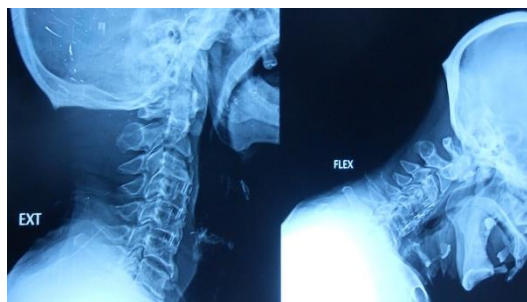

Fig. 15: Postoperative X-ray Cervical spine flexion and extension views showing cage subsidence one year postoperative, no instability

Case (3)

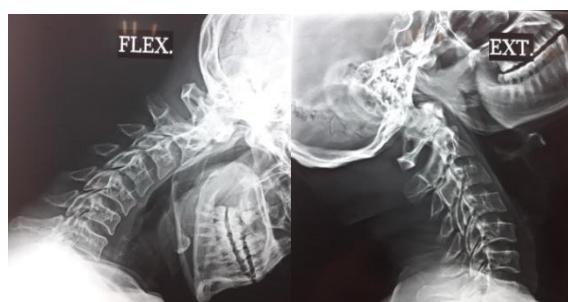


Fig. 16: Preoperative X-ray cervical spine, flexion and extension views showing no instability, lordotic curve

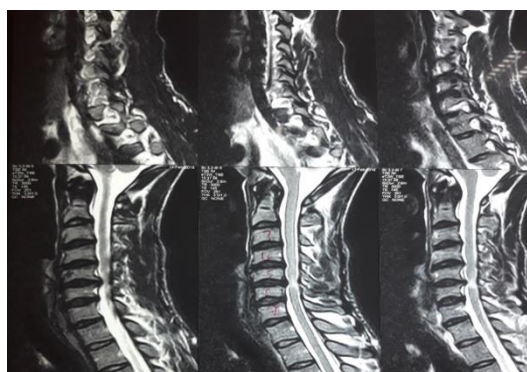

Fig. 17: Preoperative MRI Cervical spine T2 sagittal view showing cervical canal stenosis



Fig. 18: Preoperative MRI cervical spine T2 axial view showing cervical canal stenosis




Fig. 22: Preoperative MRI cervical spine T2 axial view showing cervical canal stenosis

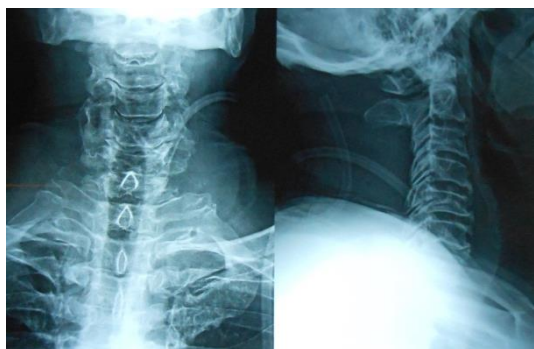


Fig. 19: Postoperative X-ray Cervical spine AP and lateral view showing straightened curve one year postoperative

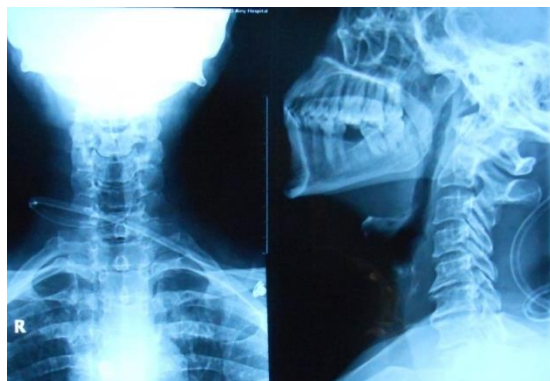


Fig. 23: Postoperative X-ray Cervical spine AP and lateral view showing normal lordotic curve

Case (4)

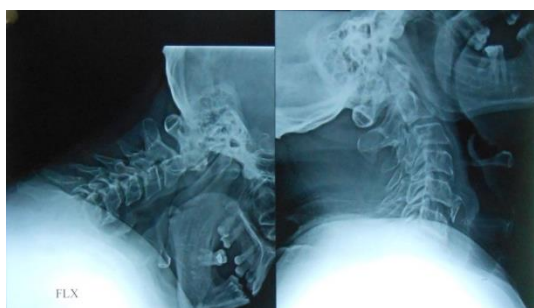

Fig. 20: Preoperative X-ray cervical spine, flexion and extension views showing no instability

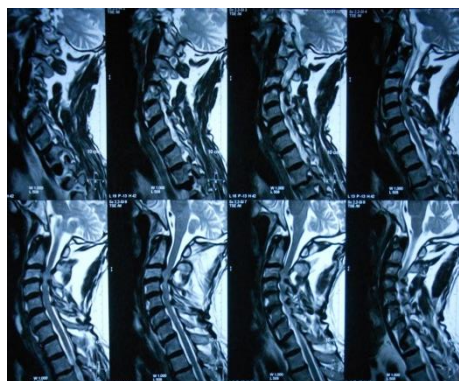

Fig. 21: Preoperative MRI. Cervical spine T2 sagittal view showing cervical canal stenosis

DISCUSSION

In our study, the mean age was 51 years (range, 25-70) with male predominance 80 %. Group (A) included 7 (70 %) males and 3 (30 %) females, while group (B) included 9 (90 %) males and only one (10 %) female. Liu et al.⁵ conducted a retrospective cohort study on a 52 patients with cervical myelopathy the mean age was 56 years (range, 36-77) with male predominance 57.7 %. Shibuya et al.⁶ conducted a retrospective cohort study on 83 patients with cervical myelopathy the mean age for the anterior group was 60.4 years and 64.8 years for the posterior group with male predominance 57.8 %. Kristof et al.⁷ conducted a retrospective cohort study on 103 patients with cervical myelopathy the mean age for the anterior group was 62.5 years and 66 years for the posterior group with male predominance 74.6 %.

In this study, in group (A), Neck pain was the commonest presenting symptom occurring in 8 patients (80 %) followed by numbness occurring in 7 patients (70%). In group (B), heaviness in both upper and lower limbs was the commonest presenting symptom occurring in 8 patients (80 %) followed by neck pain occurring in 8 patients (80 %). Houten et al.⁸ reported that upper extremity sensory disturbance was the main presenting symptom in 89% of patients, gait difficulty in 76% of patients, neck pain and brachialgia occurring in 23% and 18% respectively. In the study done by Bennie et al.⁹ the most important presenting symptom was gait difficulty in 80.3% and upper extremity sensory complain in 82.9%.

In this study, results showed that there was 60 %, 30 %, and 10 % of the patients had 1, 2 and 3 levels in the anterior group respectively while 30%, 60%, and 10% of the patients had 2, 3 and 4 levels in the posterior group respectively. Liu et al.⁵ results showed that there was 68 %, 28%, and 4 % of the patients had 3, 4 and 5 levels in the anterior group respectively while 37 %, 59%, 4% of the patients had 3, 4 and 5 levels in the posterior group respectively. Shibuya et al.⁶ results showed that there was 17.6 %, 47.1%, and 35.3 % of the patients had 1,2 and 3 levels in the anterior group respectively while 22.4 %, 44.9%, and 32.7% of the patients had 2, 3 and 4 levels in the posterior group respectively. Edwards et al.¹⁰ results showed that there was 84.6 % and 15.4% of the patients had 3 and 4 levels in the anterior group respectively while 7.7 % and 92.3% of the patients had 3 and 4 levels in the posterior group respectively.

In our study, the mean operative time per level for the anterior group was 67.8 minutes while it was 39.6 minutes only in the posterior group. Liu et al.⁵ results showed that the mean operation time for the anterior group was 115.9 minutes while it was 187.8 minutes in the posterior group. Shibuya et al.⁶ results showed that the mean operation time was 265, 334, and 371 minutes for the 1, 2 and 3 levels of the anterior group respectively while it was 175 minutes in the posterior group. Kristof et al.⁷ results showed that the mean operation time for the anterior group was 229.2 minutes while it was 183.8 minutes in the posterior group. Edwards et al.¹⁰ results showed that the mean operation time for the anterior group was 224 minutes while it was 216 minutes in the posterior group.

Myelopathy scores: In our study, the mean preoperative Nurick's scores were 2.67 0.87 in the anterior group and 2.87 1.02 in the posterior group, with an overall improvement in the postoperative Nurick's scores (mean = 2.2 0.98) in the anterior group and (mean = 2.21.11) in the posterior group, with a P value of 0.05, which is statistically insignificant. According to Edwards et al.¹⁰, the mean preoperative Nurick's scores for the anterior group were 1.9 and 2.3, respectively, with an overall improvement in the postoperative Nurick's scores for the anterior group (mean = 1) and the posterior group (mean = 0.8). Kristof et al.⁷ results showed that the mean preoperative Nurick's scores was 3 in the anterior group and 3 in the posterior group with an overall results showed no change in the score with range of change from -2 to +2. Lemus et al.¹¹ results showed that the mean preoperative Nurick's scores was 3.73 in the anterior group and 3.82 in the posterior group with an overall improvement in the postoperative Nurick's scores for the anterior group (mean = 0.73) and the posterior group (mean = 0.3).¹¹

Pain scores: The preoperative pain in the anterior group was 5.5 on the VAS scale, while it was 4.9 in the posterior group, with an overall improvement in the mean postoperative VAS scores for the anterior group of 4 and the posterior group of 2.8, with a P value of 0.05, which is statistically insignificant. Only one research employed the Visual analogue score (VAS) scale to compare pain levels across the

two groups. According to the findings of Kristof et al.⁷ the anterior group had preoperative pain with a mean intensity of 4 on the VAS scale, while the posterior group had 3.54, with an overall decrease in postoperative VAS ratings for the anterior group of one point and the posterior group of 0.5 point.

After applying Odom's criteria to assess the patient's satisfaction with the procedure's outcome, we found no significant differences between the two groups in our study. The result score using Odom's criteria was good or excellent in 60% of the cases, whereas it was good or outstanding in 50% of the cases in group (B), with a P value of 0.05, which is statistically insignificant. According to Nirala et al.¹² the anterior group's result score using Odom's criteria was good or outstanding in 81 percent of cases. According to Deniz et al.¹³ the anterior group's result score using Odom's criteria was good or outstanding in 81 percent of cases. According to Mario et al.¹⁴ the anterior group's result score was good or outstanding in 79 percent of cases, whereas the posterior group's score was good or excellent in 83 percent of cases.

The study records of postoperative complications were relatively inconsistent between studies and the definition of complications varied. Some studies provided all complications, whereas some provided the overall complications rate. The postoperative complication rate was slightly higher in the anterior group compared with the posterior group.

C5 palsy: Evaluation of the postoperative C5 palsy was carried out immediately postoperatively. In our study, the rate of C5 palsy was 10 % of the posterior approach group while it was 0% of the anterior approach group. Liu et al.⁵ results showed that there was no patients developed C5 palsy in the anterior group while there was 7.4% of the posterior group developed C5 palsy. Shibuya et al.⁶ results showed that there was 9% of the anterior group developed C5 palsy while there was 10 % of the posterior group developed C5 palsy. Yonenobu et al.¹⁵ results showed that there was 10 % of the anterior approach group developed C5 palsy while there was 7 % of the posterior approach group developed C5 palsy.

Superficial Infection: Evaluation of the postoperative infection was carried out immediately postoperatively, day 14 postoperatively and every six months by checking if there is any fever, wound redness, hotness, and/or discharge. In our study, the rate of infection was 0 % of the anterior group and 10 % in the posterior group managed by wound culture and sensitivity and I.V. antibiotics were given according to the organism with great improvement without the need for surgical debridement. Kristof et al.⁷ results showed that there was 2 % of the anterior group developed infection while there was 6.5 % of the posterior group developed infection. Benzal et al.¹⁶ results showed that there was 5.9 % of the anterior group developed infection while they didn't report if there was infection in the posterior group.

Dysphagia: Evaluation of the postoperative dysphagia was carried out immediately postoperatively, day 14 and six months postoperatively. In our study, the rate of dysphagia was 20 % of the anterior approach group while there

was no dysphagia in the posterior approach group which was transient and improved on day-14 postoperatively follow-up. Liu et al.⁵ results showed that there was 8% of the anterior group developed dysphagia while there was no patients developed dysphagia in the posterior group. Kristof et al.⁷ results showed that there was 7.1% of the anterior approach group developed dysphagia while there was no patients developed dysphagia in the posterior group. Edwards et al.¹⁰ results showed that there was 30.8% of the anterior group developed dysphagia while there was no patients developed dysphagia in the posterior group.

Liu et al.⁵ results showed that there was 8% of the anterior group developed temporary hoarseness of voice while there was no patients developed hoarseness of voice in the posterior group. Kristof et al.⁷ results showed that there was 7.1% of the anterior group developed hoarseness of voice while there was no patients developed hoarseness of voice in the posterior group. Edwards et al.¹⁰ results showed that there was 15.4% of the anterior group developed hoarseness of voice while there was no patients developed hoarseness of voice in the posterior group.

Dural tear: In our study, the rate of Dural tear was 10 % of the anterior group managed intraoperatively by muscle graft with no subsequent leak or collection while there was no dural tear in the posterior group. None of the cervical myelopathy studies recorded the rate of dural tear among their patients. They were only recorded in the OPLL studies which were excluded from our study.

Neurological deterioration: Evaluation of the postoperative motor power was carried out immediately postoperatively and during the follow up visits. In our study, 10 % of both groups (one in each group) develop temporary neurological deterioration after surgery which improved on physiotherapy.

Edwards et al.¹⁰ results showed that there was 10 % of the anterior group developed neurological deterioration after surgery while there was no cases of the posterior group that developed any deterioration after surgery. Yonenobu et al.¹⁵ results showed that there was 9.8 % of the anterior group developed neurological deterioration after surgery while in the posterior group the percentage was 7.1 %.

In our study, at one year follow up, no cases of pseudoarthrosis were detected by x-ray in group (A) or group (B) patients. In group (A), One case of cage subsidence (10 %) were detected in the lowermost segment by about 3mm with no radiological signs of instability. While in group (B), only one patient (10 %) developed straightened curve with no clinical or radiological signs of instability. Liu et al.⁵ results showed that there was 4% of the anterior group developed pseudoarthrosis while they didn't report the cervical alignment in their study for the posterior approach group. Kristof et al.⁷ results showed that there was 16.6% of the anterior group developed pseudoarthrosis while they didn't report the cervical alignment in their study for the posterior group. Edwards et al.¹⁰ results showed that there was 7.7%

of the anterior group developed pseudoarthrosis while there was no patients developed any loss of lordosis curve in the posterior group.

CONCLUSION

There is no significant difference between both groups in terms of myelopathy improvement. Postoperative pain is much less in the anterior group than in the posterior group. The average hospital stay is greater in the posterior group. however, the anterior group patients have nearly double the operative time and increased the risk of reversible dysphagia while the posterior group has more rate of C5 palsy and infection.

Conflict of interest : none

REFERENCES

1. Ghogawala Z, Coumans JV, Benzel EC, Ventral versus dorsal decompression for cervical myelopathy: Surgeons' assessment of eligibility for randomization in a Proposed Randomized control trial. Results of a survey of the cervical spine research society. *Spine*. 2007; 32:429-36.
2. Baron EM & Young WF, Cervical myelopathy: a brief review of its pathophysiology, clinical course, and diagnosis. *Neurosurgery*. 2007; 60: 1-35.
3. Kadanka Z, Mares M, Bednarík J, Predictive factors for mild forms of cervical myelopathy treated conservatively or surgically. *Eur J Neurol*. 2005; 20:12-16.
4. Klineberg E. Cervical myelopathy: a review of the evidence. *Orthop Clin North Am*. 2010; 41:193-202.
5. Liu T, Yang HL, Xu YZ, ACDF with the PCB cage-plate system versus laminoplasty for multilevel cervical myelopathy. *Spinal Disord Tech*. 2011; 24:213-20.
6. Shibuya S, Komatsubara S, Oka S, Differences between subtotal corpectomy and laminoplasty for cervical myelopathy. *Spinal Cord*. 2010; 48:214-20.
7. Kristof RA, Kiefer T, Thudium M, Comparison of ventral corpectomy and plate-screw-instrumented fusion with dorsal laminectomy and rod-screw-instrumented fusion for treatment of at least two vertebral-level cervical myelopathy. *Eur Sp*. 2009; 18:1951-6.
8. Houten JK & Louis N. Clinical Correlation of Cervical Myelopathy with the Hoffmann's Sign. *Spine Journal meeting abstracts* 2007.
9. Bennie WC, Michael AL, Haroon FC, Cooper. Cervical Myelopathy: Patterns of Neurological Deficit and Recovery after Anterior Cervical Cervical Decompression. *Neurosurgery*. 1999; 44 (4): 762-769.

10. Edwards CC, Heller JG & Murakami H, Corpectomy versus laminoplasty for multilevel cervical myelopathy: an independent matched-cohort analysis. *Spine*. 2002; 27: 1168-75.
11. Lemus M, Bustamante A, Mucino A, Clinical outcome of anterior vs posterior approach for cervical myelopathy. *J Orthop*. 2016; 13: 123–126.
12. Nirala AP, Husain M & Vatsal DK, A retrospective study of Multiple Interbody grafting and long segment strut grafting following multilevel anterior cervical decompression. *British Journal of Neurosurgery*. 2004; 18(3):227-232.
13. Deniz K, Serdar O, Arzu G, Outcomes for combined anterior and posterior surgical approaches for patients with multisegmental cervical myelopathy. *J Clin Neurosci*. 2009; 16(3):404-9.
14. Mario C, Alexander A, Daniel K, Comparison between anterior and posterior decompression with instrumentation for cervical spondyltic myelopathy: sagittal alignment and clinical outcome.2010;10.3171/2010.1FOCUS09253.
15. Yonenobu K, Hosono N, Iwasaki M, Laminoplasty versus subtotal corpectomy. A comparative study of results in multisegmental cervical myelopathy. *Spine*. 1992; 17:1281.
16. Benzel EC, Lançon J, Kesterson L, Cervical laminectomy and dentate ligament section for cervical myelopathy. *Spinal Disord*. 1999; 4:186-95.