



7-1-2022

## Validity of Estimation of IL-6 level over Cancer Antigen-125 (CA-125) with Sonographic Criteria in the Prediction of Ovarian Cancer in Patients with Adnexal Mass

Mohamed Ali

*Ministry of Health and Population, dr.moh.gaafar2016@gmail.com*

MOHAMED FOUAD

*Professor of Obstetrics and Gynecology Faculty of Medicine Al-Azhar University in Cairo, samiraziz@hotmail.com*

ISMAIL MIERA

*Professor of Obstetrics and Gynecology Faculty of Medicine Al-Azhar University in Cairo, ismailmira626449@gmail.com*

Mohamed EL-Shorbagy

*Professor of Clinical Pathology Faculty of Medicine AL-Azhar University, elshorbagy2288@gmail.com*

Follow this and additional works at: <https://aimj.researchcommons.org/journal>



Part of the [Medical Sciences Commons](#), [Obstetrics and Gynecology Commons](#), and the [Surgery Commons](#)

### How to Cite This Article

Ali, Mohamed; FOUAD, MOHAMED; MIERA, ISMAIL; and EL-Shorbagy, Mohamed (2022) "Validity of Estimation of IL-6 level over Cancer Antigen-125 (CA-125) with Sonographic Criteria in the Prediction of Ovarian Cancer in Patients with Adnexal Mass," *Al-Azhar International Medical Journal*: Vol. 3: Iss. 7, Article 13.

DOI: <https://doi.org/10.21608/aimj.2022.117269.1820>

This Original Article is brought to you for free and open access by Al-Azhar International Medical Journal. It has been accepted for inclusion in Al-Azhar International Medical Journal by an authorized editor of Al-Azhar International Medical Journal. For more information, please contact [dryasserhelmy@gmail.com](mailto:dryasserhelmy@gmail.com).

## Validity of Estimation of IL-6 Level over Cancer Antigen-125 (CA-125) with Sonographic Criteria in the Prediction of Ovarian Cancer in Patients with Adnexal Mass

Mohamed Gaafar Osman Ali <sup>1,\*</sup> MSc, Mohamed Samir Fouad <sup>2</sup> MD,  
Ismail Mohamed Miera <sup>2</sup> MD and, Mohamed Saied EL-Shorbagy <sup>3</sup> MD.

*\*Corresponding Author:*

Mohamed Gaafar Osman Ali  
[dr.moh.gaafar2016@gmail.com](mailto:dr.moh.gaafar2016@gmail.com)

*Received for publication February 01, 2022; Accepted July 30, 2022; Published online July 30, 2022.*

*doi: 10.21608/aimj.2022.117269.1820*

**Citation:** Mohamed G. , Mohamed S. , Ismail M. Validity of Estimation of IL-6 Level over Cancer Antigen-125 (CA-125) with Sonographic Criteria in the Prediction of Ovarian Cancer in Patients with Adnexal Mass. AIMJ. 2022; Vol.3-Issue7 : 70-75.

<sup>1</sup>Obstetrics and Gynecology Department, Aswan Insurance Hospital, Egypt.

<sup>2</sup>Obstetrics and Gynecology Department, Faculty of Medicine, Al-Azhar University Cairo, Egypt.

<sup>3</sup>Clinical Pathology Department, Faculty of Medicine, Al-Azhar University Cairo, Egypt.

### ABSTRACT

**Background:** Ovarian cancer is one of the most serious genital cancer in women. Pre-operative differentiation of adnexal mass is important for appropriate diagnosis and immediate referral to oncology centers for optimal surgical intervention.

**Aim of the work:** To evaluate the risk of malignancy preoperatively in patients presented with adnexal mass for referral of patients with suspected malignancy to tertiary center, which may improve survival.

**Patients and methods:** In this study, 140 women with adnexal mass were included (benign lesions 80 and malignant tumors 60), the performance of ultrasound criteria and subjective assessment was excellent in the differentiation between benign lesions and malignant tumors.

**Results:** CA 125 values (with Cut off >111 (U/ml) and AUC of CA125 level (U/ml) was 0.860 ( $p < 0.001$ ) had excellent and high ability to predict malignant tumors with sensitivity 70.0% and had a higher probability of actually having a histologically malignant tumor. AUC of IL-6 level (pg/ml) was 0.813 ( $p < 0.001$ ) with Cut off >45 had excellent and high ability to predict malignant tumors with sensitivity 60.0%. Combining CA 125 with IL-6 level (pg/ml) had excellent and high ability to predict malignant tumors with Sensitivity 88.33%.

**Conclusion:** Our data shows that serum IL-6 level is excellent for distinguishing ovarian cancer patients from those with benign lesions. The serum values of these cytokines can be analysed separately or associated with CA 125 which could be used to reinforce confidence in the differentiation of malignant ovarian masses from other ovarian masses.

**Keywords:** Ovarian cancer; Adnexal Mass, ultrasound; CA-125, IL-6.

Most of the adnexal masses in premenopausal female

**Disclosure:** The authors have no financial interest to declare in relation to the content of this article. The Article Processing Charge was paid for by the authors.

**Authorship:** All authors have a substantial contribution to the article.

**Copyright** The Authors published by Al-Azhar University, Faculty of Medicine, Cairo, Egypt. Users have the right to read, download, copy, distribute, print, search, or link to the full texts of articles under the following conditions: Creative Commons Attribution-Share Alike 4.0 International Public License (CC BY-SA 4.0).

will be less severe; hence a precise examination is

### INTRODUCTION

Ovarian cancers are one of the most fatal genital cancers in female.<sup>1</sup> In 2012 ovarian cancers were diagnosed in 238,719 female all over the world and led to 151,900 deaths.<sup>2</sup> When ovarian cancers is discovered early, especially when it is restricted to the ovary, the 5-year survival rate ascend to 89 percent, furthermore 10-year survival rate progress to 84 percent.<sup>3</sup>

Ultrasound has sensitivities of 0.82–0.93, specificities of 0.68–0.90, and a positive predictive value of 0.46, as estimated by ultrasound scores alone or when it was used as a piece of risk of malignancy indices (RMI).<sup>4</sup>

required. The aim of this examination should be the determination of the likelihood of a cancer. Regardless the fact that ovarian tumors is uncommon in premenopausal female, excluding a malignancy without surgery is sometimes a difficult process.<sup>5,6</sup>

There is an obvious headway in the prognosis of patients having epithelial ovarian neoplasms who had careful surgical staging that confirms early disease in comparing to those who had an early-stage disease without surgical staging. So it is intense to assess the risk of malignancy before the operation, as reference of patients with suspected malignancy to specialist who is profoundly prepared for management of ovarian cancers might enhance their survival.<sup>7</sup>

CA125 is a 22,000-amino-acid mucin glycoprotein that belongs to the cancer antigen family.<sup>8</sup> Cancer antigen 125 (CA125) was the only biomarker utilized in diagnosis of ovarian tumors which has been FDA-approved before the year 2008.<sup>9</sup>

It has been demonstrated that IL-6 is a multifunctional cytokine which manages immune reactions. It was confirmed that the high levels of serum IL-6 were a unique feature of ovarian tumors as compared to other gynecological neoplasms.<sup>10</sup> Han et al.,<sup>3</sup> found that CA125, and IL-6, was promising in diagnosing high-grade serous ovarian carcinoma at earlier stage.

## PATIENTS AND METHODS

This observational review was led at a tertiary oncology centers including Al-Hussein Hospital at Al-Azhar University during the period from July 2019 to August 2021. Blood samples collected from a 169 women with adnexal mass and for whom a decision to proceed with surgical intervention is decided. 140 women showed normal routine investigations while the other 29 were not appropriate and some of them didn't complete the study. In this study, 140 women with adnexal mass (benign 80 and malignant 60) were included.

Patients Included in this study were a female patients >18 years old presented with adnexal mass diagnosed

by U/S, Not under cancer treatment by chemo- or radiotherapy, No surgery on the last 12 months. Informed consent obtained. All specimens after operation could be examined histopathologically.

The excluded patients were the pregnant patients, the patients with previous bilateral oophorectomy, the patients with no surgical confirmation or unavailable histopathology could be done, and the patients refusing to give consent.

Abdominal Ultrasonography was done for all the attending patients and the blood samples for IL-6 and CA125 were obtained within 30 days before operation date.

The significance of the achieved outcomes was assessed at a 5% level of significance. The area under the ROC curve announces diagnostic performance of the test using the Chi-square test, Fisher's exact correction, Student t-test, Mann Whitney test, and Receiver operating characteristic curve (ROC). A performance of more than 50% is considered acceptable, whereas a performance of more than 100% is considered excellent. The ROC curve also provides for a performance comparison between the two tests.

## RESULTS

The malignant tumors showed a higher percentage of Ascites, Solid areas, Multi-locular and Papillary projection than benign lesions. Table (1). Also, malignant tumors showed a higher CA125 levels (U/ml) than benign lesions. Also, showed a higher IL-6 levels (pg/ml) than benign lesions. Table (2).

As regard CA125 level (U/ml) in Pre-menopause and Post-menopause the malignant tumors showed a higher CA125 levels (U/ml) than benign lesions. Also, Malignant tumors showed a higher IL-6 levels (pg/ml) than benign lesions. Table (3).

AUC of CA125 levels (U/ml) was 0.860 ( $p < 0.001$ ) with Cut off >111 had excellent and high ability to predict malignant tumors with Sensitivity 70.0%. AUC of IL-6 levels (pg/ml) was 0.813 ( $p < 0.001$ ) with Cut off >45 had excellent and high ability to predict malignant tumors with Sensitivity 60.0%. Table (4)

AUC of CA125 level (U/ml) + IL-6 level (pg/ml) was 0.944 ( $p < 0.001$ ) had excellent and high ability to predict malignant tumors with Sensitivity 88.33%. Table (5)

Sonographic criteria	Benign (n = 80)		Malignant (n = 60)		P-value
	No.	%	No.	%	
Metastasis	0	0.0	1	1.7	0.429
Ascites	4	5.0	13	21.7	0.003*
Solid areas	14	17.5	48	80.0	<0.001*
Laterality					
Unilateral	64	80.0	43	71.7	0.250
Bilateral	16	20.0	17	28.3	
Multi-locular	19	23.8	24	40.0	0.039*
Papillary projection	5	6.3	44	73.3	<0.001*

**Table 1:** Comparison in-between the two studied groups as indicated by Sonographic criteria

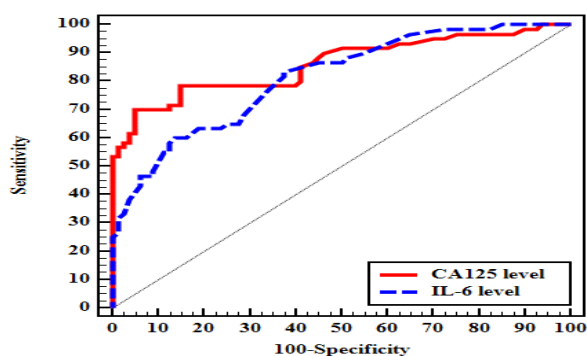
	Benign (n = 80)	Malignant (n = 60)	P-value
CA125 level (U/ml)	55.86 ± 43.12	357.05 ± 296.40	<0.001*
IL-6 level (pg/ml)	33.53 ± 10.79	49.48 ± 14.01	<0.001*

**Table 2:** Comparison in-between the two studied groups as indicated by CA125 level and IL-6 level

Pre-menopause (n = 63)	Post-menopause (n = 77)
------------------------	-------------------------

	Benign (n = 45)	Malignant (n = 18)	Benign (n = 35)	Malignant (n = 42)
CA125 level (U/ml)	35.38 ± 18.10	100.39 ± 70.01	82.20 ± 51.24	467.05 ± 288.22
U (p)	153.0* (<0.001*)		168.50* (<0.001*)	
IL-6 level (pg/ml)	32.82 ± 10.64	48.78 ± 15.32	34.43 ± 11.07	49.79 ± 13.60
U (p)	168.0* (<0.001*)		273.0* (<0.001*)	

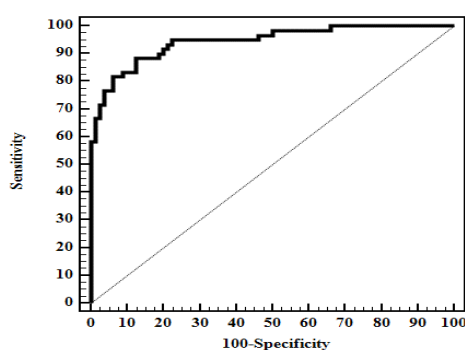
**Table 3:** Comparison between benign and malignant groups as indicated by CA125 level and IL-6 level (n = 140)



**Fig. 1:** ROC curve for CA125 level and IL-6 level to discriminate malignant tumors (n = 60) from benign (n = 80)

	AUC	p	95% C.I	Cut off#	Sensitivity	Specificity	PPV	NPV
CA125 level (U/ml)	0.860	<0.001*	0.794 – 0.926	>111	70.0	95.0	91.3	80.9
IL-6 level (pg/ml)	0.813	<0.001*	0.743 – 0.882	>45	60.0	86.25	76.6	74.2

**Table 4:** Validity (AUC, sensitivity, specificity) CA125 level and IL-6 level to discriminate malignant (n = 60) from benign (n = 80)



**Fig.2:** ROC curve for combination of CA125 level and IL-6 level to discriminate malignant (n = 60) from benign (n = 80)

	AUC	p	95% C.I	Sensitivity	Specificity	PPV	NPV
CA125 level (U/ml) + IL-6 level (pg/ml)	0.944	<0.001*	0.907 – 0.981	88.33	87.50	84.1	90.9

**Table 5:** Validity (AUC, sensitivity, specificity) combination of CA125 level and IL-6 level to discriminate malignant (n = 60) from benign (n = 80)

## DISCUSSION

Ultrasonography (US) is as yet the most involved imaging strategy for recognizing and describing adnexal masses.<sup>12-16</sup> The combined experience of several institutions all over the world yielded an excellent wealth of data that enables for accurate classification of around 90% of adnexal masses based on their US characteristics.<sup>17, 18</sup>

In this study, benign lesions were 80 cases(57.1%) and malignant tumors were 60 cases(42.9%). According to our findings, a study done by Yogambal M et al found that 78.6% had benign lesions and 20.65% had malignant neoplasms.<sup>19</sup> Nazneen et al. discovered among the study population showed that benign tumors were 72% and malignant tumors were 28%.<sup>20</sup>

In the current review, the mean age for benign lesions was  $46.99 \pm 11.09$  years and mean age for malignant tumors was  $54.68 \pm 11.45$  years. The difference was significant. As per our outcomes Setiawan et al.,<sup>21</sup> stated that, most of malignant ovarian tumors were normally diagnosed after menopause between the age of 60 to 64 years. Another study found that the majority of ovarian cancer occurrences was after menopause, with 73 percent of ovarian cancer cases occurring after menopause.<sup>22</sup>

CA125 levels (U/ml) were greater in malignant tumors than in benign lesions. Niloff et al.<sup>23</sup> announced about serum CA-125 level which was more with individuals having advanced or recurrent endometrial cancer, which matched our findings.

Several other studies found that preoperative CA-125 levels were linked to advanced-stage illness and the occurrence of extrauterine disease.<sup>20-24</sup> Greater CA-125 levels (>35 U/ml) were related to more advanced stages and grades, lymph node metastases, and with poorer survival, according to Sood et al.<sup>24</sup> who looked at 210 women with endometrial cancer. They also found that high CA-125 levels gives best anticipation for extra uterine illness. Koper et al.<sup>25</sup> found that the higher CA-125 levels present the more involvement of the adnexa in patients with endometrial neoplasms.

In our study, women with high CA 125 values (Cut off >111 (U/ml) and AUC of CA125 level (U/ml) was 0.860 (p 0.001) had good and high capacity to predict malignant tumors with sensitivity 70.0 percent and a greater risk of actually having a histologically malignant tumor. In patients with endometrial cancer, serum CA-125 became broadly utilized for preoperative and postoperative assessment. Landolfo et al. (2020)<sup>26</sup> calculate the ability of using tumor-related proteins in distinguishing benign from malignant adnexal masses. CA125 showed the best univariable AUC for discrimination between benign and malignant tumors. The findings support the importance of CA125 in detecting cancer.

Hartman et al.<sup>27</sup> used CA 125 testing and ultrasound criteria for evaluation of the possibility of prediction of malignancy in patients with adnexal mass. Ultrasound criteria were used to appropriately classify the majority of cancers. When it came to distinguishing between

malignant and benign adnexal tumors, CA 125 alone performance was worse than using ultrasonography. Just in sonographically malignant tumors did CA 125 estimation help in the conclusion of malignancy, improving overall specificity. To discriminate in-between borderline ovarian tumors and stage I epithelial ovarian cancer, Zacharakis et al.<sup>28</sup> looked at the significance of preoperative serum cancer antigen 125 (CA-125) levels in connection to ultrasonographic characteristics (EOC). CA-125 > 100 IU mL preoperatively, with a substantial absence of papillary projections and presence of solid component, appears to increase the ability of discrimination in favour of stage I epithelial ovarian tumor.

The mean IL-6 level in the current research was  $33.53 \pm 10.79$  for benign lesions and  $49.48 \pm 14.01$  for malignant lesions. There was a statistically significant difference in IL-6 level (pg/ml) between benign lesions and malignant tumors ( $p \leq 0.001^*$ ). In the current study, malignant tumors had a higher IL-6 level (pg/ml) than benign lesions, with AUC of IL-6 level (pg/ml) of 0.813 and Cut off >45 having good and high capacity to predict malignant tumors with sensitivity of 60.0 percent. In accordance with our results, Amer et al.,<sup>29</sup> intended to give an inclusive meta-analysis for the diagnostic performance of IL-6 in advanced and early-stage ovarian cancer. The plasma/serum IL-6 mean level in late stages ovarian tumors was 23.88 pg/mL, and in the early stages of ovarian tumors was 16.67 pg/mL, significantly more than in the healthy women at 3.96 pg/mL. Serum/plasma IL-6 provided 76.7% sensitivity and 72% specificity. This study highlights on the utilization of IL-6 in early detection of patient having ovarian tumors.

In patients diagnosed having adnexal mass and did a surgery for ovarian torsion, Daponte et al.<sup>30</sup> found that in patients with IL-6 serum levels more than or equal to 10.2 pg/mL had a 16-fold increased risk of ovarian torsion. The levels of IL-6 might support the early discovery of the ovarian twist and take into account suitable careful surgical intervention. According to Kampan et al (2020).<sup>31</sup> Median sera IL-6 was more in ovarian cancer patients in comparison to patients having a benign mass or controls having normal ovaries (28.3 vs. 7.3 vs. 1.2 pg/ml,  $p < 0.0001$ ). Addition of IL-6 to the traditional assays enhanced their overall prognostic power.

## CONCLUSION

Serum IL-6 can be examined related with CA 125 and could be utilized to build up trust in the differentiation of malignant ovarian masses from other ovarian masses.

Conflict of interest : none



## REFERENCES

1. Lowe KA, Chia VM, Taylor A, O'Malley C, Kelsh M, et al. An international assessment of ovarian cancer incidence and mortality. *Gynecologic oncology*. 2013;130(1): 107-14.
2. Torre LA, Bray F, Siegel RL, Ferlay J, Lortet-Tieulent J, et al. Global cancer statistics, 2012. *CA Cancer J Clin*. 2015 Mar;65(2):87-108.
3. Han C, Bellone S, Siegel ER, Altwerger G, Menderes G, et al. A novel multiple biomarker panel for the early detection of high-grade serous ovarian carcinoma. *Gynecologic oncology*. 2018; 149:585-91.
4. Manegold-Brauer G, Bellin AK, Tercanli S, Lapaire O, Heinzelmann-Schwarz V. The special role of ultrasound for screening, staging and surveillance of malignant ovarian tumors: distinction from other methods of diagnostic imaging. *Arch Gynecol Obstet*. 2014; 289:491-8.
5. Timmerman D, Van Calster B, Testa AC, Guerriero S, Fischerova D, et al. Ovarian cancer prediction in adnexal masses using ultrasound-based logistic regression models: a temporal and external validation study by the IOTA group. *Ultrasound Obstet Gynecol*. 2010; 36: 226-34.
6. Givens V, Mitchell GE, Harraway-Smith C, Reddy A, Maness DL. Diagnosis and management of adnexal masses. *Am Fam Physician*. 2009 Oct 15;80(8):815-20.
7. Kaijser J, Sayasneh A, Van Hoorde K, Ghaem-Maghamsi S, Bourne T, et al. Presurgical diagnosis of adnexal tumours using mathematical models and scoring systems: a systematic review and meta-analysis. *Hum Reprod Update*. 2014 May-Jun;20(3):449-62.
8. Choi HJ, Lee YY, Sohn I, Kim YM, Kim JW, et al. Comparison of CA 125 alone and risk of ovarian malignancy algorithm (ROMA) in patients with adnexal mass: A multicenter study. *Current problems in cancer*. 2020; 44:100508.
9. Lan Z, Fu D, Yu X, Xi M. Diagnostic values of osteopontin combined with CA125 for ovarian cancer: a meta-analysis. *Familial cancer*. 2016; 15:221-30.
10. Isobe A, Sawada K, Kinose Y, Ohyagi-Hara C, Nakatsuka E, et al. Interleukin 6 receptor is an independent prognostic factor and a potential therapeutic target of ovarian cancer. *PLoS One*. 2015 Feb 6;10(2):-0118080.
11. Dodge JE, Covens AL, Lacchetti C, Elit LM, Le T, Devries-Aboud M, et al. Preoperative identification of a suspicious adnexal mass: a systematic review and meta-analysis. *Gynecol Oncol*. 2012 Jul;126(1):157-66.
12. Marx J. Cancer biology. All in the stroma: cancer's Cosa Nostra. *Science*. 2008 Apr 4;320(5872):38-41.
13. Zeng F, Wei H, Yeoh E, Zhang Z, Ren ZF, et al. Inflammatory Markers of CRP, IL6, TNF $\alpha$ , and Soluble TNFR2 and the Risk of Ovarian Cancer: A Meta-analysis of Prospective Studies. *Cancer Epidemiol Biomarkers Prev*. 2016 Aug;25(8):1231-9.
14. Li J, Jiao X, Yuan Z, Qiu H, Guo R. C-reactive protein and risk of ovarian cancer: A systematic review and meta-analysis. *Medicine (Baltimore)*. 2017 Aug;96(34):-7822.
15. Van Calster B, Timmerman D, Bourne T, Testa AC, Van Holsbeke C, et al. Discrimination between benign and malignant adnexal masses by specialist ultrasound examination versus serum CA-125. *J Natl Cancer Inst*. 2007 Nov 21;99(22):1706-14.
16. Cao L, Wei M, Liu Y, Fu J, Zhang H, et al. Validation of American College of Radiology Ovarian-Adnexal Reporting and Data System Ultrasound (O-RADS US): Analysis on 1054 adnexal masses. *Gynecol Oncol*. 2021 Jul;162(1):107-12.
17. Patel MD. Practical approach to the adnexal mass. *Radiol Clin North Am*. 2006 Nov;44(6):879-99.
18. Sadowski EA, Rockall AG, Maturen KE, Robbins JB, Thomassin-Naggara I. Adnexal lesions: Imaging strategies for ultrasound and MR imaging. *Diagnostic and interventional imaging*. 2019; 100:635-46.
19. Yogambal M, Arunalatha P, Chandramo-uileswari K, Palaniappan V. Ovarian tumours-Incidence and distribution in a tertiary referral center in south India. *IOSR J Dental Med Sci*. 2014; 13:74-80.
20. Nazneen T, Begum SA, Mahmud T, Khatoun F, Islam F, et al. Preoperative Analysis of CA-I25 and its Relation with Histopathological Study in Ovarian Tumours. *Mymensingh Med J*. 2021 Apr;30(2):402-9.
21. Setiawan VW, Pike MC, Kolonel LN, Nomura AM, Goodman MT, et al. Racial/ethnic differences in endometrial cancer risk: the multiethnic cohort study. *Am J Epidemiol*. 2007; 165: 262-70.
22. Moorman PG, Alberg AJ, Bandera EV, Barnholtz-Sloan J, Bondy M, et al. Reproductive factors and ovarian cancer risk in African-American women. *Ann Epidemiol*. 2016 Sep;26(9):654-62.
23. Niloff JM, Klug TL, Schaetzl E, Zurawski VR Jr, Knapp RC, et al. Elevation of serum CA125 in carcinomas of the fallopian tube, endometrium, and endocervix. *Am J Obstet Gynecol* 1984; 148: 1057-8.
24. Sood AK, Buller RE, Burger RA, Dawson JD, Sorosky JI, et al. Value of preoperative CA-125 level in the management of uterine cancer and prediction of clinical outcome. *Obstet Gynecol* 1997; 90: 441-7.
25. Koper NP, Massuger LF, Thomas CM, Kiemeny LA, Verbeek AL. Serum CA 125 measurements to identify patients with endometrial cancer who require lymphadenectomy. *Anticancer Res*. 1998 May-Jun;18(3B):1897-902.
26. Landolfo C, Achten ETL, Ceusters J, Baert T, Froyman W, et al. Assessment of protein biomarkers for preoperative differential diagnosis between benign and malignant ovarian tumors. *Gynecol Oncol*. 2020 Dec;159(3):811-819.
27. Hartman CA, Juliato CR, Sarian LO, Toledo MC, Jales RM, et al. Ultrasound criteria and CA 125 as predictive variables of ovarian cancer in women with adnexal tumors. *Ultrasound Obstet Gynecol*. 2012; 40:360-6.

28. Zacharakis D, Thomakos N, Biliatis I, Rodolakis A, Simou M, et al. Ultrasonographic markers and preoperative CA-125 to distinguish between borderline ovarian tumors and stage I ovarian cancer. *Acta Obstet Gynecol Scand.* 2013; 92:285-92.
29. Amer H, Kartikasari AER, Plebanski M. Elevated Interleukin-6 Levels in the Circulation and Peritoneal Fluid of Patients with Ovarian Cancer as a Potential Diagnostic Biomarker: A Systematic Review and Meta-Analysis. *J Pers Med.* 2021; 11:1335.
30. Daponte A, Pournaras S, Hadjichristodoulou C, Lialios G, Kallitsaris A, et al. Novel serum inflammatory markers in patients with adnexal mass who had surgery for ovarian torsion. *Fertil Steril.* 2006; 85:1469-72.
31. Kampan NC, Madondo MT, Reynolds J, Hallo J, McNally OM, et al. Pre-operative sera interleukin-6 in the diagnosis of high-grade serous ovarian cancer. *Sci Rep.* 2020; 10:1-5.