



7-1-2022

Comparative Study Between Merocel and Merocel Surgicel Wrap In Management Of Epistaxis

Mohamed Abdelkhalek

ENT department, faculty of medicine, Al-Azhar university, cairo, Egypt, mohamedelneklawy81@gmail.com

Ahmed abdefattah

ENT department, faculty of medicine, Al-Azhar universty, cairo,Egypt, ahmedfatah10@hotmail.com

Ibrahim Eldosoky

ENT department, faculty of medicine, Al-Azhar university, cairo, Egypt, ibrahimeldsokyorl@gmail.com

Follow this and additional works at: <https://aimj.researchcommons.org/journal>



Part of the [Medical Sciences Commons](#), [Obstetrics and Gynecology Commons](#), and the [Surgery Commons](#)

How to Cite This Article

Abdelkhalek, Mohamed; abdefattah, Ahmed; and Eldosoky, Ibrahim (2022) "Comparative Study Between Merocel and Merocel Surgicel Wrap In Management Of Epistaxis," *Al-Azhar International Medical Journal*: Vol. 3: Iss. 7, Article 7.

DOI: <https://doi.org/10.21608/aimj.2022.117744.1808>

This Original Article is brought to you for free and open access by Al-Azhar International Medical Journal. It has been accepted for inclusion in Al-Azhar International Medical Journal by an authorized editor of Al-Azhar International Medical Journal. For more information, please contact dryasserhelmy@gmail.com.

Comparative Study Between Merocel and Merocel Surgicel Wrap in Management Of Epistaxis

Mohamed Adel Abdel-khalek El-Nklawy,¹ MBBCH, Ahmed Mohamed Abdelfattah,¹ MD, Ibrahim Ibrahim Eldosoky,¹ MD.

* Corresponding Author:

Mohamed Adel Abdel-khalek.

mohamedelneklawy81@gmail.com

Received for publication
Februray 04, 2022; Accepted
July 24, 2022; Published online
July 24, 2022.

doi: 10.21608/aimj.2022.117744.1808

Citation: Mohamed A. , Ahmed A. , Ibrahim I.. *Comparative Study Between Merocel and Merocel Surgicel Wrap in Management Of Epistaxis.* AIMJ. 2022; Vol.3- Issue7 :30-37.

¹Internal Medicine Department, Faculty of Medicine, Al-Azhar University, Cairo, Egypt.

²Clinical Pathology Department, Faculty of Medicine, Al-Azhar University, Cairo, Egypt.

ABSTRACT

Background: Epistaxis affects more than half of the population. It impacts both genders and all age groups and is triggered by a variety of etiological variables. Merocel has been a compressed, dehydrated sponge made of hydroxylated polyvinyl acetate that needs to be rehydrated using normal saline to reach its ideal size in the nasal cavity and compress bleeding vessels. It also promotes hemostasis by acting as a platform for platelet aggregation. Surgicel is a regenerated oxidized cellulose that's employed in clinical settings for more than fifty years. It absorbs water and expands to give tamponade at hemorrhage areas.

Aim of the study: The purpose of this research is to compare merocel with merocel surgicel wrap nasal packs for epistaxis management.

Patients and Methods: This research has been conducted on 60 epistaxis patients. They were allocated into 2 groups. The first group (A) consisted of 30 patients managed by a merocel nasal pack. The second group (B) included 30 patients who were treated with the merocel surgicel wrap technique.

Results: The differences between the groups studied are statistically significant (group A & group B) as regard bleeding control. There were 24 patients (80%) with bleeding control in group A while there were 29 patients (96.7%) with bleeding control in group B.

Conclusion: Anterior nasal packing with merocel wrapped surgical is both effective and safe in the management and control of bleeding, as well as more preventive of recurrent attacks than merocel alone in epistaxis patients.

Keywords: Epistaxis; Merocel; surgicel...

Disclosure: The authors have no financial interest to declare in relation to the content of this article. The Article Processing Charge was paid for by the authors.

Authorship: All authors have a substantial contribution to the article.

Copyright The Authors published by Al-Azhar University, Faculty of Medicine, Cairo, Egypt. Users have the right to read, download, copy, distribute, print, search, or link to the full texts of articles under the following conditions: Creative Commons Attribution-Share Alike 4.0 International Public License (CC BY-SA 4.0).

INTRODUCTION

Epistaxis is amongst the most prevalent ENT emergencies, with 60% of the general population reporting it.¹

Men have a higher rate of epistaxis than women.²

The majority of cases may be handled in an emergency room, but some older individuals may need more comprehensive care and hospital stays.³

The carotid arteries, both external and internal, provide a rich vascular supply to the nose. Epistaxis has historically been characterized as either anterior or posterior, without a clear demarcating line.⁴ There are many types of nasal packaging strategies accessible. Merocel packing, inflatable balloons,

Rapid rhino, and petroleum-infused gauze are some of the most commonly used.⁵

Merocel, a compressed, dehydrated sponge consisting of hydroxylated polyvinyl acetate that may expand in size inside the nasal canal and compress a hemorrhage vessel when rehydrated with normal saline, is among the most frequently used nonabsorbable nasal packing materials.⁶

Surgicel is an oxidized cellulose polymer-based hemostatic agent (the unit is polyanhydroglucuronic acid). In 1947, it was first used in clinical practise. It's utilized to control hemorrhage after surgery.⁷

PATIENTS AND METHODS

This research has been conducted on 60 patients with epistaxis. They were allocated into 2 groups.

The first group (A) of 30 patients was managed with a merocel nasal pack. The second group (B) consists of 30 patients who were managed with the merocel surgical wrap technique.

They were presented to emergency and ENT department of Al-Azhar university hospitals from April 2021 to January 2022.

The nasal packs removed from each patient after 48 hours.

follow up was done for each patient weekly for 3 months.

Primary outcome measures: (Rate of success of interventions to stop hemorrhage, pain during nasal pack insertion, and time of insertion for both groups).

Secondary outcome measures: (Rebleeding in both groups).

Inclusion criteria: (Age from 10 – 70 years) - (Both males and females).

Exclusion criteria: (Nasal or nasopharyngeal masses) - (Nasal truma).

RESULTS

This study has been conducted on 60 patients with epistaxis. They have been allocated into 2 groups. The first one (group A) 30patients: treated by merocel nasal pack and the second one (group B) 30patients: treated by merocel surgical wrap nasal pack. They were presented to emergency and ENT department of Al-Azhar University Hospitals between April 2021 and January 2022.

(Table 1) reveals that there are no statistically significant differences ($p\text{-value} > 0.05$) in age and sex between the 2 groups tested (groups A & B). As regards age, the average age in group A was 36.1 ± 15.9 years, while the average age in group B was 36.4 ± 15.3 years. As regards sex, there were 21 men (70%) and 9 women (30%) in group A, while there were 18 men (60%) and 12 women (40%) in group B (Figure 1 and 2).

		Group A (N = 30)		Group B (N = 30)		Stat. test	P-value
Age (years)	Mean	36.1		36.4		T = 0.05	0.954 NS
	±SD	15.9		15.3			
Sex	Male	21	70%	18	60%	X ² = 0.65	0.417 NS
	Female	9	30%	12	40%		

Table 1: Comparison of the studied groups in terms of demographic data. (T: independent sample T test; X²: Chi-square test; NS: $p\text{-value} > 0.05$ is considered non-significant).

(Table 2) reveals that there are no statistically significant differences ($p\text{-value} > 0.05$) in comorbidities between the 2 groups tested (group A & group B) (DM & HTN). As regard DM, there were 4 diabetic patients (13.3%) in group A while there were 2 diabetic patients (6.7%) in group B. As regard HTN, there were 4 hypertensive patients (13.3%) in group A while there were 2 hypertensive patients (6.7%) in group B (Figure 3).

(Table 3) reveals that there are no statistically significant differences ($p\text{-value} > 0.05$) between the 2 groups tested (group A & group B) as regards previous attacks. There were 7 patients (23.3%) with previous attacks in group A while there were 5 patients (16.7%) with previous attacks in group B (Figure 4).

(Table 4) reveals that there are no statistically significant differences ($p\text{-value} > 0.05$) between the 2 groups tested (group A & group B) as regards side. There were 12 patients (40%) of right side, 15 patients (50%) of left side and 3 bilateral patients (10%) in group A while there were 11 patients (36.7%) of right side, 15 patients (50%) of left side and 4 bilateral patients (13.3%) in group B (Figure 5).

(Table 5) reveals that there are no statistically significant differences (**$p\text{-value} > 0.05$**) between the 2 groups tested (group A & group B) as regard pain. There were 19 patients (63.3%) of mild pain, 8 patients (26.7%) of moderate pain and 3 patients (10%) of severe pain in group A while there were 19 patients (63.3%) of mild pain, 9 patients (30%) of moderate pain and 2 patients (6.7%) of severe pain in group B (Figure 6).

(Table 6) reveals that there are no statistically significant differences (**$p\text{-value} = 0.044$**) between the 2 groups tested (groups A & B) as regards bleeding control. There were 24 patients (80%) with bleeding control in group A while there were 29 patients (96.7%) with bleeding control in group B (Figure 7).

(Table 7) reveals that there are no statistically significant differences (**$p\text{-value} = 0.037$**) between the 2 groups tested (groups A & B) as regards recurrence. There were 8 patients (26.7%) with recurrence in group A while there were 2 patients (6.7%) with recurrence in group B (Figure 8).

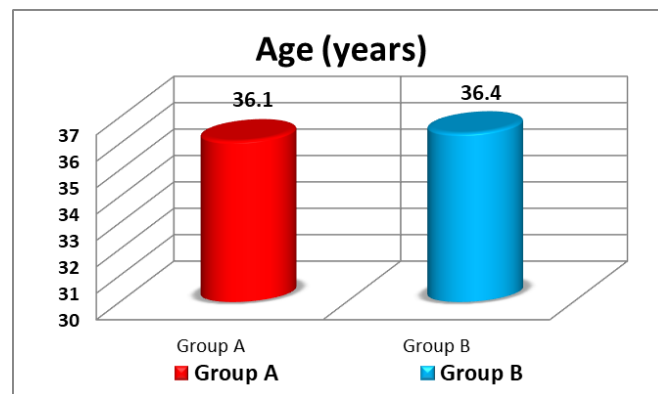


Fig 1: Age comparisons between the studied groups.

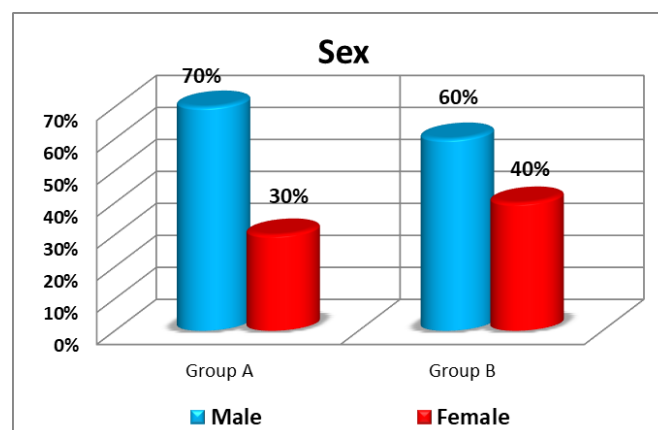


Fig 2: Sex comparisons between the studied groups.

		Group A (N = 30)		Group B (N = 30)		X ²	P-value
DM	No	26	86.7%	28	93.3%	0.74	0.389 NS
	Yes	4	13.3%	2	6.7%		
HTN	No	26	86.7%	28	93.3%	0.74	0.389 NS
	Yes	4	13.3%	2	6.7%		

Table 2: Comorbidity comparisons between the studied groups. (X²: Chi-square test; NS: p-value > 0.05 is considered non-significant).

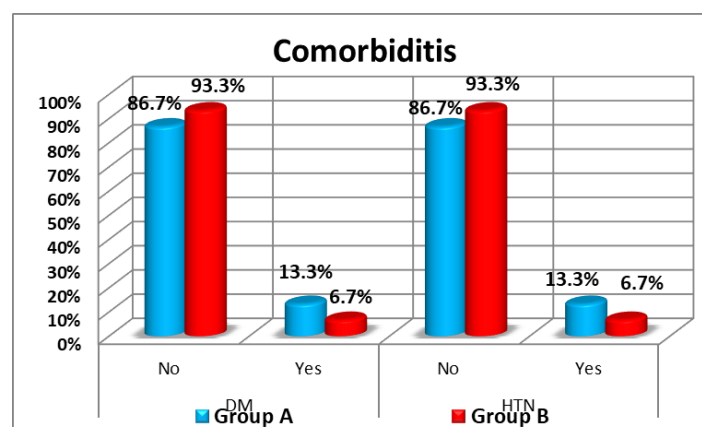


Fig 3: Comparison between studied groups as regard comorbidities.

		Group A (N = 30)		Group B (N = 30)		X ²	P-value
Previous attacks	No	23	76.7%	25	83.3%	0.41	0.519 NS
	Yes	7	23.3%	5	16.7%		

Table 3: Comparison of the studied groups in terms of previous attacks. (X²: Chi-square test; NS: p-value > 0.05 is considered non-significant).

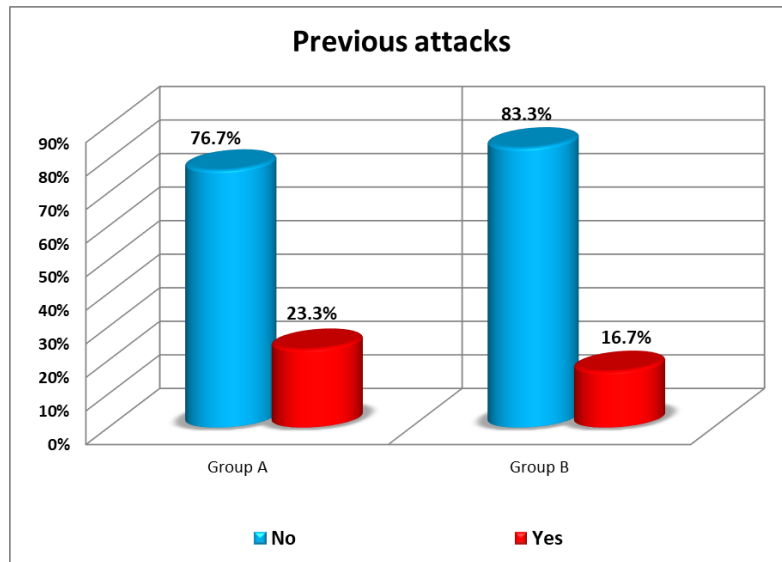


Fig 4: Comparison between studied groups as regard previous attacks.

		Group A (N = 30)		Group B (N = 30)		Stat. test	P-value
Side	Right	12	40%	11	36.7%	X ² = 0.18	0.911 NS
	Left	15	50%	15	50%		
	Bilateral	3	10%	4	13.3%		

Table 4: Comparison of the studied groups in terms of side. (X²: Chi-square test; NS: p-value > 0.05 is considered non-significant).

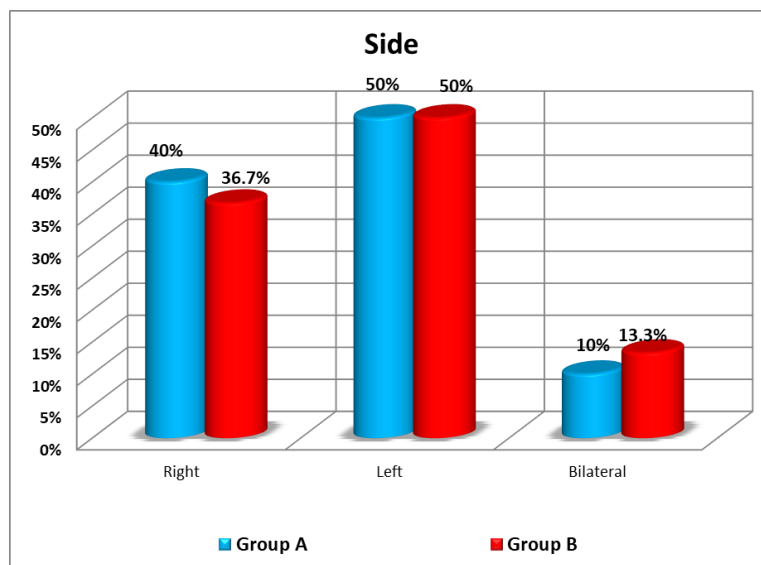
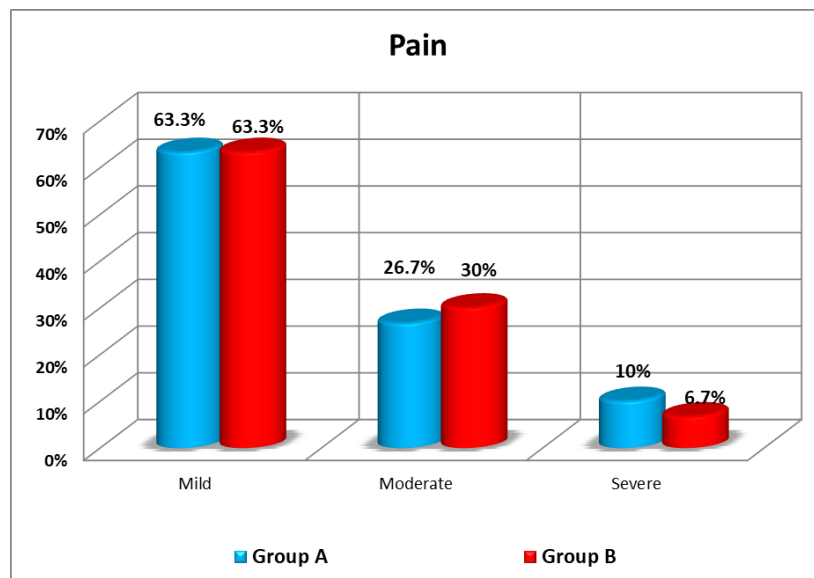


Fig 5: Comparison between studied groups as regard side.

		Group A (N = 30)		Group B (N = 30)		Stat. test	P-value
Pain	Mild	19	63.3%	19	63.3%	$\chi^2 = 0.25$	0.879 NS
	Moderate	8	26.7%	9	30%		
	Severe	3	10%	2	6.7%		

Table 5: Comparison between studied groups as regard pain.. (χ^2 : Chi-square test; NS: p-value > 0.05 is considered non-significant).



		Group A (N = 30)		Group B (N = 30)		χ^2	P-value
Bleeding control	No	6	20%	1	3.3%	4.04	0.044 S
	Yes	24	80%	29	96.7%		

Fig 6: Comparison between studied groups as regard pain.

Table 6: Comparison between studied groups as regard bleeding. (χ^2 : Chi-square test; NS: p-value > 0.05 is considered non-significant).

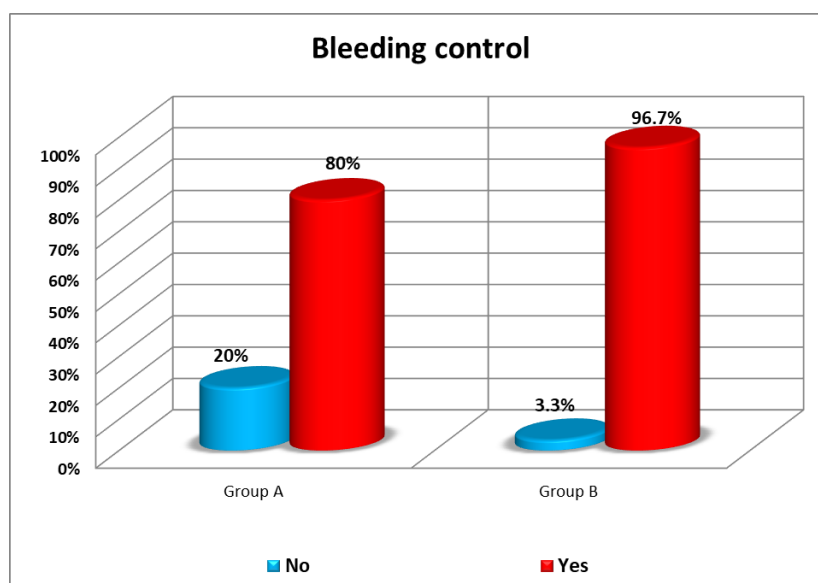
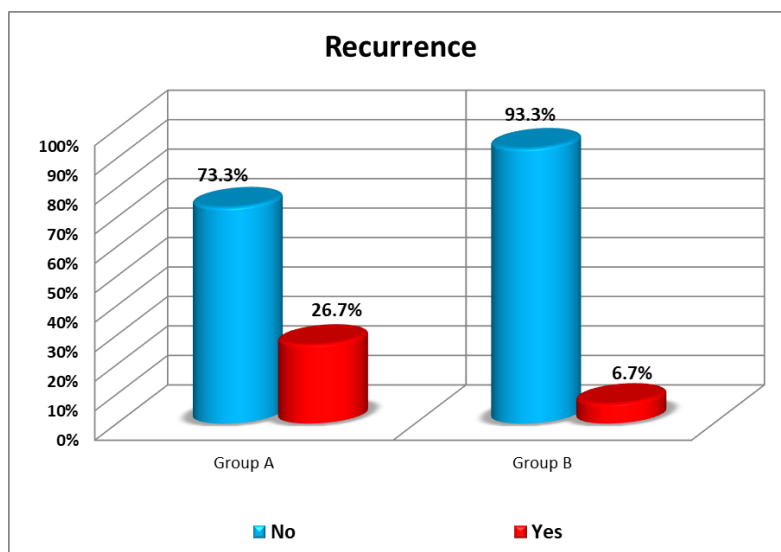


Fig 7: Comparison between studied groups as regard bleeding control.

		Group A (N = 30)		Group B (N = 30)		X ²	P-value
Recurrence	No	22	73.3%	28	93.3%	4.32	0.037 S
	Yes	8	26.7%	2	6.7%		

Table 7: Comparison between studied groups as regard recurrence. (X²: Chi-square test; NS: p-value > 0.05 is considered non-significant).**Fig 8:** Comparison between studied groups as regard recurrence.

DISCUSSION

The most frequent otorhinolaryngologic emergency that necessitates hospitalization is epistaxis, or nasal bleeding. Arterial epistaxis is caused by degenerative alterations in the tunica media.⁸

Shaheen proposed that epistaxis could be caused by local ischemia alterations.⁹

Epistaxis might be caused by numerous local reasons, including septal deviation, chemical irritants, digital trauma, and inflammation, or by systemic causes, including coagulopathies, kidney failure, alcohol addiction, and vascular anomalies.¹⁰

Epistaxis is commonly caused by high blood pressure. It accounts for 31.82–47.3% of all instances¹¹ and may be associated with anxiety in some cases.¹²

Adults are more likely to experience anterior epistaxis, whereas people over 60 are more likely to develop posterior epistaxis.¹³

Furthermore, anterior epistaxis is a frequent ENT emergency. In the literature, there are numerous

theories on the etiology, clinical symptoms, diagnosis, and therapy.¹⁴

Nasal packing procedures include ribbons of gauze, Bismuth iodine paraffin paste, and balloon catheters, among others. While successful, such procedures may result in side effects like infection, patient pain, pressure necrosis of the nasal alae, septal perforation, as well as cardiovascular instability.¹⁵

The ideal nasal pack must provide good epistaxis control, be painless to use, have seamless entry and removal, be comfortable in position, and also have minimal danger of aspiration, tissue sensitivity, and infection. Nevertheless, regardless of the sort of nasal pack utilized, there is always a danger of aspiration.¹⁶

Merocel is a hydroxylated polyvinyl acetate-based compressed and dehydrated pack. It needs to be rehydrated using saline following insertion in order to attain its ideal size inside the cavity of the nose and compress the bleeding vessels. It also serves as a platelet aggregation surface and actively promotes hemostasis.⁶

Surgicel is a type of oxidized regenerated cellulose that has been used in clinical settings for more than

fifty years. It absorbs water and expands to act as a tamponade at haemorrhage points. Its fibers trap fluids, blood proteins, platelets, and cells, forming a gel-like "cluster" which serves as a blood flow barrier and then as a solid matrix.⁷

The therapeutic efficacy of Surgicel, Vaseline gauze, as well as Merocel as a form of nasal packaging was tested. They observed that Surgicel causes less pain both in situ and during evacuation when compared to Merocel and Vaseline packs.¹⁷

Hemostasis is generally achieved with pressure dressings and sutures, although many other products have been created to accomplish the same purpose. Topical hemostatic agents, like sponges, fibrin glue, thrombin, gelatin-thrombin, and various operative sealants, are among these.¹⁸

In vitro and in vivo, oxidized regenerated cellulose is completely absorbed in two weeks with minimum tissue response, and it has antibacterial efficacy versus Gram-positive and Gram-negative bacteria, like methicillin-resistant *Staphylococcus aureus* (MRSA).¹⁹

Because of its size and form, Merocel has a low risk of swallowing or aspiration. Furthermore, it is advised to protect the Merocel string from the dorsum of the nose and the cheek. However,²⁰ described a case in which a nasal pack was eaten during epistaxis therapy, resulting in intestinal blockage and perforation.

In our research, using Merocel with Surgicel, hemorrhage was effectively controlled in 96.7% of patients, with a 6.7% incidence rate. In comparison with treatment by using merocel alone that reported a successful rate of 80% and recurrence rate of 26.7%

The rate of control of bleeding in our study by using merocel with surgical was higher than that in studies by²¹, who observed 96% rates of success and a recurrence rate of 4%.

In other studies, therapy with a Merocel pack alone resulted in success rates of 91.5 %²² and 92.6 %²³, respectively, in terms of bleeding control.

There were no complications with the usage of Merocel or Merocel plus Surgicel in this research. Hemorrhage was effectively controlled in all cases except two, who showed rebleeding after evacuation of the Merocel surgical pack, five patients after removal of the Merocel pack alone, and only one patient after removal of the Merocel surgical pack in studies by²¹.

The Surgicel was left in place in order to ensure the creation of a hemostatic plug that would eventually be absorbed. Our findings, together with those of earlier research, suggest that absorbable packs have few side effects. Patients with anterior nasal packing can also be treated safely and without complications.²⁴

CONCLUSION

The most frequent otorhinolaryngologic emergency that necessitates hospital admittance is epistaxis, or nasal hemorrhage. Degenerative alterations to the tunica media cause arterial epistaxis. The purpose of this research was to compare merocel and merocel surgical wrap for epistaxis management. Our findings show that merocel and surgicel can treat it successfully.

This study was performed on 60 patients with epistaxis. They were allocated into 2 groups. First group (A): 30 patients managed by a merocel nasal pack. The second group (B) included 30 patients who were treated with the merocel surgical wrap technique.

They were presented to emergency and ENT department of Al-Azhar university hospitals from April 2021 to January 2022. The nasal packs removed from each patient after 48 hours. Follow up was done for each patient weekly for 3 months.

The result of the present study revealed the following: The differences between the groups studied are statistically significant (group A & group B) as regards bleeding control. There were 24 patients (80%) with bleeding control in group A while there were 29 patients (96.7%) with bleeding control in group B. In terms of recurrence, there is a statistically significant difference between the 2 groups studied (groups A and B). There have been eight patients (26.7%) with recurrence in group A, while there were two patients (6.7%) with recurrence in group B.

There has been no statistically significant difference in age or gender between the two groups tested (groups A and B). There has been no statistically significant difference between the studied groups (group A & group B) as regards comorbidities (DM & HTN). As regard DM, there were 4 diabetic patients (13.3%) in group A while there were 2 diabetic patients (6.7%) in group B. As regard HTN, there were 4 hypertensive patients (13.3%) in group A while there were 2 hypertensive patients (6.7%) in group B.

There has been no statistically significant difference between the studied groups (group A & group B) as regard previous attacks. There were 7 patients (23.3%) with previous attacks in group A while there were 5 patients (16.7%) with previous attacks in group B.

There has been no statistically significant difference between the studied groups (group A & group B) as regard side. There were 12 patients (40%) of right side, 15 patients (50%) of left side and 3 bilateral patients (10%) in group A while there were 11 patients (36.7%) of right side, 15 patients (50%) of left side and 4 bilateral patients (13.3%) in group B.

There has been no statistically significant difference between the studied groups (group A & group B) as

regard pain. There were 19 patients (63.3%) of mild pain, 8 patients (26.7%) of moderate pain and 3 patients (10%) of severe pain in group A while there were 19 patients (63.3%) of mild pain, 9 patients (30%) of moderate pain and 2 patients (6.7%) of severe pain in group B.

Merocel wrapped surgical anterior nasal packing is both effective and safe in management and control of bleeding, as well as prevention of recurrent attacks more than merocel alone in patients with epistaxis.

Conflict of interest : none

REFERENCES

- Pollice P and Yoder M. Epistaxis: a retrospective review of hospitalized patients. *Otolaryngology—Head and Neck Surgery*. 1997;117(1):49–53.
- Kucik CJ and Clenney T. Management of epistaxis. *American Family Physician*. 2005;71(2):305–11.
- Viehweg TL, Roberson JB and Hudson JW. Epistaxis: diagnosis and treatment. *Journal of Oral and Maxillofacial Surgery*. 2005;64(3):511–8.
- McGarry GW. *Epistaxis in Scott-Brown's Otolaryngology Head & Neck Surgery, Chapter 126*. 7th. Vol. 2. London, UK: Hodder-Arnold; 2009. pp. 1596–608.
- Corbridge RJ, Djazaeri B, Hellier WPL, et al. A prospective randomized controlled trial comparing the use of Merocel nasal tampons and BIPP in the control of acute epistaxis. *Clinical Otolaryngology*. 1995;20(4):305–7.
- Gabay M. Absorbable hemostatic agents. *American Journal of Health-System Pharmacy*. 2006;63(13):1244–53.
- Franz VK, Clarke HT and Lattes R. Hemostasis with absorbable gauze (oxidized cellulose) *Annals of Surgery*. 1944;120(2):181–98.
- O'Reilly BJ, C Simpson D and Dharmeratnam R. Recurrent epistaxis and nasal septa deviation in young adults. *Clinical Otolaryngology*. 1996;21:12–4.
- Shaheen O. Epistaxis. In: Bull T. R., MacKay I. R., editors. *Scott Brown's Otolaryngology: Rhinology*. 5th. Vol. 4. London, UK: Butterworth-Heinemann. 1987;277–8.
- Gifford TO and Orlandi R.R. Epistaxis *Otolaryngologic Clinics of North America*. 2008;41(3):525–36.
- Hallberg OE. Severe nosebleed and its treatment. *JAMA: The Journal of the American Medical Association*. 1952;148(5):355–60.
- Alvi A and Joyner-Triplett N. Acute epistaxis. *Postgraduate Medicine*. 1996;99(5):83–96.
- Watkinson JC. Epistaxis. In: Scott- Brown WR, Kerr AG, editors. *Scott Brown's Otolaryngology: Rhinology*. 6th. Vol. 4. Oxford, UK: Butterworth-Heinemann; 1997; 1–19.
- Oioriz Marin JA, Prim Espada MP and De Diego Sastre JJ. History of epistaxis since the ancient times to the first half of the XXth century. *An Otorrinolaringol Ibero Am*. 2007;34(5):505–15.
- Stangerup SE, Dommerby H, Lau T. Hot- water irrigation as a treatment of posterior epistaxis. *Rhinology*. 1996; 34:18–20.
- Varshney S, Saxena RK. Epistaxis: a retrospective clinical study. *Indian Journal of Otolaryngology and Head and Neck Surgery*. 2005;57(2):125–9.
- Shinkwin CA, Beasley N, Simo R, et al. Evaluation of Surgicel Nu-Knit, Merocel and Vasolene gauze nasal packs: a randomized trial. *Rhinology*. 1996;34:41–4.
- Mathiasen RA and Cruz RM. Prospective, randomized, controlled clinical trial of a novel matrix hemostatic sealant in children undergoing adenoidectomy. *Otolaryngology-Head and Neck Surgery*. 2004;131(5):601–5.
- Johnson and Johnson. *Prescribing Information, Surgicel Original, Surgicel Nu- Knit and Surgicel Fibrillar Absorbable Hemostats (Oxidized Regenerated Cellulose)* Somerville, MA, USA: Johnson and Johnson Wound Management, a Division of Ethicon, Inc.; 2007.
- Hashmi SM, Gopaul SR, Prinsley PR, et al. Swallowed nasal pack: a rare but serious complication of the management of epistaxis. *The Journal of Laryngology & Otology*. 2004;118(5):372–3.
- Alshehri WM, Ahmed MW, Albathi A., et al. Merocel surgical pack technique to manage diffuse epistaxis in patients with comorbidities. *International Journal of otolaryngology*. 2020;102(7):498-501.
- Pringle MB, Beasley P and Brightwell AP. The use of Merocel nasal packs in the treatment of epistaxis. *The Journal of Laryngology & Otology*. 1996;110(6):543–6.
- Corbridge RJ, Djazaeri B, Hellier WPL, et al. A prospective randomized controlled trial comparing the use of Merocel nasal tampons and BIPP in the control of acute epistaxis. *Clinical Otolaryngology*. 1995;20(4):305–7.
- Van Wyk FC, Massey S, Worley G, et al. Do all epistaxis patients with a nasal pack need admission? A retrospective study of 116 patients managed in accident and emergency according to a peer reviewed protocol. *The Journal of Laryngology & Otology*. 2007;121(3):222–7.