



6-1-2022

## EVALUATION OF LIGATION OF THE INTERSPHINCTERIC FISTULAS TRACT (LIFT) TECHNIQUE IN TRANSSPHINCTERIC PERIANAL FISTULA

MARWAN BORHAM

surgery department faculty of medicine azhar university cairo, marwanborham74@gmail.com

Follow this and additional works at: <https://aimj.researchcommons.org/journal>



Part of the [Medical Sciences Commons](#), [Obstetrics and Gynecology Commons](#), and the [Surgery Commons](#)

### How to Cite This Article

BORHAM, MARWAN (2022) "EVALUATION OF LIGATION OF THE INTERSPHINCTERIC FISTULAS TRACT (LIFT) TECHNIQUE IN TRANSSPHINCTERIC PERIANAL FISTULA," *Al-Azhar International Medical Journal*: Vol. 3: Iss. 6, Article 22.

DOI: <https://doi.org/10.21608/aimj.2022.138777.1949>

This Original Article is brought to you for free and open access by Al-Azhar International Medical Journal. It has been accepted for inclusion in Al-Azhar International Medical Journal by an authorized editor of Al-Azhar International Medical Journal. For more information, please contact [dryasserhelmy@gmail.com](mailto:dryasserhelmy@gmail.com).

# Evaluation Of Ligation Of the Intersphincteric Fistulas Tract (LIFT) Technique In Transsphincteric Perianal Fistula

Marwan Mansour Borham <sup>1</sup>\*MD; Mohamed Elsaed Abo Elkher <sup>2</sup>MD.

## \*Corresponding Author:

Marwan Mansour Borham  
marwanborham74@gmail.com

Received for publication May 22, 2022; Accepted June 24, 2022;  
Published online June 24, 2022.

**Copyright** The Authors published by Al-Azhar University, Faculty of Medicine, Cairo, Egypt. Users have the right to read, download, copy, distribute, print, search, or link to the full texts of articles under the following conditions: Creative Commons Attribution-Share Alike 4.0 International Public License (CC BY-SA 4.0).

doi: 10.21608/aimj.2022.138777.1949

<sup>1</sup>General Surgery Department, Faculty of Medicine, Al-Azhar University, Cairo, Egypt.

<sup>2</sup>General Surgery Department, Faculty of Medicine, Al-Azhar University, Damietta, Egypt.

## ABSTRACT

**Background:** Since 2007, ligation of the inter-sphincteric fistula tract (LIFT) has been performed successfully and enthusiastically to treat anal fistulas. However, whether a surgical treatment is better for trans-sphincteric fistula is still debated. The goal of this study is to evaluate the LIFT technique in treating trans-sphincteric perianal fistula.

**Aim of The Work:** To evaluate the result of using LIFT technique in patients with inter-sphincter anal fistulas.

**Patients and Methods:** Our research conducted on of 40 cases with trans-sphincteric perianal fistula who presented to our tertiary care center at Al-Azhar University hospital in Damietta, Egypt, between December 2019 and December 2021.

**Results:** The study was done on 40 patients, with a 24-week median follow-up. At the end of the follow-up, 29 patients (72.5 %) had healed completely and did not require any further surgical treatment. There were eight problems (27.5 percent). There were two failures and six recurrences between 3 and 6 months after the surgery. There was no de novo incontinence recorded. The LIFT technique was more suitable in patients who did not have prior fistulas and those with shorter tracts,  $P = 0.005$  and  $P = 0.003$ , respectively.

**Conclusion:** A number of surgical methods have been documented for the treatment of perianal fistula. The most important factor in determining optimal therapy and minimizing the risk of recurrence or incontinence is choosing the best surgical approach among the available alternatives. The LIFT method is simple and easy to grasp. According to the authors, LIFT is an appropriate treatment choice for uncomplicated short trans-sphincteric perianal fistulas.

**Keywords:** ligation of the inter-sphincteric fistula tract; LIFT technique; inter-sphincteric fistula.

**Disclosure:** The authors have no financial interest to declare in relation to the content of this article. The Article Processing Charge was paid for by the authors.

**Authorship:** All authors have a substantial contribution to the article.

## INTRODUCTION

A perianal fistula is a tubular structure lined with granulation tissue that connects a main entry within the anal canal or rectum to a secondary opening in the perianal skin.<sup>1</sup> For many years, probing the fistula tract has been the procedure of choice for identifying the anatomy of fistulas. The most commonly used treatment is to open a fistulous tract (fistulotomy). However, if a considerable portion of the sphincter muscle is damaged, this treatment may become difficult.<sup>2</sup>

The LIFT technique is a novel surgical method for treating trans-sphincteric fistula that was first described by Rojanasakul et al.<sup>3</sup> in 2007. It has been shown to be effective in the short term with no incontinence. It is done by identifying the internal opening; making incision at the inter-sphincteric groove; dissecting the inter-sphincteric space; identifying the inter-sphincteric fistula tract; securing ligation and excision of the inter-sphincteric tract; confirming the removal of the correct fistulous tract;

opening and curing the external opening; and finally closing the inter-sphincteric wound.<sup>3</sup>

Despite its initial feasibility and high success rates, multiple later investigations have indicated inferior healing rates and greater recurrences due to non-standardized operating practices and patients' inclusion criteria.

The primary goal of this research is to evaluate healing, failure, recurrence, incontinence, and other key concerns associated with the LIFT technique in trans-sphincteric.

## PATIENTS AND METHODS

Our study included 40 patients of trans-sphincteric anal fistula who came to our tertiary care center between December 2019 and December 2021.

Anal fistula with trans-sphincteric track is required for inclusion. All cases were clinically diagnosed and confirmed by MRI and CT. Patients having anal fistula owing to a particular illness are excluded. There are three forms of anal fistulas: low inter-sphincteric, supra-sphincteric, and extra-sphincteric.

**Ethical approval:** All patients who participated in this trial provided informed consent. This study was authorized by the ethical committee of Al-Azhar University's college of medicine in Damietta, Egypt.

**Preoperative assessment:** full medical history including age, gender, BMI, diabetes, and a history of previous anal surgeries and previous fistula surgeries. Secondly: digital rectal examination is performed to detect the position of the external opening, fistulous tract, internal opening, and anal tone. MRI and CT scans to confirm the presence of anal fistulas and define their anatomy. The following regions were thoroughly checked intraoperatively: external opening position, internal opening location, tract length, presence of external piles at the incision site, and anal muscle thickness.

**Operative procedures:** All patients had the LIFT surgery.<sup>4</sup> The following procedures were carried out in the lithotomy position under spinal or general anesthesia: The internal hole was discovered after sensitive probing of the fistula tract. If probing failed, a hydrogen peroxide solution was injected through the exterior opening into the fistula tract. The inter-sphincteric plane was reached using a 2-3 cm incision at the medial end of the fistulous tract. By dissection with scissors and electrocautery while the probe was still in place, the inter-sphincteric space was discovered and penetrated between the internal and external sphincters. Rather than cutting, we found the inter-sphincteric tract and hooked it with a right-angled clamp before transfixing the patient. Rather than cutting, we located the inter-sphincteric tract and hooked it with a right-angled clamp; we then transfixed the inter-sphincteric fistula tract with polyglactin (Vicryl) 3/0 on both sides, one near the internal opening and the other near the external

sphincter defect. The tract was split between the places of ligation. From the external aperture, the distal half of the tract was fully curetted. Vicryl 3/0 simple interrupted single layer was used to approximate the inter-sphincteric incision wound. The tract's tight suturing was verified by introducing a probe through the exterior orifice or injecting hydrogen peroxide.

**Postoperative follow-up:** All patients were released after 24 hours unless there was a complication. All patients were given ciprofloxacin and metronidazole orally for 7 days. For wound healing and postoperative complications, including recurrence, weekly visits for the first month, then every two months for the remaining six months. A successful outcome was defined as the surgical wound and external opening fully healing. Persistence of fistula was defined as the presence of persistent discharge with no complete wound healing of either the external opening or the inter-sphincteric wound (procedure failure). Recurrence was defined as the emergence of symptoms following complete healing of the exterior opening and the inter-sphincteric wound.

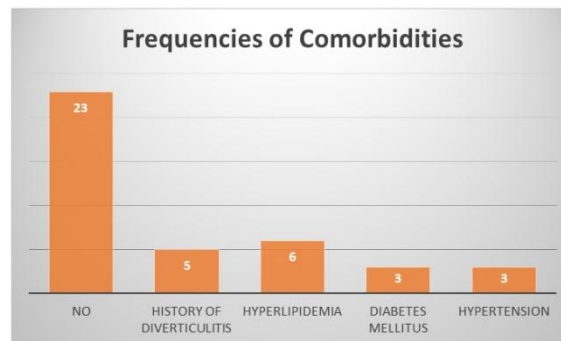
**Statistical analysis:** Mean values were used for quantitative variables, while absolute and relative frequencies were used for qualitative data (SD). To compare proportions between groups, Fisher's exact test was performed, whereas Student's t-test was utilized to compare mean values. The p values displayed are all two-tailed. The statistical significance limit of p 0.05 was set. The Jamovi statistical tool was used to conduct this research (version 2.0.0).<sup>5</sup>

## RESULTS

Table 1 summarizes the demographics and clinical characteristics of the individuals enrolled. LIFT procedures were performed on 40 patients. The patients are composed of 32 men (80%) and 8 women (20%), with a median age of 44 (range: 25–64) and a median symptom duration of 20 months (range: 2–72 months). In five of the patients (12.5 percent), previous definitive fistula repairs had failed. A fistula tract's median length was 4 cm (range: 3–10 cm), with 62.5 percent of fistula tracts being longer than 3 cm. Six patients had hyperlipidemia, five had diverticulitis, three had diabetes, and three had high blood pressure (Table 1)

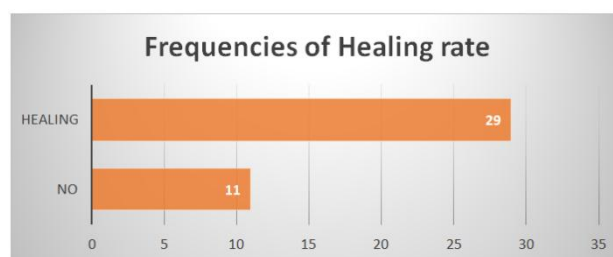
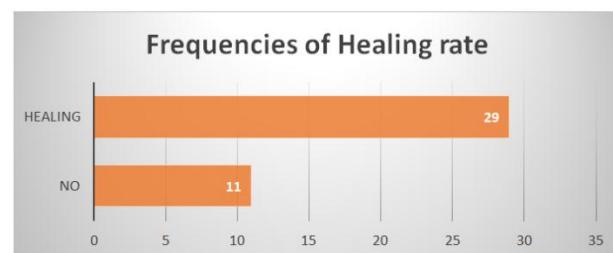
Total number of patients		40
Sex, n (%)		
Female		8 (20.0%)
Male		32 (80.0%)
Median age, y (range)		44 (25 – 64)
Median symptom duration, mo (range)		20 (2-72)
Median fistula tract length, cm (range)		4 (3-10)
Fistula tract length ≤3 cm, %		15 (37.5%)
Fistula tract length >3 cm, %		25 (62.5%)
Comorbidities		
History of diverticulitis		5 (12.5%)
Diabetes Meletus		3 (7.5%)
Hyperlipidemia		6 (15%)
Hypertension		3 (7.5%)
Recurrent fistula		
Negative		35 (87.5%)
Positive		5 (12.5%)

<b>Piles at Fistula</b>	
<b>Present</b>	8 (20%)
<b>Absent</b>	32 (80%)

**Table 1:** Demographics and clinical characteristics of the included patients.**Fig. 1:** Frequencies of Comorbidities.

Following the initial LIFT operation, 29 (72.5%) of the 40 patients recovered without the need for additional surgeries. The average follow-up time was 24 weeks (range: 3-46 weeks). Age, gender, comorbidities, and sickness duration had no statistically significant influence on healing. However, the median fistula tract length in the repaired group is shorter than in the failed group (3cm vs 7cm,  $p=0.014$ ). When 3 cm was selected as an artificial cutoff limit, fistula tracts shorter than 3 cm showed significantly better primary healing (56 percent versus 44 percent,  $p = 0.003$ ). Furthermore, there was no subjective incontinence or intraoperative issue. (Tables 2 and 3).

<b>Primary healing, %</b>	<b>29 (72.5 %)</b>
<b>Median follow-up, weeks (range)</b>	<b>24 (3 – 46.)</b>
<b>Incontinence, %</b>	<b>0 (0%)</b>

**Table 2:** Overall results (total number=40).**Fig. 2:** Frequency of Healing rate among the studied group.**Fig. 3:** Frequency of complications among the studied group.

<b>Total number of patients</b>	<b>Healing rate, (%)</b>	<b>P-value</b>
<b>Fistula tract length <math>\leq 3</math> cm, %</b>	13/15 (86%)	0.003
<b>Fistula tract length <math>&gt; 3</math> cm, %</b>	14/25 (65%)	

- Fisher's exact test is significant ( $p < .05$ ).

**Table 3:** Effect of fistula length on the healing rate.

There was no statistically significant difference between people with surgical difficulties and those without postoperative issues in terms of age, median symptom duration, and other comorbidities. However, there was a significant difference between the two groups in terms of recurrent fistula and piles with fistula, with P-values of 0.005 and 0.001, respectively. (Table 2 and Table 4).

Patients' characteristics	Post-operative complications		P-value
	Not Complicated	Complicated	
	29 (72.5%)	11 (27.5%)	
<b>Sex</b>			
Female	8 (27.5%)	0 (0%)	0.051*
Male	21 (72.5%)	11 (100%)	
<b>Age (Median <math>\pm</math>SD)</b>			
	44.90 $\pm$ 11.49	43.45 $\pm$ 12.71	0.732•
<b>Median symptom duration (Median <math>\pm</math>SD)</b>	24.41 $\pm$ 20.36	22.91 $\pm$ 20.36	0.817•
<b>Median fistula tract length (Median <math>\pm</math>SD)</b>	11.49 $\pm$ 2.17	3.82 $\pm$ 2.75	0.111•
<b>Fistula tract length</b>			
$\leq 3$ cm	7 (24.13%)	7 (63.63%)	0.019*
$> 3$ cm	22 (75.8%)	4 (36.36%)	
<b>Comorbidities</b>			
History of diverticulitis	2 (6.9%)	3 (27.27%)	0.402*
Diabetes Meletus	2 (6.9%)	2 (18.18%)	
Hyperlipidemia	4(13.8%)	1 (9%)	
Hypertension	2 (6.9%)	1 (9%)	
<b>Recurrent fistula</b>			
Negative	28 (96.5%)	7 (63.63%)	0.005*
Positive	1 (3.4%)	4 (36.36%)	
<b>Piles at fistula</b>			
Present	0 (0%)	8 (72.5%)	<0.001
Absent	29 (100%)	3 (27.5%)	

:\*Fisher's exact test; •: Independent t-test

**Table 4:** Relation of postoperative complications with demographic and clinical characteristics of the studied patients

## DISCUSSION

A quarter of all fistulas are trans-sphincteric, with the track travelling from the inter-sphincteric space to the ischiorectal space via the external anal sphincter. Trans-sphincteric fistulas that span the top two-thirds of the external anal sphincter (high trans-sphincteric fistulas) are distinguished from trans-sphincteric fistulas that traverse the bottom third of the external anal sphincter (low trans-sphincteric fistulas).<sup>6</sup> Both forms need distinct treatment, with the low type necessitating fistulectomy.

Rojanasakul and colleagues published the first paper outlining the LIFT method in 2007, reporting a good healing rate (nearly 94%) for trans-sphincteric fistulas with no complications. Since then, clinicians have used the LIFT technique.<sup>7</sup> The goal of this study is to assess the short-term outcome of the LIFT surgery in 40 patients with a trans-sphincteric anal fistula.

The study's main finding is that 72.5 percent of the 40 LIFT operations performed in our setting recovered fully following a median follow-up of about 24 weeks. The short-term follow-up may have contributed to this trial's extraordinary success rate. A two-year or longer follow-up should clarify this point.<sup>8</sup> A longer period of follow-up is required to get a better grasp of LIFT's long-term outcomes. According to prior research and our findings, a 12-month follow-up time after the first procedure is indicated to check that full healing has occurred.

In a comprehensive review of 13 studies involving 438 fistula patients, the overall success rate ranged from 40% to 94.4 percent, with a pooled success rate of 71%.<sup>9&10&11</sup> Other variations on the original LIFT approach have since been described. The present study's findings were consistent with those of Shanwani and colleagues (2010), who discovered that 17.7 percent of 45 patients had a recurrence of fistula between 3 and 8 months following a median follow-up of 9 months. 12 Although the current median follow-up duration is 5 to 9 months, certain studies have found that late recurrences can occur 7 to 8 months after surgery. As a result, based on short-term observations, the success rate may be overstated.<sup>13&14&15</sup>

Incontinence is the most prevalent side effect of perianal fistula surgery, and it is a major cause of dissatisfaction for most surgeons. Indeed, the majority of trials showed no substantial postoperative complications after LIFT surgery, proving the technique's safety.<sup>12</sup> This was clear in our study since none of the patients reported any changes in their continence. We determined that the LIFT therapy is a sphincter-preserving technique with no loss of continence since it does not cause anal sphincter injury.

Murugesan et al.<sup>16</sup> conducted a narrative synthesis of the data from the 22 studies and discovered that no incontinence or change in continence was seen in 18 of the 22 studies. Similarly, in our prospective study, we identified no patients with incontinence after

LIFT surgery. The LIFT approach, according to the study, has the advantages of protecting the anal sphincters, inflicting less tissue damage, and resulting in a rapid recovery period with no additional costs. If the procedure fails, it is simple to redo. Till now, however, only one prospective randomized trial has been carried out, and the majority of the data is based on small case series with poor follow-up and no objective assessment of incontinence.

The average time for wound healing in our study was 4 weeks. This was similar to the findings of Sirikurnpiboon and colleagues (2013).<sup>17</sup> The quick wound healing duration of the LIFT method may be explained by the presence of a small wound in the inter-sphincteric groove, which is less prone to contamination.

We observed lower success rates in cases where there was a previous history of fistula surgery. This is consistent with the findings of Abcarian et al. (2012)<sup>18</sup>, who discovered that patients who had no previous procedures (90% healing rate) healed quicker than those who had one or more previous surgeries (70% healing rate) prior to receiving LIFT. They believe the explanation is multifaceted, with the complexity of the original fistula, the modification of the operating table, and DE vascularization of native tissues with any subsequent surgical intervention all leading to reduced healing rates. They conclude that LIFT is a great initial sphincter-sparing surgery for perianal fistula in adequately chosen individuals. Lehmann and Graf evaluated the efficacy of LIFT for reoccurring anal fistulas (2013).<sup>19</sup>

In terms of the association between fistula tract length and failure to heal after LIFT surgery, Liu and colleagues (2013)<sup>20</sup> observed that longer fistula tracts had a lower primary healing rate. They believe this is because longer tracts are more likely to include persistent epithelial tissue, inflammation, and sepsis, all of which make healing more difficult. As a consequence, they concluded that thorough curettage, cauterization, and peroxide irrigation of the external tract during the initial operation, as well as widening the external incision to aid drainage, might help to prevent persistent sepsis and accelerate recovery. This matched the findings of our investigation, which revealed that the recurrence rate rose dramatically as the distance between the anal margin and the external orifice increased.

**Limitations:** There are significant drawbacks to this study, including its nonrandomized design, limited sample size, and short follow-up time. Follow-up was challenging, particularly for patients who had recovered, because individuals prefer to miss appointments when they are feeling well. Due to the small sample size, multivariate analysis was not possible. Larger prospective, randomized studies may be necessary to assess the real comparative and advantage of the LIFT procedure.

### CONCLUSION

Based on the evidence so far, the LIFT procedure appears to be a safe and effective surgical approach with low fecal incontinence complications. It is particularly effective in treating trans-sphincteric,

minor fistulas and people who have never had surgery previously. Randomized controlled trials with a longer follow-up time are still required before the LIFT approach may be recommended above other surgical treatments for anal fistulas.

### REFERENCES

1. Oxforddictionaries.com. Fistula – definition of fistula in English from the Oxford dictionary. 2015; Available at: <http://www.oxforddictionaries.com/definition/english/fistula>.
2. Mangual RN, Tudu DN, Pattnaik SP, Mohanty SS, Prusty KP. The sphincter preserving perianal fistulectomy: a better alternative. *Ind J Surg*. 2004;66:31–5.
3. Rojanasakul A, Pattanaarun J, Sahakitrungruang C, Tantiphlachiva K. Total anal sphincter saving technique for fistula-in-ano; the ligation of intersphincteric fistula tract. *J Med Assoc Thai*. 2007;90:581–6.
4. Limura E. Modern management of anal fistula. *World J Gastroenterol*. 2015;21(1):12. doi:10.3748/wjg.v21.i1.12.
5. The jamovi project (2020). jamovi. (Version 1.2) [Computer Software]. Retrieved from <https://www.jamovi.org>.
6. Phillips R, Lunniss P. Anal fistula evaluation and management. – a companion to specialist surgical practice. *Colorectal Surgery E-Book*. 2013;22(1):212–6.
7. Rojanasakul A, Pattanaarun J, Sahakitrungruang C, Tantiphlachi- va K. Total anal sphincter saving technique for fistula-in-ano; the ligation of intersphincteric fistula tract. *J Med Assoc Thai*. 2007; 90:581–6.
8. Lehmann J, Graf W. Efficacy of LIFT for recurrent anal fistula. *Colorectal Disease*. 2013;15(5):592–5. doi:10.1111/codi.12104.
9. Wallin UG, Mellgren AF, Madoff RD, Goldberg SM. Does ligation of the intersphincteric fistula tract raise the bar in fistula surgery? *Dis Colon Rectum*. 2012;55:1173–8.
10. Rojanasakul A, Pattanaarun J, Sahakitrungruang C, Tantiphlachi- va K. Total anal sphincter saving technique for fistula-in-ano; the ligation of intersphincteric fistula tract. *J Med Assoc Thai*. 2007; 90:581–6.
11. Hong KD, Kang S, Kalaskar S, Wexner SD. Ligation of inter- sphincteric fistula tract (LIFT) to treat anal fistula: systematic review and meta-analysis. *Tech Coloprocto.l* 2014;18:685–91.
12. Lehmann J, Graf W. Efficacy of LIFT for recurrent anal fistula. *Colorectal Disease*. 2013;15(5):592–5. doi:10.1111/codi.12104.
13. Bleier J, Moloo H, Goldberg S. Ligation of the Intersphincteric Fistula Tract: An Effective New Technique for Complex Fistulas. *Diseases of the*



- Colon & Rectum*. 2010;53(1):43-6. doi:10.1007/dcr.0b013e3181bb869f.
14. Aboulain A, Kaji A, Kumar R. Early Result of Ligation of the Intersphincteric Fistula Tract for Fistula-in-Ano. *Diseases of the Colon & Rectum*. 2011;54(3):289-92. doi:10.1007/dcr.0b013e318203495d.
  15. Aboulain A, Kaji A, Kumar R. Early Result of Ligation of the Intersphincteric Fistula Tract for Fistula-in-Ano. *Diseases of the Colon & Rectum*. 2011;54(3):289-92. doi:10.1007/dcr.0b013e318203495d.
  16. Murugesan J, Mor I, Fulham S, Hitos K. Systematic review of efficacy of LIFT procedure in cryptoglandular fistula-in-ano. *J Colo- proctol*. 2014;34:109-19.
  17. Sirikurnpiboon S. Ligation of intersphincteric fistula tract and its modification: Results from treatment of complex fistula. *World J Gastrointest Surg*. 2013;5(4):123. doi:10.4240/wjgs.v5.i4.123.
  18. Abcarian A, Estrada J, Park J et al. Ligation of Intersphincteric Fistula Tract. *Diseases of the Colon & Rectum*. 2012;55(7):778-82. doi:10.1097/dcr.0b013e318255ae8a.
  19. Lehmann J, Graf W. Efficacy of LIFT for recurrent anal fistula. *Colorectal Disease*. 2013;15(5):592-5. doi:10.1111/codi.12104.
  20. Liu W, Aboulain A, Kaji A, Kumar R. Long-term Results of Ligation of Intersphincteric Fistula Tract (LIFT) for Fistula-in-Ano. *Diseases of the Colon & Rectum*. 2013;56(3):343-7. doi:10.1097/dcr.0b013e318278164c.