



6-1-2022

Intravitreal Diclofenac compared to Intravitreal Ranibizumab in Treatment of Diabetic Macular Edema

Mohamed Gamal

Ophthalmology, dhhbiris@gmail.com

Al-Araby Nassar

Department of Ophthalmology, Faculty of Medicine, Al-Azhar University, alarabynassar@yahoo.com

abdelghany abdelghany

Department of Ophthalmology, Faculty of Medicine, Al-Azhar University,
abdelghanyahmed936@gmail.com

Follow this and additional works at: <https://aimj.researchcommons.org/journal>



Part of the [Medical Sciences Commons](#), [Obstetrics and Gynecology Commons](#), and the [Surgery Commons](#)

How to Cite This Article

Gamal, Mohamed; Nassar, Al-Araby; and abdelghany, abdelghany (2022) "Intravitreal Diclofenac compared to Intravitreal Ranibizumab in Treatment of Diabetic Macular Edema," *Al-Azhar International Medical Journal*: Vol. 3: Iss. 6, Article 11.

DOI: <https://doi.org/10.21608/aimj.2022.111094.1723>

This Original Article is brought to you for free and open access by Al-Azhar International Medical Journal. It has been accepted for inclusion in Al-Azhar International Medical Journal by an authorized editor of Al-Azhar International Medical Journal. For more information, please contact dryasserhelmy@gmail.com.

Intravitreal Diclofenac compared to Intravitreal Ranibizumab in Treatment of Diabetic Macular Edema

Mohamed Mahmoud Gamal ¹*MSc; Al-Araby Abd Al-Ghany Nassar ¹MD;
Abd Al-Ghany Ibrahim Abd Al-Ghany ¹MD.

*Corresponding Author:

Mohamed Mahmoud Gamal
dhbiris@gmail.com

Received for publication December 15, 2021; Accepted June 24, 2022;
Published online June 24, 2022.

Copyright The Authors published by Al-Azhar University, Faculty of Medicine, Cairo, Egypt. Users have the right to read, download, copy, distribute, print, search, or link to the full texts of articles under the following conditions: Creative Commons Attribution-Share Alike 4.0 International Public License (CC BY-SA 4.0).

doi: 10.21608/aimj.2022.111094.1723

¹Ophthalmology Department, Faculty of Medicine, Al-Azhar University, Cairo, Egypt.

ABSTRACT

Background: there are many options in treatment of diabetic macular edema(DME). Intravitreal injection of anti vascular endothelial growth factor(Anti-VEGF) is standard treatment of DME. Ranibizumab is one of worldwide used. Intravitreal injection of non steroidal anti-inflammatory is one of new modalities in treatment .Diclofenac is promising material for DME.

Aim of The Work: To Compare between intravitreal injection of Diclofenac versus Ranibizumab in treatment of (DME).

Patients and Methods: Patients with DME were categorized into 2 groups , group 1 (40 eyes) managed with intravitreal injection of 0.5 mg/0.1mL Ranibizumab(IVR), group 2 (40 eyes) managed intravitreal injection of 0.5 mg /0.1 mL of Diclofenac(IVD). All patients' best-corrected visual acuity (BCVA), and Central macular thickness (CMT) and intra ocular pressure(IOP) followed up for three months.

Results: At the end of 3rd month, the BCVA improved significantly in both groups it was (0.3± 0.087) decimal in the IVD group and (0.26 ± 0.046) decimal in the IVR group, which was statistically significant (P-value <0.05) . CMT decreased to (257.12± 45.96) µm in the IVD group and (257.3± 48.79) µm in the IVR group. There was no statistically significant meaningful difference between the two groups by the end point (P-value >0.05). The IOP in the IVD group reduced to (14.85± 2.01)mmHg and in the IVR group increased to (15.22± 2.87) mmHg. There was no statistically significant difference between two groups (P-value = 0.5).

Conclusion: In DME, Diclofenac has a reasonable effect comparable to Ranibizumab on CMT and significant visual gain.

Keywords: Diclofenac; Diabetic macular edema; Ranibizumab; Intravitreal.

Disclosure: The authors have no financial interest to declare in relation to the content of this article. The Article Processing Charge was paid for by the authors.

Authorship: All authors have a substantial contribution to the article.

INTRODUCTION

DME is defined as retinal thickening within two disc diameters of the fovea . Because of retinal micro vasculopathy in blood retinal barrier, causing escaping of plasma components into the surrounding retinal tissue and macular edema developed.¹

The estimated percentage of incidence of DME for a 10-year period long about 13.9% of patients with type 2 diabetes non-insulin dependent diabetes mellitus (NIDDM) and 20.1% of patients with type 1 diabetes insulin –dependent diabetes mellitus (IDDM),¹

Visual loss in diabetic patients represents one of the majority vital reasons which develops at any time through out the disease due to DME, vitreous haemorrhage ,neovascular glaucoma, ischemic maculopathy ,hyphema and consecutive optic atrophy.²

There are many modalities for DME management . Newly intravitreal injection of anti- (VEGF) drugs has become well-known. Numerous trials have

investigated the value of bevacizumab and ranibizumab on DME .steroids another modalities has been used in intravitreal injections in DME. ⁽³⁾

Arachidonic acid that produced from cell membrane phospholipids, converted to prostaglandins (PGs) and thromboxanes by cyclooxygenase enzymes (COX1 and COX2) and to leukotrienes by 5-lipoxygenase enzymes.

Prostaglandins are potent for release of angiogenesis. Non steroidal anti-inflammatory drugs (NSAIDs) have a property of potent anti-inflammatory and COX suppressor .So, having antiangiogenic and antiproliferative effects .⁽⁵⁾

Corticosteroids has concurrently double pathways (COX and 5-lipoxygenase) that suppress inflammation, NSAIDs have minimal side effects compared to steroids like (IOP) and lens clauding in diabetics who are exposed to glucose fluctuations.⁶

So, in this study, we will compare the visual and anatomical results of IVD with those of IVR. This study aimed to investigate these intravitreal injections effect in patients with DME.

PATIENTS AND METHODS

This was a randomized interventional comparative study conducted on 80 eyes of 58 patients who presented with diffuse DME during the period from January 2020 to December 2020 in Zagazig ophthalmic hospital.

All patients underwent a complete ophthalmic examination, slit-lamp biomicroscopy, best-corrected visual acuity (decimal), IOP applanation fluorescein angiography and fundus photography. Measurement of central macular thickness using spectral-domain optical coherence tomography

After local ethical committee approval, all patients signed a separate informed approval for the use of intravitreal injection before entering the study.

Inclusion criteria:

All eyes with diffuse DME with non-tractional maculopathy, Central macular thickness $\geq 400\mu\text{m}$ with or without cystic changes, Diabetes mellitus type one or two and Best corrected visual acuity $\geq 6/60$

Exclusion criteria:

All eyes with diffuse DME in: Patients with previous ocular surgery, corneal opacities, Dense

cataract, Patients with macular ischemia, epiretinal membrane or vitreomacular traction. Or history of Glaucoma, ocular trauma, posterior segment complications vascular occlusions. Patients treated with diclofenac, Ranibizumab or Bevacizumab in past 6 months

follow up: On 1st day, 7th day after injection, On 1st, 2nd and 3rd month after injection. using : Slit lamp examination, Fundus examination and optical coherence tomography (OCT) MACULA

METHOD (Technique of Injection)

under complete aseptic conditions in the operating room with an operation microscope. Patients received either drug: 0.5 mg/0.1 mL Ranibizumab or 0.5 mg /0.1 mL of diclofenac

At the inferotemporal quadrant through pars plana approach, 4 mm posterior to the limbus intravitreal injections were done (Technique of Injection).

Injection is repeated every month for three successive months.

Statistics

Statistical analysis was done using (SPSS v16; SPSS, Inc, Chicago, IL). For comparison between groups, t-test was used for numerical variables and paired t-test was used for within-group comparison. A 95% confidence level was set to all tests.

RESULTS

The study included 80 eyes of 58 patients (22 patients both eyes, 36 one eye) with mean age (52.81 ± 3.7) years (range 45-58 years). Thirty six were men and twenty two were women. Duration of diabetes range from (8-13 years). see Table 1.

BCVA

Before intervention, with the IVD group the BCVA was (0.11 ± 0.027) decimal and in the IVR group was (0.12 ± 0.028) decimal and there was no statistically significant difference between both groups (P-value > 0.05). At the end of 3rd month, vision is improved significantly in both groups it was (0.3 ± 0.087) decimal in the IVD group and (0.26 ± 0.046) decimal in the IVR group, which was statistically significant (P-value < 0.05) (Table 2)

Macular Thickness

The mean baseline CMT in the IVD group was (484.67 ± 75) μm and in the IVR group was (495 ± 83) μm . There was no significant difference between the two groups (P-value = 0.56). After 1st month, the CMT decreased to (378.85 ± 43.75) μm in the IVD group and (399.37 ± 66.25) μm in the IVR group. After 2nd month, the CMT diminished to (313.92 ± 40.27) μm in the IVD group and (325.82 ± 59.59) μm in the IVR group. After 3rd month, CMT decreased to (257.12 ± 45.96) μm in the IVD group and (257.3 ± 48.79) μm in the IVR group. There was no statistically significant meaningful difference between the two groups (p-value = 0.9). (Table 2).

IOP

The IOP measured at pre injection and after injection for all patients. Before injection the IOP in the IVD arm was (15.12 ± 3.14) mmHg and in the IVR group was (14.95 ± 2.11) mmHg and there was no statistically significant difference between two groups (P-value = 0.7). One week after injection the IOP in the IVD group reduced to (14.85 ± 2.01) mmHg and in the IVR group increased to (15.22 ± 2.87) mmHg. So, there was no statistically significant difference between two groups (P-value = 0.5). Table 2, Table 3

Age(years)	58 - 45(52.81 \pm 3.7)	
Sex		
Male	36	
Female	22	
Type of diabetes		
IDDM	(32.5) %	26
NIDDM	(67.5)%	54

Table 1: baseline Data of Patients Data in table are presented as mean \pm SD or NO

Variable	Intravitreal Diclofenac (n=40)	Intravitreal Ranibizumab (n=40)	P value
Central macular thickness Before injection	484.67±75	495±83	0.565
best-corrected visual acuity (Decimal) Before injection	0.11 ±0.027	0.12 ±0.028	0.63
intra ocular pressure Before injection	15.12±3.14	14.95±2.11	0.77
best-corrected visual acuity (Decimal)	0.11 ±0.027	0.12 ±0.028	0.63
best-corrected visual acuity at 1 st month	0.17±0.041	0.17±0.05	0.88
best-corrected visual acuity at 2 nd month	0.24±0.046	0.23±0.04	0.34
best-corrected visual acuity at 3 rd month	0.3±0.087	0.26 ±0.046	0.04
Central macular thickness	484.67±75	495±83	0.565
Central macular thickness at 1 st month	378.85±43.75	399.37±66.25	0.10
Central macular thickness at 2 nd month	313.92±40.27	325.82±59.59	0.299
Central macular thickness at 3 rd month	257.12±45.96	257.3±48.79	0.987

Table 2: Comparison of Visual Acuity , Macular thickness and IOP variables between the two groups before intervention. Comparison of Visual Acuity Central and Macular Thickness in Follow-up Visits between the Two Groups

Study group	(pre injection)	Post injection	P value
Intravitreal Diclofenac	15.12±3.14	14.85±2.01	0.770
Intravitreal Ranibizumab	14.95±2.11	15.22±2.87	0.502

Table 3: Comparison of (IOP) between before and after complete intravitreal injections in both Group

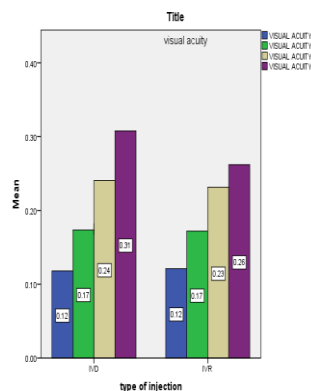


Fig 1: Visual acuity Comparison in visits of follow-up between the both groups

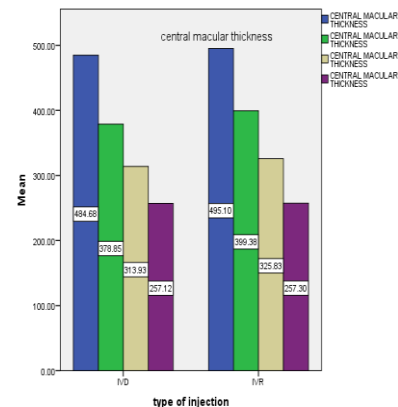


Fig 2: CMT Comparison in visits of follow-up between the both groups

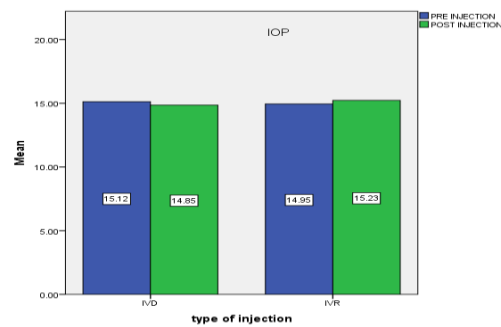


Fig. 3: IOP Comparison before and after injections in both group

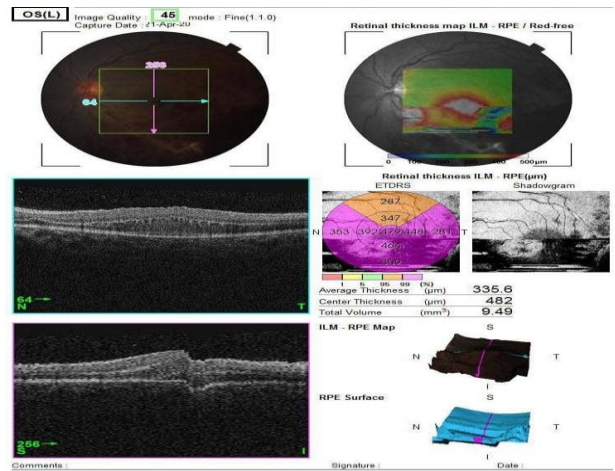


Fig. 4: IVR CASE :OCT pre injection

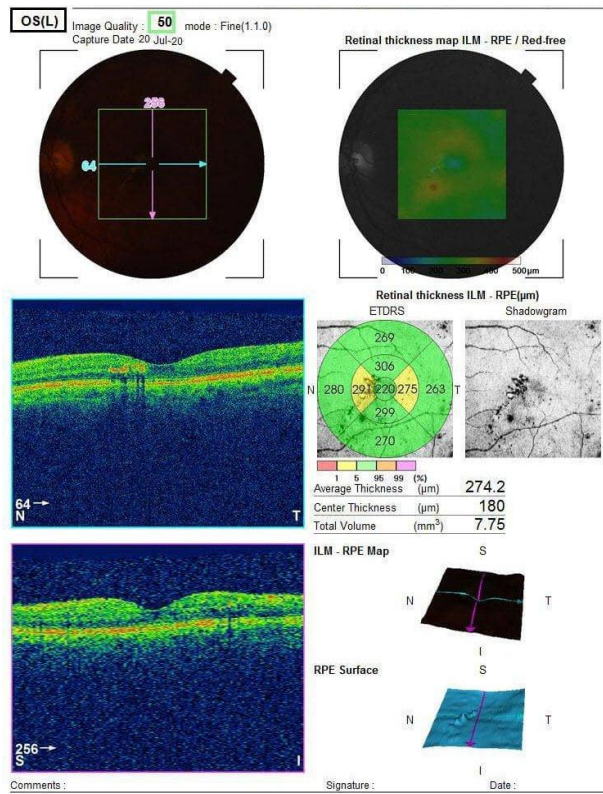


Fig. 5: IVR CASE :OCT post injection after 3rd injection

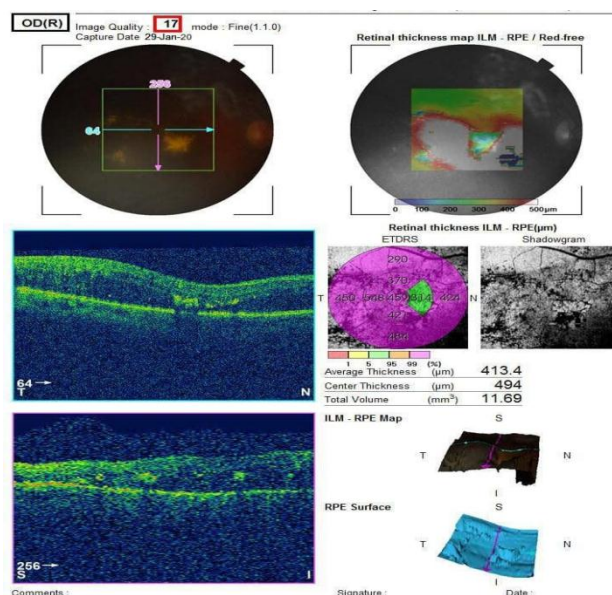


Fig.6: IVD CASE :OCT pre injection

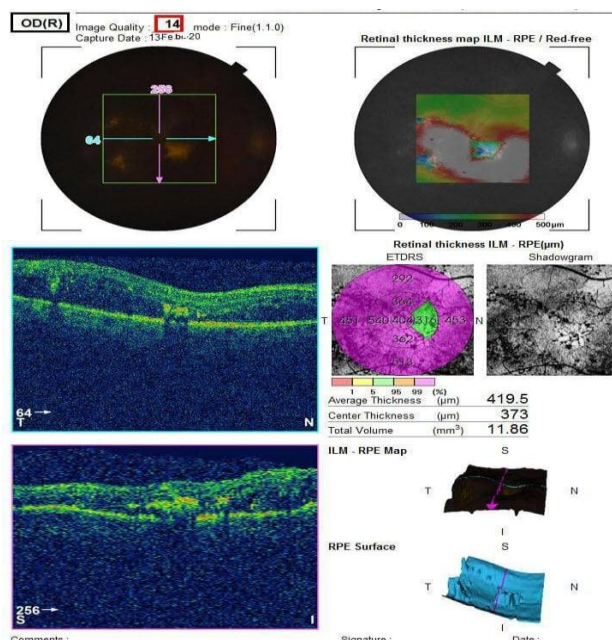


Fig. 7: IVD CASE :OCT post injection after 3rd injection

DISCUSSION

DME represents a vision -threatening state .

The prevalence of DME in the diabetic population about 10%, but the prevalence is increased in eyes with severe retinal insult . So, currently available treatment options are argon laser photocoagulation (ALP), topical NSAIDs, intravitreal medical treatment (either vascular endothelial growth factor inhibitors or corticosteroids), and vitrectomy . Although ALP presented as the main line of treatment for many years with potential complications, alternative therapies has been replaced. ³

Studies with steroids suggested that: steroids are superior to laser, steroids could reduce capillary leakage , thus decreasing DME the high incidence of complications especially cataract and increased IOP limiting its use. ⁶

Anti-VEGF agents block VEGF receptors activity , preventing leakage of vessel, thus lowering DME. The most widely used drugs include Bevacizumab ,Ranibuzimab and Aflibercept . ⁷

Diclofenac, an NSAID, works by inhibition of COX and lipoyxygenase enzymes . Although diclofenac used in the treatment of other

conditions, intravitreal delivery is a promising alternative.⁸

Numerous forms of NSAID have been trailed before for treating DME. For instance, nepafenac 0.1% was used topically in DME. Bromofenac used in managing CME after cataract extraction in diabetics.⁵

Hariprasad et al (2007), Callanan et al (2008) and Singh et al (2012) reported vision improvement and CMT reduction.^{9,10,11}

Regarding CMT the present clinical trial revealed that there was significant improvement in CMT by the end of 3rd month in both groups ($p=0.9$) and insignificant difference between both groups. These data were confirmed by El bendary et al (2011) compared IVD versus intravitreal triamcinolone acetate (IVTA) in DME for 3 months. Both groups showed significant reduction in CMT IVTA ($p=0.02$) and IVD ($p=0.01$) with insignificant difference between both groups ($p=0.03$).⁴ Same results seen by Faghihi et al (2007) compared IVD versus bevacizumab for 6 months with $p(=0.533)$ and insignificant difference between them. By the end of 6th month CMT improved $p(=0.06)$ with significant reduction in CMT.¹²

Moreover, Seth et al (2016) revealed in clinical trial for 3 months with branch retinal vein occlusion using IVD that CMT reduction at 3rd month $p(0.001)$.¹³ Hegazy et al (2015) showed in their clinical trial IVTA versus IVD for 3 months and revealed that central macular thickness reduction in both groups with insignificant difference between them.¹⁴ Wang et al (2012) revealed in clinical trial compared IVR versus IVR with laser for 12 months, decrease in CMT $p(0.01)$ no significant difference between both groups.¹⁵ Schmidt-Erfurth et al (2014) revealed in clinical trial done for 12 months compared IVR versus IVR with laser versus laser alone reduction in CMT. These similar to previous studies Reveal, Restore, RESOLVE and READ-2.¹⁶

On the other hand, Soheilian et al (2010) revealed in clinical trial performed with DME for 2 months used IVD and reported no CMT improvement.⁸

Regarding visual acuity, the present trial revealed that there was visual acuity improvement by the end of 3rd month for IVD rather than IVR. (P -value <0.05). These results confirmed by Soheilian et al (2010) revealed in clinical trial with DME for 2 months used IVD and reported there was meaningful difference between two groups in Visual enhancement (P -value <0.05) $p(0.019)$.⁸ Seth et al (2016) used IVD in branch retinal vein occlusion (BRVO) revealed visual acuity improved by 3rd month $p(=0.002)$.¹³ Faghihi et al (2007) Improvement in IVD and in Bevacizumab $p(>0.05)$ with insignificant difference between both groups without any side effects.¹²

Hegazy et al (2015) revealed no significant difference between IVD and IVTA groups in mean visual acuity ($p=0.05$).¹⁴

Schmidt-Erfurth et al (2014) concluded that IVR improved visual acuity. These similar to previous

studies Rise/ Ride, Reveal, Restore, Resolve and READ-2.¹⁶

Wang et al (2012) revealed IVR Improved visual acuity $p(=0.001)$. These similar to Rise/ Ride, Reveal, Restore.¹⁵ On the other hand, El bendary et al (2011) revealed Visual enhancement in IVTA group only $p(=0.005)$ with statistical insignificant difference between IVD and IVTA groups.⁴

Regarding IOP, the present clinical trial revealed that there was reduction in IOP in IVD group and increase in IVR group but this increase was not significant (P -value = 0.5). Therefore, there was no meaningful difference between two groups in IOP. This results similar to El bendary et al (2011) revealed transient increase in IOP in IVTA 12.5%, and IVD group showed IOP reduction ($p=0.02$).⁴ Moreover, Hegazy et al (2015) revealed that 12.5% increase in IOP for (IVR) and reduction in IOP in (IVD) $p(=0.02)$.¹⁴ Faghihi et al (2007) reported after 1st week IVD showed IOP reduction and in bevacizumab increase ($p=0.3$). With insignificance in this increase. No side effects after injection.¹²

Seth et al (2016) revealed no change was detected in IOP measurement.¹³ Good et al (2011) compared ranibizumab versus bevacizumab and reported increase in IOP for ranibizumab 3.1% and bevacizumab 9.9% $p(<0.001)$.¹⁷ On the other hand, Soheilian et al (2010) revealed increase in IOP in IVD during 1st week.⁸

The present study showed that IVD was not associated by systemic or local complication like lens opacification, glaucoma, endophthalmitis, traumatic injury of the lens, and retinal detachment. Same results seen by El bendary et al (2011) and Hegazy et al (2015).^{4,14}

Limitations

The present study limited by low number cases and short period of recording notes to detect any difference between the groups.

Long-term studies are needed to determine IVD safety, effectiveness, evaluating their ideal regimen, duration of treatment and potential role in the treatment of DME.

CONCLUSION

The study demonstrated the effectiveness of intravitreal NSAIDs in management of DME.

This study showed that IVD have an efficacy rather than IVR for DME in enhancement of vision, with reduction of IOP and no statistical significant difference in CMT reduction. IVD could be used as an accessory or even substitute to other modalities such as anti-VEGF drugs.

REFERENCES

1. Gabriel Cocos, Jose Cunha-Vaz, and Gisele Soubrane, Definition and Basic Concepts ch.1. In: Macular Edema A practical Approach. Coscas (ed). Basel, Karger. 2010; vol 47, pp 1-9.

2. Albert DM and Jakobiec FA, Principle and practice of ophthalmology. 3rd Edition. Philadelphia.WBS Saunders Co. 2008; VOL:II page 1783.
3. David JBrowning, diabetic macular edema ch.7 in diabetic retinopathy Evidence - based management springe David j browning editor. 2010; Pp 152-78.
4. Elbendary A and Shahin M, Intravitreal diclofenac versus intravitreal triamcinolone acetate in the treatment of diabetic macular edema. *Retina*. 2011; 31 (10):2058–2064.
5. Semeraro F, Russo A, Gambicorti E, Efficacy and vitreous levels of topical NSAIDs. *Expert Opin Drug Deliv*. 2015;12 (11):1767-82.
6. Gillies M, Kuzniarz M, Craig J, Intravitreal triamcinolone-induced elevated intraocular pressure is associated with the development of posterior sub-capsular cataract. *Ophthalmology*. 2005; Jan;112 (1):139-43.
7. Mukkamala L, Bhagat N and Zarbin M, Practical Lessons from Protocol T for the Management of Diabetic Macular Edema. *Dev Ophthalmol* . 2017; 60:109-24.
8. Soheilian M, Karimi S, Ramezani A, Pilot study of intravitreal injection of diclofenac for treatment of macular edema of various etiologies. *Retina* . 2010; Mar;30(3):509-15.
9. Hariprasad S, Callanan D, Gainey S , Cystoid and diabetic macular edema treated with nepafenac 0.1%. *J Ocul Pharmacol Ther*. 2007;23(6):585-90.
10. Callanan D and Williams P, Topical nepafenac in the treatment of diabetic macular edema. *Clin Ophthalmol*. 2008; 2(4):689-92.
11. Singh R, Alpern L, Jaffe GJ, Evaluation of nepafenac in prevention of macular edema following cataract surgery in patients with diabetic retinopathy. *Clin Ophthalmol*. 2012; 6:1259-69.
12. Faghihi H, Yahyapour H, Mahmoudzadeh R, Comparison of intravitreal bevacizumab and intravitreal diclofenac in the treatment of diabetic macular edema: a 6-month follow-up. *Med Hypothesis Discov Innov Ophthalmol*. Fall. 2017; 6(3):67-75.
13. Seth A, Ghosh B, Raina U, Intravitreal Diclofenac in the Treatment of Macular Edema Due to Branch Retinal Vein Occlusion. *Ophthalmic Surg Lasers Imaging Retina*. 2016; 47(2):149-55.
14. Hegazy S, El-Sada M, El-Malt M, Intravitreal Diclofenac Versus Intravitreal Triamcinolone for Diabetic Macular Edema. *Med. J. Cairo Univ*. 2015; 83 (2): 95-100.
15. Wang H, Sun X, Liu K, Intravitreal ranibizumab (lucentis) for the treatment of diabetic macular edema: a systematic review and meta-analysis of randomized clinical control trials. *Curr Eye Res*. 2012; 37(8):661-70.
16. Wang H, Sun X, Liu K, Intravitreal ranibizumab (lucentis) for the treatment of diabetic macular edema: a systematic review and meta-analysis of randomized clinical control trials. *Curr Eye Res*. 2012; 37(8):661-70.
17. Good T, Kimura A, Mandava N, Sustained elevation of intraocular pressure after intravitreal injections of anti-VEGF agents. *Br J Ophthalmol*. 2011; 95(8):1111-4.