



6-1-2022

Short Term Evaluation of Hybrid Fixation of Adolescent Both-bone Forearm Diaphyseal Fracture

Ahmed Ali

Orthopedic Surgery Department, Faculty of Medicine, Al-Azhar University, Cairo, Egypt,
ahmedshehta83@gmail.com

Ismael Yassin

orthopaedic surgery faculty of medicine Alazhar university cairo egypt, ismailyasseen2@gmail.com

Lotfy Shwitter

Departments of Orthopedic Surgery, Faculty of Medicine, Al-Azhar University, Cairo, Egypt,
lotfy.m.shwitter@gmail.com

Follow this and additional works at: <https://aimj.researchcommons.org/journal>



Part of the [Medical Sciences Commons](#), [Obstetrics and Gynecology Commons](#), and the [Surgery Commons](#)

How to Cite This Article

Ali, Ahmed; Yassin, Ismael; and Shwitter, Lotfy (2022) "Short Term Evaluation of Hybrid Fixation of Adolescent Both-bone Forearm Diaphyseal Fracture," *Al-Azhar International Medical Journal*: Vol. 3: Iss. 6, Article 4.

DOI: <https://doi.org/10.21608/aimj.2022.107040.1673>

This Original Article is brought to you for free and open access by Al-Azhar International Medical Journal. It has been accepted for inclusion in Al-Azhar International Medical Journal by an authorized editor of Al-Azhar International Medical Journal. For more information, please contact dryasserhelmy@gmail.com.

Short Term Evaluation of Hybrid Fixation of Adolescent Both-bone Forearm Diaphyseal Fracture

Ahmed Shehta Ali,¹ M.B.B.Ch, Ismael Ahmed Yassen,¹ MD, Lotfy Shwitter,¹ MD.

* Corresponding Author:

Ahmed Shehta Ali

Ahmedshehta83@gmail.com

Received for publication December 5, 2021; Accepted June 15, 2022; Published online June 15, 2022.

Copyright The Authors published by Al-Azhar University, Faculty of Medicine, Cairo, Egypt. Users have the right to read, download, copy, distribute, print, search, or link to the full texts of articles under the following conditions: Creative Commons Attribution-Share Alike 4.0 International Public License (CC BY-SA 4.0).

doi: 10.21608/aimj.2022.107040.1673

¹Orthopedic Surgery Department, Faculty of Medicine, Al-Azhar University, Cairo, Egypt.

ABSTRACT

Background: In children and adolescents, both-bone forearm fractures have been one of the most prevalent injuries.

Aim of the study: To assess the clinical and radiographic outcomes of hybrid fixation (ulnar plating and elastic stable intramedullary nailing for the radius) the optimal method of stabilization is controversial.

Patients and Methods: This randomized controlled trial was carried out at Bab Al-Sharia (Sayed Galal) university hospital. It included 20 adolescent patients who had both-bone forearm diaphyseal fractures. The research lasted from May 2017 to May 2018.

Results: The average age of the cases studied was 12.87 years, with 15 males (75%) and 5 females (25%), respectively. Union has been accomplished in all patients in the current study. The average radius was 6.2 weeks (6–8 weeks). While for ulna the mean was 8.2 weeks (6-14 weeks) delayed union occurred in 2 cases, complete union was reached at 14 weeks with no obvious cause for this delay. The mean postoperative supination range was 83.75°, while mean pronation was 69.5°. Sixteen patients (80.0%) showed excellent outcomes. 3 patients (15%) showed good outcomes. Only one case (5%) showed fair outcome due to limited forearm rotation range and deep wound infection.

Conclusion: In skeletally immature patients aged from 10 to 16 years, hybrid fixation is an acceptable, safe, and efficient alternative method of treatment.

Keywords: Bone forearm diaphyseal fracture; Hybrid fixation.

Disclosure: The authors have no financial interest to declare in relation to the content of this article. The Article Processing Charge was paid for by the authors.

Authorship: All authors have a substantial contribution to the article.

INTRODUCTION

Fractures of both bones in the forearm represent 3.4% of all pediatric fractures and 26% of all pediatric upper limb fractures.^{1,2}

Even though non-operative treatment is still a viable therapy alternative for children over the age of ten, they are more prone to malunion owing to low bone remodeling potential. As a result, this age group may benefit from surgical intervention.⁵

Hybrid fixation, which combines an elastic stable intramedullary nail (ESIN) for fixing the radius with traditional ulnar plate fixation to decrease nonunion rates and provide forearm rotational control with ulnar plate fixation, while lowering the requirement for dissection of soft tissue for radius plating, is an appealing option.

This work aimed to evaluate the clinical and radiological outcomes of hybrid fixation (ulnar plating and elastic stable intramedullary nailing for the radius) in the therapy of adolescent both bone forearm diaphyseal fractures.

PATIENTS AND METHODS

Candidates were chosen in the study based to the following criteria: Diaphyseal both bone forearm fracture, age group: 10-16 years and non-comminuted stable fracture. While patients with neurovascular Injury, open fractures, below ten years / patient above 16 years, comminuted fractures and pathological fractures were omitted from the study.

All candidates underwent routine anteroposterior (AP) and lateral radiographs of their whole forearm, from the wrist to elbow

Discussion of the technique and its potential complications were done with the patient and their parents clarifying pros and cons.

Surgical technique: All patients were given general anesthesia and prophylactic intravenous antibiotic (3rd generation cephalosporin). The tourniquet was applied for most of patients. A sterile upper limb drape was placed after the whole upper limb was sterilized.

Preparation and Selection of the fixation implants:

Retrograde ESIN for Radius: Two entry points for retrograde nailing of the radius were identified: The proximal part of Lister's tubercle is the entry site for the dorsal physal sparing. The first dorsal extensor compartment floor can be used as a lateral entry point. Lateral entry was used in all patients.

The nail was accurately situated between the brachio-radialis tendon's dorsal insertion and the radial artery's ventral surface on the radius. During dissection, the cephalic vein and the sensory branches of the superficial radial nerve are less likely to be damaged. To mitigate the likelihood of the awl slipping anteriorly and injuring the radial artery, the awl or drill bit was directed dorsally. Then identification of SRN is done to avoid its injury. The bone surface must be directly visualized to keep the tendon from being injured during nail insertion. Because the nail was inserted obliquely, more distal space was required to prevent skin impingement.

Open reduction of the radius was indicated after failure of two trials of closed reduction to avoid compartment syndrome. This was done in two cases only in which the fracture level was in the proximal third. To facilitate later removal, only 3–5 mm protruded from the bone. An impactor was used to bend the nail ends if they were excessively protruding.

ORIF for Ulna: The assistant fixes the elbow flexed to bring ulna into near vertical position. Dorsal incision was made along subcutaneous edge of the ulna. The dissection was done in minimal and atraumatic way to preserve soft tissue. After visualization of the fracture edges, hematoma and interposed soft tissue were cleaned out. Washing saline was applied to clean the fracture site. Once reduced, pointed reduction clamp was placed over fracture site. 6-8-hole 3.5mm plate was applied on the dorsal of the ulna but not on subcutaneous border due to possible hardware irritation. Two holes with bicortical screws proximal and distal were put in compression mode then checked on image intensifier AP/Lat for alignment and rotation, and then the remaining ulna bicortical screw holes were completed and filled.

Wound closure: Wounds were thoroughly irrigated, and tourniquet deflated. Wounds were closed in 3 layers. Dressing was followed by soft band and above elbow splint for immobilization.

Patients' assessment and follow up:

Each patient was immobilized post operatively in an above elbow back slab in neutral rotation at the end of the operation for 2 weeks. Neurovascular status was re-checked and finger movements were encouraged. Following fixation, the patient returned for 2–4 months of follow-up visits every two weeks. Assessment of the reduction quality used the final intra-operative or initial post-operative radiographs. Serial radiographic assessment was done after 2 weeks, 4 weeks, 6 weeks and 12 weeks after surgery and evaluated for secondary fracture displacement, and union. It is advised that the nail be removed once the fracture has completely healed (usually 6 months after trauma, but not before 16 weeks). Early metal elimination, according to some researchers, increases the risk of refractures significantly¹⁵. We were not faced with this issue because we removed the metal later, usually after 6 months.

Follow up: .¹⁶ Union has been assessed clinically and radiologically. Complete union was considered when pain and tenderness disappeared at the fracture site and after the appearance of sufficient callus bridging the fracture site at least 3 cortices of bone on both AP and lateral views.

Functional assessment: Martus et al. developed an outcome grading system that was used to assess the overall functional outcome.¹⁶ Complications have been evaluated employing a modified Clavien-Dindo classification of surgery complications.¹⁷

Statistical Methods: The SPSS (Statistical Package for the Social Sciences) version 25 statistical package has been used to code and enter the data. For quantitative data, the mean, median, standard deviation, minimum, and maximum have been used to summarize the data, while categorical data was summarized by utilizing relative frequency (percentage) and frequency (count). Age, surgery period, time from injury to surgery, postoperative immobilization period, follow-up period, time to bone union, and ROM were all continuous factors. Gender, injury side, injury mechanism, fracture union type, functional result, and rate of complication have been categorical factors. The chi-squared test or Fisher's exact test has been used to analyze all categorical data.

RESULTS

	Mean	Min.	Max.
Age	12.87 years	10 years	16 years

Table 1: Age distribution

Mode of trauma	Fall on the ground	Road traffic accident
Count	16	4
%	80 %	20 %

Table 2: Mode of injury.

Dominance	Right	Left
Count	16	4
%	80%	20%
Hand affected		
Count	14	6
%	70%	30%

Table 3: Hand dominance and hand affected.

	Proximal	Mid shaft	Distal
Count	2	15	3
%	10%	75%	15%
	Proximal	Mid shaft	Distal
Count	2	16	2
%	10%	80%	10%

Table 4: Radial fracture level and Ulnar fracture level.

	Day 0	Day 1	Day 2	Day 3	Day 4
Count	12	4	2	1	1
%	60%	20%	10%	5%	5%

Table 5: Surgery timing.

	Closed reduction	Open reduction
Count	18	2
%	90 %	10 %

Table 6: Reduction of the radius

	Mean	Min.	Max.
Operative time (min)	57.6	35	90

Table 7: Operative time.

	Primary union	Secondary union
Count	11	9
%	55%	45%

Table 8: Union Type of ulna.

	Mean	Min.	Max.
Radius	6.2 weeks	6 weeks	8 weeks
Ulna	8.2 weeks	6 weeks	14 weeks

Table 9: Union of radius and ulna.

	Mean	Min	Max
Supination(degree)	83.75°	70°	85°
Pronation (degree)	69.5°	65°	70°

Table 10: Distribution of supination and pronation range.

Supination (degree)	85°	80°	70°
Count	17	2	1
%	85%	10%	5%

Table 11: Supination range.

Pronation (degree)	70°	65°
Count	18	2
%	90%	10%

Table 12: Pronation range.

Functional outcome	Excellent	Good	Fair	Poor
Count	16	3	1	0
%	80%	15%	5%	0%

Table 13: Functional outcome according to Outcome Grading System.

	Wound complications	
	Deep infection	Superficial infection
Count	1	3
%	5%	15%

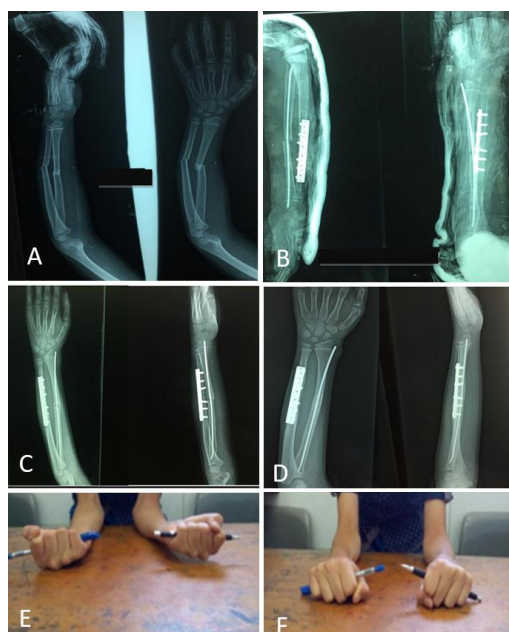
Table 14: Wound complications.

Fig 1: 10-year-old male, presented to the emergency department after falling on outstretched hand with mid-shaft transverse fracture of both bones Rt. forearm at the same level. Hybrid fixation was done 1 day after trauma. Post-operative: above elbow slab for 2 weeks. Two weeks following fixation slab was removed and patient started elbow and forearm range of motion. 3 months follow up showed complete union with full supination and pronation compared to the contralateral side. A) AP and lateral radiographs of a 10-year-old boy with a both-bone fracture of the right forearm. B) Hybrid fixation was performed. AP and lateral postoperative radiographs. C) Follow-up radiographs after 4 weeks. D) Follow-up radiographs after 3 months showing complete union of both radius and ulna fractures. E and F) Full supination and pronation three months post-operative.

DISCUSSION

Most both-bone forearm fractures in children aged 10 to 16 years can now be effectively treated with excellent outcomes using closed methods. In some

cases, however, closed reduction is insufficient, and open reduction with internal fixation is required^{19, 20}. Plate fixation provides perfect reduction but, hypothetically, it may be associated with increasing risk of nonunion due to soft tissue dissection and periosteal stripping¹⁵. Over plating, it has been reported that ESIN has the advantages of tiny incisions, shorter surgery times, and less dissection at the site of the fracture. However, ESIN may require open reduction or may be associated with less success rate in children with age of 10 years or older.^{13, 21, 22}

To balance the advantages and disadvantages of both methods of fixation (plating and nailing), we chose hybrid fixation, which combines ESIN fixation of the radius with plate and screw fixation of the ulna, for the diaphyseal treatment of both bone forearm fractures in older children.

In children ranging in age from 10–16 years, several studies compared the outcomes of hybrid fixation, dual ESIN fixation, open reduction, and dual plate fixation in the treatment of dual-bone forearm fractures.^{9, 21, 22, 25}

Twenty patients with both-bone forearm shaft fractures were included in our prospective study. Their average age is 12.87 (range 10-16). In approximately skeletally mature adolescents with diaphyseal both-bone forearm fractures, all patients underwent reduction and internal fixation using hybrid fixation, which combined ORIF of the ulna with elastic intramedullary fixation of the radius. The aim of our research was to assess the surgical efficacy and advantages of this method of fixation. Titanium elastic nails were unique in that they were extremely flexible and could be remodeled to fit the radius curvature. It could be easily pre-bent and contoured to create a fixation with two or more points based on the fracture properties and location. Fixation of the ulna with a plate and screws affords more stability to the forearm, and the anti-rotation performance has been improved even more. So, patients will not require a long period of immobilization and can start early ROM.

The average duration of follow-up has been 6.9 months (range 6-9 months) and patients were assessed for union, functional outcome, ROM and complications.

The results of the present study were high rate of good and excellent functional outcome, 16 cases (80.0%) showed excellent outcome. 3 cases (15%) showed good outcome. only one case (5%) showed fair outcome.

Regarding range of motion (ROM), the mean supination range was 83.75°, mean pronation range was 69.5° with full elbow and wrist ROM.

Radial union has been attained in every patient, with an average time of radial union of 6.2 weeks (min. 6 weeks, max. 8 weeks). In regard to ulna, the mean time of union was 8.2 weeks (min. 6 weeks, max. 14 weeks).

Regarding complications, delayed union of ulna occurred in 2 patients; both of these cases were 15

year-old male patients .One of them developed deep infection and needed debridement and plate removal at 8 weeks after operative fixation and, all of the delayed unions had fully healed by 3-4 months.

Wound infection occurred in 4 patients, 3 patients (15%) with superficial infection. Empirical oral antibiotics were given and infection subsided within one week. Deep infection was noticed in 1 occasion (5%). It occurred at the ulnar incision site and necessitated debridement and early removal of implant (major complication). (8 weeks after fixation)

After comparison of our results with that of other studies that used hybrid method of fixation, there are no significant differences regarding age, sex, trauma mode, and duration of surgery, we noticed that the percentage of excellent and good outcome slightly higher (95 % in our study compared to (89-93 %) in other studies) and slightly less mean time to union than that mentioned in other studies (As detailed in tables 15, 16).

Studies	Functional outcome	The % of Excellent and good result outcome	Time to union
Hybrid fixation	Feng et al 9 Price et al criteria 144	Excellent 18, 64% Good 8, 29 % Fair 2, 7%	93 % 9.15+-3.75 weeks
Plate for ulna	Zheng et al 143 Price et al criteria 144	Excellent % 26, 57.8% Good % 16, 35.6% Fair % 3, 6.7%	93.3 % 9.3+-1.9 weeks
Nail for radius	Cai et al 101 Price et al criteria 144	Excellent % 11, 57.8% Good % 6, 31.6% Fair % 1, 5.3% Poor % 1, 5.3%	89.4 % 11.8 weeks
	Our study	Excellent % 16, 80 % Good % 3, 15 %	95 % Radius = (6.2 weeks) Ulna = (8.2 weeks)
Hybrid fixation	Martus et al criteria 135,124	Fair 1, 5% Poor 0	
Hybrid fixation	Zhu et al 113 Price et al criteria 144	Excellent 15, 57.7% Good 9, 34.6 % Fair 2, 7.7%	92.3 % 10.81+ - 1.47 weeks
Plate for radius		Unsatisfactory 0 Good 5, 17.2 % Acceptable 6, 20.7%	
Nail for ulna		Unacceptable 1, 3.4 %	

Table 15: Comparison with other studies' results with hybrid fixation (1)

	Feng et al	Zheng et al	Cai et al	Zhu et al	Our study
Age (years)	13.8	13.2	13.1	13.27	12.8
Sex :male	64	62	68	57.7	75
Female	36	37	32	42.3	25
Mode of injury					
FOG	71	51.1	89.4	73.1	80
RTA	25	26.7		19.2	20
Others	4	22	10.6	7.7	
Duration of surgery (min.)	57.5	56.0	51.1	46.9	57.6

Table 16: Comparison with other studies' results with hybrid fixation (2).

	Our (hybrid)	study	D-ESIN	D-PLATE
Duration of Surgery Minutes	57.6		• 53.29 ± 10.84 in Feng et al (9)	• 67.4 ± 9.7 in Zheng 143 • 64.3 in Cai et al 101 • 56.6 in Zhu 113
Time to union Weeks	Radius = (6.2 weeks) Ulna = (8.2 weeks) 7.2 week		• 11.44 ± 4.10 in Feng et al 9 • 10.3 ± 2.3 in Zheng et al 143	• 9.1 ± 2.2 in Zheng 143 • 12.4 in Cai 101 • 10.43 ± 1.50 in Zhu 113
Functional outcome	95 %		• 82 % in Feng et al 9	• 88.6 % in Zheng 143
Excellent outcome	+good		• 89.6 % in Zheng et al 143	• 84.6 % in Cai 101 • 86.7 % in Zhu 113

Table 17: Comparison of our study with other studies' results with different fixation.

CONCLUSION

In skeletally immature patients aged from 10 to 16 years, hybrid fixation is an acceptable, safe, and efficient alternative method of treatment for both-bone diaphyseal forearm fractures.

REFERENCES

- Landin LA. Fracture patterns in children: analysis of 8682 fractures with special reference to incidence, etiology and secular changes in a Swedish urban population. *Acta Chir Scand Suppl.* 1983; 202:1950-79.
- Mann DC and Rajmaira S. Distribution of physeal and nonphyseal fractures in 2,650 long-bone fractures in children aged 0-16 years. *Journal of pediatric orthopedics.* 1990; 10(6):713-6.
- Larsen EI, Vittas DI, Torp-Pedersen S. Remodeling of angulated distal forearm fractures in children. *Clinical orthopaedics and related research.* 1988;(237):190-5..
- Vittas DI, Larsen EI, Torp-Pedersen S. Angular remodeling of midshaft forearm fractures in children. *Clinical orthopaedics and related research.* 1991; (265):261-4.
- Kay S, Smith C, Oppenheim WL. Both-bone midshaft forearm fractures in children. *Journal of pediatric orthopedics.* 1986; 6(3):306-10.
- Sun YQ, Penna J, Haralabatos SS, et al. Intramedullary fixation of pediatric forearm diaphyseal fractures. *American journal of orthopedics.* 2001; 30(1):67-70.
- Myers GJ, Gibbons PJ and Glithero PR. Nancy nailing of diaphyseal forearm fractures: single bone fixation for fractures of both bones. *The Journal of bone and joint surgery. British volume.* 2004; 86(4):581-4.
- Cheng JC, Ng BK, Ying SY, et al. A 10-year study of the changes in the pattern and treatment of 6,493 fractures. *Journal of Pediatric Orthopaedics.* 1999; 19(3):344-50.
- Feng Y, Shui X, Wang J, et al. Comparison of hybrid fixation versus dual intramedullary nailing fixation for forearm fractures in older children: case-control study. *International Journal of Surgery.* 2016; 30:7-12.
- Schmittenebecher PP, Fitze G, Gödeke J, et al. Delayed healing of forearm shaft fractures in children after intramedullary nailing. *Journal of Pediatric Orthopaedics.* 2008; 28(3):303-6.
- Sinikumpu J-J, Lautamo A, Pokka T, et al. Complications and radiographic outcome of children's both-bone diaphyseal forearm fractures after invasive and non-invasive treatment. *Injury.* 2013; 44(4):431-6.
- Sinikumpu JJ, Victorzon S, Antila E, et al. Nonoperatively treated forearm shaft fractures in children show good long-term recovery. *Acta Orthop.* 2014; 85(6):620-5.
- Flynn JM, Jones KJ, Garner MR, et al. Eleven years experience in the operative management of pediatric forearm fractures. *Journal of Pediatric Orthopaedics.* 2010; 30(4):313-9.
- Mehlman CT and Eric J. Wall, Diaphyseal Radius and Ulna Fractures. Rockwood and Wilkins' fractures in children, 8th Edn. *Wolters Kluwer. Philadelphia.* 2015; 413-67.
- Hunter JB. The principles of elastic stable intramedullary nailing in children. *Injury.* 2005; 36(1 SUPPL.).
- Martus JE, Preston RK, Schoenecker JG, et al. Complications and Outcomes of Diaphyseal Forearm Fracture Intramedullary Nailing. *J Pediatr Orthop.* 2013; 33(6):598-607.
- Clavien PA, Barkun J, de Oliveira ML, et al. The Clavien-Dindo Classification of Surgical Complications. *Ann Surg.* 2009; 250(2):187-96.
- Raiss P, Rettig O, Wolf S, et al. Range of motion of shoulder and elbow in activities of daily life in 3D motion analysis. *Z Orthop Unfall.* 2007; 145(4):493-8.
- Zionts LE, Zalavras CG and Gerhardt MB. Closed treatment of displaced diaphyseal bothbone forearm fractures in older children and

- adolescents. *J Pediatr Orthop*. 2005; 25(4):507–12.
20. Ayodele OO and Abraham A. Evidence-Based Treatment of Forearm Fractures in Children. In pediatric orthopedics. *Springer, Cham*. 2017; 347-52.
 21. Cai L, Wang J, Du S, et al. Comparison of hybrid fixation to dual plating for both-bone forearm fractures in older children. *American journal of therapeutics*. 2016; 23(6):1391-6.
 22. Zhu S, Yang D, Gong C, et al. A novel hybrid fixation versus dual plating for both-bone forearm fractures in older children: A prospective comparative study. *Int J Surg*. 2019; 70:19-24.
 23. Ogonda L, Wong-Chung J, Wray R, et al. Delayed union and non-union of the ulna following intramedullary nailing in children. *Journal of Pediatric Orthopaedics B*. 2004; 13(5):330-3.
 24. Fernandez FF, Eberhardt O and Langendörfer M. Wirth T, Nonunion of forearm shaft fractures in children after intramedullary nailing. *Journal of Pediatric Orthopaedics B*. 2009; 18(6):289-95.
 25. Zheng W, Tao Z, Chen C, et al. Comparison of three surgical fixation methods for dual-bone forearm fractures in older children: A retrospective cohort study. *International Journal of Surgery*. 2018; 51:10-6.