



4-1-2022

Cervical length Measurements and Uterine Artery Doppler in Prediction of Preterm Labour of High-Risk Women

Ahmed El Sayed

Obstetrics and Gynecology Department, Faculty of Medicine, Al-Azhar University, Cairo, Egypt,
dr.ahmedsalh.auc@gmail.com

Ahmed Amer

Obstetrics and Gynecology, Faculty of Medicine, Al-Azhar University, Cairo, Egypt, asamyamer@gmail.com

Ashraf Mohamed

Obstetrics and Gynecology, Faculty of Medicine, Al-Azhar University, Cairo, Egypt, ashraf.hamdy@live.com

Follow this and additional works at: <https://aimj.researchcommons.org/journal>



Part of the [Medical Sciences Commons](#), [Obstetrics and Gynecology Commons](#), and the [Surgery Commons](#)

How to Cite This Article

El Sayed, Ahmed; Amer, Ahmed; and Mohamed, Ashraf (2022) "Cervical length Measurements and Uterine Artery Doppler in Prediction of Preterm Labour of High-Risk Women," *Al-Azhar International Medical Journal*: Vol. 3: Iss. 4, Article 26.

DOI: <https://doi.org/10.21608/aimj.2022.108619.1697>

This Original Article is brought to you for free and open access by Al-Azhar International Medical Journal. It has been accepted for inclusion in Al-Azhar International Medical Journal by an authorized editor of Al-Azhar International Medical Journal. For more information, please contact dryasserhelmy@gmail.com.

Comparative Study Between Extracapsular Dissection and Superficial Parotidectomy in Treatment of Benign Parotid Tumors

General Surgery

Mohamed Mohamed Atya Mohamed Ayad ^{1,*} Msc, Mohamed Ibrahim El-Anany ² MD,
Ahmed Abd El Aal Sultan ² MD, Mohamed Salah Elfeshawy ³ MD

*Corresponding Author:

Mohamed Mohamed Atya Mohamed Ayad
drmohamedayad230@gmail.com

Received for publication November 23, 2021; Accepted April 16, 2022;
Published online April 16, 2022.

Copyright The Authors published by Al-Azhar University, Faculty of Medicine, Cairo, Egypt. Users have the right to read, download, copy, distribute, print, search, or link to the full texts of articles under the following conditions: Creative Commons Attribution-Share Alike 4.0 International Public License (CC BY-SA 4.0).

doi: 10.21608/aimj.2022.107677.1681

¹Surgical oncology Department, fakus cancer centre sharki, Cairo, Egypt.

²General Surgery Department, Faculty of Medicine, Al-Azhar University Cairo, Egypt.

³Diagnostic Radiology Department, Faculty of Medicine, Al-Azhar University Cairo, Egypt.

ABSTRACT

Background: In the treatment of benign parotid tumours, extracapsular dissection (ECD) and superficial parotidectomy (SP) were compared.

Aim of the work: Comparing the outcomes of ECD and SP in the surgical removal of a benign parotid tumour and the rate of recurrence.

Patients and methods: This study was conducted on 100 patients with benign parotid tumours who were admitted to the general surgery department of AL-Azher university hospitals and fakus cancer centre between May 2017 and July 2020. After completing a full history and clinical examination, the patients were divided into two groups: the first 50 patients had an ECD. A benign tumour with a diameter of less than 4 cm, no deep lobe invasion, and another 50 individuals were included in the study SP was performed with a one-year follow-up to determine the rate of recurrence in both groups.

Results: The follow up period was 12 months. In terms of complain, operation time, tumour size, and recurrence the most common complain in both groups is preauricular swelling; the time of operation in ECD is 42.80±5.54 minutes compared to 127.36±16.36 minutes in SP; the tumour diameter in ECD is less than 5 cm compared to more than 5 cm in SP; the most common pathological type in both groups is pleomorphic adenoma. In SP 5 patients had disease recurrence, while in ECD, 3 patients had disease recurrence.

Conclusion: In terms of recurrence rates, conservative parotidectomy was comparable to superficial parotidectomy.

Keywords: Parotidectomy; tumours; parotid.

Disclosure: The authors have no financial interest to declare in relation to the content of this article. The Article Processing Charge was paid for by the authors.

Authorship: All authors have a substantial contribution to the article.

INTRODUCTION

A benign Parotid gland tumour appears as a slowly developing preauricular lump in the superficial lobe of the Parotid gland ¹. The pleomorphic adenoma of the Parotid gland that manifests as a single, movable, well-defined border, and is not painful. and The Warthin's tumour is a second form. ². superficial parotidectomy. is performed with removal of the superficial lobe and preservation of the facial nerve ³ Extracapsular dissection is performed with a cruciate incision above the tumour and a rim of 2mm normal tissue including the capsule is then removed ⁴

PATIENTS AND METHODS

This prospective study included 100 cases with benign parotid tumours who were admitted to the general surgery department of AL-Azher university hospitals and fakus cancer centre between May 2017 and July 2020. After a full history and clinical examination, the patients were divided into two groups: the first 50 patients had ECD done with careful dissection of the tumour and its capsule, and the second 50 patients had sp done. The inclusion criteria were benign mass, no invasion of the deep lobe, and a diameter of

less than 5 cm, as well as another 50 patients with facial nerve dissection who were included in SP. Following surgery, the drain was removed, and stitches were removed on day 7, with follow-up every month for a year and recurrence documented. Exclusion criteria include malignant histology and tumour placement in the deep lobe. Patients agreed to participate in the trial and gave their informed permission.

Superficial Parotidectomy. In a preauricular crease a modified Blair incision was made that ran down into the subcutaneous tissues and platysma muscle. Elevate the anterior flap to the anterior side of the gland superficial to the larger auricular nerve and the parotid fascia. The peripheral facial nerve branches are carefully avoided. To reveal the parotid gland's tail, a posterior and inferior flap is also raised. The flaps are retracted using silk suture after elevation. Dissect The parotid gland's tail is exposed from the sternocleidomastoid, followed by the posterior belly of the digastric muscle. To open the preauricular space divide the parotid gland attachments to the cartilaginous external auditory canal by blunt dissection. This plane of dissection exposes the tragal cartilage allowing anatomic landmarks such as the posterior belly of the digastric muscle the tragal pointer and the tympanomastoid suture to be used to identify the facial nerve. It also divides the parotid gland superficial to

the facial nerve. A dissector is used to travel along the facial **Surgical Technique of Extracapsular parotidectomy.** In a preauricular crease a modified Blair incision was made that ran down into the subcutaneous tissues and platysma muscle. Elevate the anterior flap to the front of the gland just beneath the larger auricular nerve and the parotid fascia. palpate Above it was a tumour and a cruciate incision. locate and

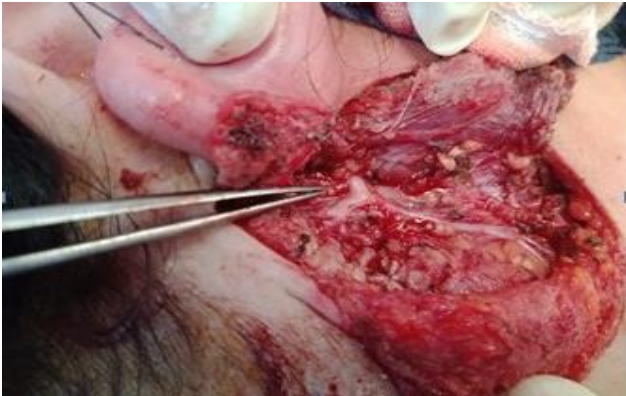

Fig. 1: Exploration of facial nerve

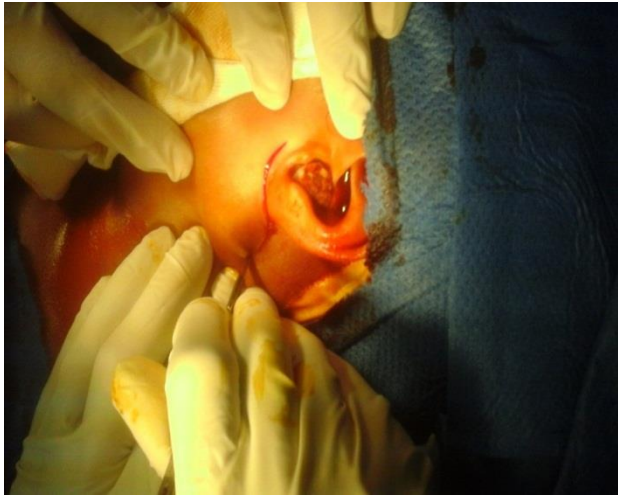


Fig. 2: A standard modified Blair incision

nervaise it and then spread it gently. dissect the a loose areolar plane surrounding the bulk without rupturing the capsule appley Four artery clips are attached to the parotid fascia at the cruciate incision's centre to retract the parotid fascia and allow for blunt dissection into the parenchyma until the tumour is seen. Edges of the cruciate incision were re-aproximated and sutured together.

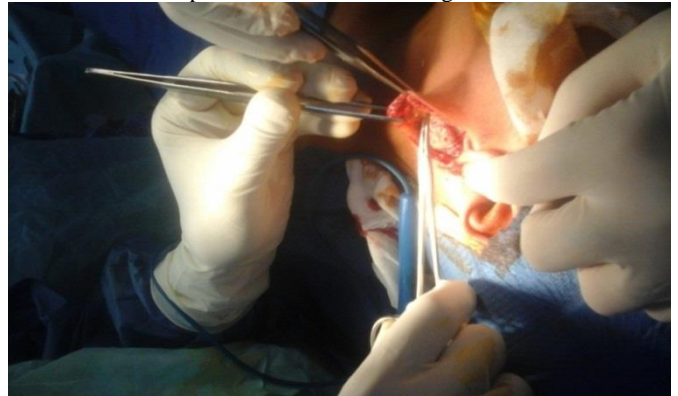


Fig. 3: The mass is identified and a cruciate incision is made above the lesion

RESULTS

Table1: Age was distribution as 36.86 ± 7.21 and 38.94 ± 7.51 with no significant difference between groups and regard sex distribution there was no significant difference between groups

			Superficial parotidectomy Group	Extra-capsular parotidectomy Group	t	P
Age Years			36.86 ± 7.21	38.94 ± 7.51	1.411	0.161
Sex	Male	N	29	26		
		%	58.0%	52.0%		
	Female	N	21	24	0.36	0.54
		%	42.0%	48.0%		
Total		N	50	50		
		%	100.0%	100.0%		

Table1: age and sex distribution between studied groups

Table2: This table shows that there was no significant difference between groups and the majority of both groups were unilateral

			Group		X ²	P
laterality			Superficial parotidectomy Group	Extracapsular parotidectomy Group		
laterality	Unilateral	N	48	50		
		%	96.0%	100.0%		
	Bilateral	N	2	0	2.04	0.15
		%	4.0%	0.0%		
Total	N	50	50			
	%	100.0%	100.0%			

Table2: side and laterality distribution between studied groups

Table3: No significant difference between group regard swelling or pain distribution and swelling was the main complaint in both groups

			Group		X ²	P
			Superficial parotidectomy Group	Extracapsular parotidectomy Group		
Swelling	-VE	N	2	3		
		%	4.0%	6.0%		
	+VE	N	48	47	0.21	0.64
		%	96.0%	94.0%		
Pain	-VE	N	47	46		
		%	94.0%	92.0%		
	+VE	N	3	4	0.15	0.69
		%	6.0%	8.0%		
Total	N	50	50			
	%	100.0%	100.0%			

Table3: Complaint distribution between studied groups

Table4 : Regard distribution of pathology between groups there was no significant difference and the majority were Plemorphic adenoma

			Group		X ²	P
Pathology			Superficial parotidectomy Group	Extracapsular parotidectomy Group		
Cavernus haemangioma	N	2	1			
	%	4.0%	2.0%			
Oncocytoma	N	1	1			
	%	2.0%	2.0%			
Basal cell adenoma	N	1	2			
	%	2.0%	4.0%			
Parotid lymph node	N	3	2	1.35	0.96	
	%	6.0%	4.0%			
Plemorphic adenoma	N	40	40			
	%	80.0%	80.0%			
Warthin s tumer	N	3	4			
	%	6.0%	8.0%			
Total	N	50	50			
	%	100.0%	100.0%			

Table4: Pathology distribution between studied groups

Table5: Operation duration was distributed between studied groups as 127.36 ±16.36 and 42.80±5.54 respectively between Superficial parotidectomy Group and Extra-capsular parotidectomy Group and Superficial parotidectomy was significantly longer regard duration

	Superficial parotidectomy Group	Extra-capsular parotidectomy Group	t	P
Operation Duration /M	127.36 ±16.36	42.80±5.54	18.657	0.00**

Table5: Operation duration distribution between studied groups

Table6: Size was distributed between studied groups as 5.12 ± 1.62 and 3.42 ± 0.64 respectively between Superficial parotidectomy Group and Extra-capsular parotidectomy Group and Extra-capsular parotidectomy was significantly smaller regard size

	Superficial parotidectomy Group	Extra-capsular parotidectomy Group	t	P
Size/cm	5.12 ± 1.62	3.42 ± 0.64	11.812	0.00**

Table6: tumor size distribution between studied groups

Table7 : We found only 8 cases had recurrence (5 cases in 1st group with 10% and 3 cases in 2nd group with 6%) with no significant difference between groups

			Group		X ²	P
			Superficial parotidectomy Group	Extracapsular parotidectomy Group		
Recurrence	-VE	N	45	47		
		%	90.0%	94.0%		
	+VE	N	5	3	0.54	0.46
		%	10.0%	6.0%		
Total		N	50	50		
		%	100.0%	100.0%		

Table7: recurrence distribution between studied groups

DISCUSSION

The parotid gland is the most prevalent location for salivary gland tumours, accounting for 60-75 percent of all occurrences with 85 percent of parotid tumours occurring in the superficial lobe 11 percent in the deep lobe and 1% in the accessory lobe⁵. The superficial parotidectomy involves locating the facial nerve trunk, dissecting along all of its branches and removing the parotid's superficial lobe⁶

Extracapsular dissection (ECD) occurs when the tumour is removed with only the immediate pseudocapsule and the facial nerve branches are not identified or dissected⁷. In our research, we discovered that 29 patients (58%) in the superficial parotidectomy group were male. 21 patients were female 42% with mean age of 36.86 ± 7.21 years. In the extracapsular dissection group, there were 26 patients (52 percent) male and 24 patients (48 percent) female, with a mean age of $38.947.51$ years (table 1). However, contrary to the findings of benign parotid tumours were found in 40.8 percent of males and 59.2 percent of women⁸. Men made up 51.6 percent of the benign parotid tumours and. The average age of diagnosis for benign tumours was 50.7 19.2 years.⁹ A total of 100 instances of parotid gland tumours were examined in this investigation. The average age of parotid gland tumours was 48.58 years, with a range of 18 to 71 years.¹⁰ In SP, 48 patients (96 percent) were unilateral, 2 patients (4 percent) were bilateral, and 50 patients (100 percent) were unilateral in ECD (table 2) the unilateral parotid gland was more often impacted than the bilateral parotid gland which was found in one patient and histology confirmed Warthin's tumour in a survey of 100 cases.¹⁰, The most prevalent clinical finding in SP 48 patients (96 percent) is swelling, with 2 patients (4 percent) reporting no swelling, and in ECD 47 patients (94 percent) reporting no swelling. The second most common complain is pain which

accounts for sp 3 patients (6%) and 47 patients (94 percent). There is no discomfort in ECD. 4 patients (8%) and 46 patients (92%) had no pain (table 3). Slowly increasing enlargement of the parotid gland was the most frequent clinical manifestation¹¹. The first finding in patients with parotid was painless swelling (79%) followed by pressure feeling (10%) and pain (3%).¹², The most frequent pathological type in SP pleomorphic adenoma 40 patients (80%) and Warthin tumour 3 individuals in our study (6 percent). Patients with parotid lymph node 3 (6%), and patients with basal cell adenoma 1 (1%), oncocytoma 1 patients (2%), cavernous hemangioma 2 patients (4%), patients (4%), and ECD pleomorphic adenoma 40 patients (80%) and Warthin tumour 4 individuals (8 percent). Patients with parotid lymph node 2 (4%), basal cell adenoma 2 (4%), oncocytoma 1 (2%), cavernous haemangioma 1 (2%), (table 4). Pleomorphic adenoma is the most prevalent benign tumour, accounting for 60.9 percent of all cases, followed by Warthin's tumor (30.4%), Basal cell adenoma (6.5%) and hemangioma (2.2%).¹³, In terms of tumour size, SP 5.12 ± 1.62 cm and ECD 3.42 ± 0.64 cm are comparable. ECD PT was dramatically decreased when compared to that of SP (127.36) minutes vs. ECD 42.80 ± 5.54 minutes. This was expected because to the time it took to first locate the FN stem and then dissect its many branches during SP.¹⁴, The follow up for one year with clinical examination and Imaging studies (ultrasound and MRI) to detect complications. The occurrence of recurrence in SP 5 patients (10 percent), patients with ECD 3 patients (6 percent). (table 7) This is distinct. When comparing ECD with superficial parotidectomy, a study from a high-volume parotid facility found no statistically significant difference in capsule rupture (3.4 vs. 1.8 percent)¹⁵. A total of 176 patients were tracked for 52 months in this study. When ECD was compared to superficial parotidectomy, the risk of recurrence was 4.5 percent against 3.6 percent.¹⁶ In our study in S p the Permanent facial nerve dysfunction is 2 %,

transient dysfunction 20 % and Frey's syndrome 20% and in ECD the Permanent facial nerve dysfunction is (0 %) transient dysfunction 10 % Frey's syndrome 4 % this differ from results in sp the Permanent facial nerve dysfunction is reported 4 %, transient dysfunction 25 % and Frey's syndrome 17 % and in ECD the incidence Permanent facial nerve dysfunction is (2 %) transient dysfunction 11 % and Frey's syndrome 3 %.

Summary

Pleomorphic adenoma is the most common benign parotid tumour, followed by Warthin tumour and, less commonly, oncocytoma and basal cell adenoma. The majority of cancers begin in the superficial lobe and manifest as slow-growing masses under the ear. The initial non-invasive method for localising superficial tumours, differentiating solid masses from cystic collections, and guiding fine-needle aspiration biopsy is Ultrasound. The superficial parotidectomy is a technique that involves the complete removal of the superficial lobe, dissection and preservation of the main trunk of the facial nerve and its branches, while ECD is a technique that involves a whole excision of the mass. Without planned dissection of the main trunk of the facial nerve, it is surrounded by healthy parotid gland tissue. In our research, we performed ECD on 50 patients and followed them up for a year to determine the recurrence rate and compare it to 50 other patients PS is done. We used SP to identify recurrence rate after one year after surgery and discovered that ECD had a lower recurrence rate than SP.

CONCLUSION

Conservative parotidectomy has a comparable recurrence rate to superficial parotidectomy and may be a suitable alternative in the treatment of benign parotid tumours that are situated in the superficial lobe, mobile, and tiny (the diameters are less than 5cm).

REFERENCES

1. Kumar V, Bhuyan S, and Gogoi M; Benign parotid tumors: An experience in a general surgical unit. *J Evol Med Dent Sci Oral Maxillo facial Surg Clin N*. 2015; 4:5138-41.
2. Tryggvason G, Gailey MP, Hulstein SL, Karnell LH, Hoffman HT and Funk GF ;Accuracy of fine needle aspiration and imaging in the preoperative workup of salivary gland mass lesions treated surgically. *Laryngoscope*. 2013;123:158-63 .
3. Eric R. Carlson, DMD, MDa, David E. Webb, Maj, USAF, DCb The Diagnosis and Management of Parotid Disease. *oral maxillofacial (surgery clin Am* 2. 2013 ; 931-48.
4. Orabona GD, Bonavolonta P, Iaconetta G ,et al., Surgical management of benign tumors of the parotid: ECD versus superficial parotidectomy-our experience in 232 cases. *J Oral maxilla fac. Surg*. 2013 ;71:410-3.
5. Bradley PJ; Frequency and Histopathology by Site, Major Pathology, Symptoms and Signs of Salivary Gland Neoplasms. *Advances in otorhinolaryngology*. 2016; 78:9-16.
6. Carlson ER and McCoy JM; Margins for Benign Salivary Gland Neoplasms of the Head and Neck. *Oral and maxillofacial surgery clinics of North America*. 2017.
7. Cristofaro MG, Allegra E, Giudice A et al Pleomorphic adenoma of the parotid: extracapsular dissection compared with superficial parotidectomy a 10-year retrospective cohort study scientific world Journal. 2014.
8. Ayoub OM, Bhatia K and Mal RK.; Pleomorphic adenoma of the parotid gland: is long-term follow-up needed? *Auris Nasus Larynx*. 2002; 29:283-5.
9. Smith WP and Langdon JD. Russell RG, Williams NS, and Bulstrode CJ Disorders of the salivary glands. In Bailey and Love's Short Practice of Surgery. 24th ed. Ch. 51. London: Arnold. 2004 pp; 718-38.
10. Ali NS, Nawaz A, Rajput S et al.; Parotidectomy: A review of 112 patients treated at a teaching hospital in Pakistan. *Asian Pac J Cancer Prev*. 2010;11:1111-3.
11. Aversa S, Ondolo C, Bollito E et al .; Preoperative cytology in the management of parotid neoplasms. *Am J Otolaryngol*. 2006;27:96-100.
12. Nemer Al- Khtoum et al., Extracapsular Dissection vs Superficial Parotidectomy of Benign Parotid Lesions Surgical Outcomes and Cost-effective , 2013.
13. Venkatesh, Teerthanath Srinivas, S. Hariprasada Parotid Gland Tumors: 2-Year Prospective Clinicopathological Study *Ann Maxillofac. Surg. Jan Jun*; 2019 ; 9(1): 103-9.
14. Masanari G. Kato, Evren Erkul, Shaun A. Nguyen, Terry A. Day, Joshua D. Hornig, Eric J. Lentsch, M. and Boyd Gillespie. Extracapsular Dissection vs Superficial Parotidectomy of Benign Parotid Lesions" Surgical Outcomes and Cost-effectiveness analysis, *JAMA Otolaryngology-Head & Neck Surgery*. 2017 ; 143(11):1092-7.
15. Orabona GD, Bonavolonta P, Iaconetta G, et al., Surgical management of benign tumors of the parotid: ECD versus superficial parotidectomy-our experience in 232 cases. *J Oral Maxillofac Surg*. 2013 ;71:410-3.
16. George KS and, Mc Gurk M. ECD-minimal resection for benign parotid tumors. *British J Oral & Maxillofac Surg*. Large series of ECD performed by high volume experienced surgeon can journal of clinical pathology. 2011;49:451-54.
17. Robert L., Witt and IroMark, The role of extracapsular dissection for Benign Parotid Tumors. *Curr Otorhinolaryngol* . 2014; 2:55-63.