



3-1-2022

Multi-detector Computed Tomography Versus Upper Gastrointestinal Endoscopy in Diagnosis and Grading of Esophageal Varices in Egyptian Cirrhotic Patients

Mahmoud Ali

Hepatogastroenterology and Infectious diseases department, Faculty of Medicine, Al-azhar university, Cairo, Egypt., mahmoudouf4@gmail.com

Mohammed Afify

Hepatogastroenterology and Infectious diseases department, Faculty of Medicine, Al-azhar university, Cairo, Egypt., amerlivercenter@azhar.edu.eg

Osama Abdelrazek

Hepatogastroenterology and Infectious diseases department, Faculty of Medicine, Al-azhar university, Cairo, Egypt., osamamos67@gmail.com

mohamed elfeshawy

Department of Diagnostic and Interventional Radiology, Faculty of Medicine, Al-Azhar University, Cairo, Egypt., mohamedelfeshawy@azhar.edu.eg

Follow this and additional works at: <https://aimj.researchcommons.org/journal>

Ahmed Abdelnaby

Part of the Medical Sciences Commons, Obstetrics and Gynecology Commons, and the Surgery, Hepatogastroenterology and Infectious diseases department, Faculty of Medicine, Al-Azhar University, Cairo, Egypt., dr_a.abdelnaby@yahoo.com

How to Cite This Article

Ali, Mahmoud; Afify, Mohammed; Abdelrazek, Osama; elfeshawy, mohamed; and Abdelnaby, Ahmed (2022) "Multi-detector Computed Tomography Versus Upper Gastrointestinal Endoscopy in Diagnosis and Grading of Esophageal Varices in Egyptian Cirrhotic Patients," *Al-Azhar International Medical Journal*: Vol. 3: Iss. 3, Article 6.

DOI: <https://doi.org/10.21608/aimj.2022.106046.1659>

This Original Article is brought to you for free and open access by Al-Azhar International Medical Journal. It has been accepted for inclusion in Al-Azhar International Medical Journal by an authorized editor of Al-Azhar International Medical Journal. For more information, please contact dryasserhelmy@gmail.com.

Multi-detector Computed Tomography Versus Upper Gastrointestinal Endoscopy in Diagnosis and Grading of Esophageal Varices in Egyptian Cirrhotic Patients

Mahmoud Madeh Ali Auf,¹ MBBCH, Mohammed Amer Afify,¹ MD, Osama Mostafa Abdelrazek¹ MD, Ahmed Mohammed Abdelnaby,¹ MD and Mohamed Salah Elfeshawy,² MD.

* Corresponding Author:

Mahmoud Madeh Ali Auf

mahmoudouf4@gmail.com

Received for publication November 15, 2021; Accepted March 21, 2022; Published online March 21, 2022.

Copyright The Authors published by Al-Azhar University, Faculty of Medicine, Cairo, Egypt. Users have the right to read, download, copy, distribute, print, search, or link to the full texts of articles under the following conditions: Creative Commons Attribution-Share Alike 4.0 International Public License (CC BY-SA 4.0).

doi: 10.21608/aimj.2022.106046.1659

¹Hepatogastroenterology and Infectious Diseases Department, Faculty of Medicine, Al-Azhar University, Cairo, Egypt.

²Diagnostic and Interventional Radiology Department, Faculty of Medicine, Al-Azhar University, Cairo, Egypt.

ABSTRACT

Background: Cirrhosis is often complicated by esophageal varices (EVs) and portal hypertension. The use of upper GI endoscopy (EGD) as a screening method is limited regarding invasiveness, expensive, needs sedation as well as patient's poor acceptance of the procedure. In contrast, Multidetector Computed Tomography (MDCT) imaging is non-invasive, does not necessitate sedation, and allows accurate assessment of variceal site and size. It is also better tolerated by patients than EGD.

Aim of the study: To assess the efficacy of MDCT in evaluating the EVs.

Patients and Methods: A prospective cross-sectional study was carried out in the hepatogastroenterology and infectious disease department and department of radiology, Al-Azhar university hospitals. From June 2021 to November 2021, fifty patients attended the outpatient clinic who had cirrhosis due to chronic HCV were enrolled in the study on a prospective basis, aged 24 to 73 years old. The studied patients were subjected to history taking, clinical examination, MDCT, and EGD.

Results: The cases were separated into three groups based on the CT findings: group I, which included 11 patients with no EVs (22%), group II, which included 11 patients with low-risk varices (22%), and group III, which included 28 patients with high-risk varices (56%). The total CT sensitivity for detecting EVs was 92.8%, with 100% specificity, 100% PPV, and a 72.7% NPV. The MDCT sensitivity for high-risk EVs cases (100%) was greater than that for low-risk EVs cases (72.7%).

Conclusion: MDCT is an excellent diagnostic alternative to conventional EGD for detecting and grading EVs in cirrhotic patients.

Keywords: Cirrhosis; Endoscopy; Computed Tomography; Portal hypertension.

Disclosure: The authors have no financial interest to declare in relation to the content of this article. The Article Processing Charge was paid for by the authors.

Authorship: All authors have a substantial contribution to the article.

INTRODUCTION

In liver cirrhosis, EVs are the commonest cause of U.G.I.T bleeding. Early detection of EVs is critical for physicians to begin a proper variceal bleeding prophylactic and treatment plan as soon as possible.¹⁻²

Currently, upper gastrointestinal endoscopy is the gold standard for the diagnosis of EVs. However, nearly all patients are poorly tolerated with EGD, and even a majority of cirrhotic patients without any previous history of portal hypertension-related complications refuse the routine examinations in our clinical practice.³

Several alternative methods have been proposed for predicting the presence of EVs in liver cirrhosis.

including ultrasonographic parameters, CT scan, magnetic resonance imaging (MRI), serum markers, liver stiffness measurement (L.S.M.), spleen stiffness measurement (S.S.M.), platelet to spleen diameter ratio (P.S.R.), and video capsule endoscopic examination.⁴

In cirrhotic patients, spontaneous portosystemic shunts, EVs, gastric varices, and paraoesophageal varices are increasingly being discovered because of significant developments in multi-detector CT imaging. Because MDCT is not invasive, with no need to sedation, and allows for the assessment and precise estimation of EVs size, it is reasonable to expect that most patients will tolerate MDCT more than EGD.⁵

Moreover, if the accuracy of CT in the detection of EVs is significant, a thorough assessment of high-risk EVs on CT scan may be beneficial in preventing the patients from performing unnecessary endoscopy, so even with the best result of CT, there is still a need for performing EGD for high-risk patients.⁶

Thus, the aim of this study is to compare the use of contrast enhanced MDCT to detect and grade EVs, as well as differentiate between EVs at low risk and those at high risk for bleeding, in comparison to endoscopy as a reference standard.

PATIENTS AND METHODS

A prospective cross-sectional study was carried out in the hepatogastroenterology and infectious disease department and the department of radiology at al-Azhar university hospitals. Fifty patients attended the outpatient clinic from June 2021 to November 2021.

Inclusion criteria:

Patients who had cirrhosis due to previous chronic hepatitis C virus were enrolled in the study on a prospective basis.

Exclusion criteria:

Active gastrointestinal bleeding on admission, cases who had a history of variceal ligations or injections. Patients with previous variceal bleeding or porto-systemic shunts Patients who refused to be enrolled in the study. Contrast media contraindications (high renal function test and history of allergy to contrast media).

The participants were informed about the study and its aim, and informed consent was declared from all participants.

Imaging Technique:

All patients were examined by MDCT scanning using CT machines (160 slice, Toshiba Medical Systems, Aquilion Prime, TSX-303A, made in Japan) at the Radiology department. Images were obtained in a single breath-hold, with the patient positioned supine with elevated arms, and a scan ranger from the carina of the trachea to the iliac crest. Patients were given IV nonionic contrast media (Ultravist 500 mg/ml) at a rate of 1.5 ml/Kg with an overall dose range of 80-100 ml, at a rate of 3.0 mL/s with a pressure injector, using a bolus-tracking program. Triphasic CT protocol, arterial phase (15 seconds), portal venous phase (44 seconds), venous phase (74 seconds) and delayed equilibrium phase (5 minutes) after contrast administration.

Image Interpretation:

On axial images, EVs were best visualized in the postcontrast portal or venous phases. They appear as intraluminal round/oval structures with marked

enhancement on axial cuts (linear on coronal reformats).

Grading of EVs: The CT images were reviewed using a 4-point confidence scale to diagnose the presence of high-risk EVs for developing bleeding based on their maximum diameter (scores 1-4). Score 1: no varices or low risk: <1 mm; Score 2: probably low risk between 1 and 2 mm; Score 3: probably high-risk: between 2 and 3-mm; Score 4: high-risk: >3 mm. A 2 mm threshold was used to distinguish between high-risk (Score 3 or 4) and low-risk EVs (Score 2). Cases with scores of 1 (no E.V.s) and 2 (very low-risk EVs) were assigned to a separate group.⁷

EGD:

Upper endoscopy was then done on our study cases using the Pentax Medical EG34-i10 Video Gastroscope, EGD was used as a reference for diagnosing EVs.

Grading of EVs by Endoscopy:

EVs were classified into three grades based on their size: small (low risk), medium, and large (high risk). To define high-risk varices, a cutoff point of medium size was chosen (classification of AASLD).⁸

The patients will be divided into three groups based on the results obtained by the CT; patients with no esophageal varices (score I), patients with low-risk esophageal varices (score II), and patients with high-risk esophageal varices (score III & IV). The same for EGD results, where the patients were divided into three groups: no varices, low-risk small-sized varices, and high-risk medium and large-sized varices. Then we compare the results obtained by MDCT to those obtained by endoscopy.

Statistical analysis

The Statistical Program for Social Science (SPSS) version 15.0 was used to analyse the data. The mean and S.D. were used to express quantitative data, while the frequency and percentage were used to express qualitative data.

The following tests were carried out: To compare two means, an independent-samples t-test (T) of significance was used. When comparing non-parametric data, the Chi-square test (X^2) was used. The MedCalc calculator performed a diagnostic test at https://www.medcalc.org/calc/diagnostic_test.php to determine sensitivity, specificity, PPV, NPV, and accuracy.

A P-value (probability) of less than 0.05 was regarded as significant. P-values of less than 0.001 were regarded as highly significant. P-values greater than 0.05 were regarded as insignificant

RESULTS

The study was conducted on 50 patients with liver cirrhosis due to chronic hepatitis C infection. As regards age, the mean age of all studied patients was 54.6 ± 11.5 years. As regards sex, there were 29

males (58%) and 21 females (42%) in all the studied patients.

		Type of varices				Stat. test	P-value
		Low risk (N = 14).		High risk (N = 28).			
Age (years).	Mean	57.6		54.9		T = 0.75	0.456 NS
	±SD	11.9		11.02			
Sex	Male	9	64.3%	16	57.1%	X ² = 0.19	0.567 NS
	Female	5	35.7%	12	42.9%		

Table 1: Description of age and sex of patients in relation to esophageal varices grading by endoscope. This table shows: There was no statistically significant difference (p-value > 0.05) between the type of esophageal varices by endoscope and the age and sex of patients.

		Type of varices				Stat. test	P-value
		Low risk (N = 14).		High risk (N = 28).			
Abdominal pain	No	10	71.4%	22	78.6%	X ² = 0.26	0.608 NS
	Yes	4	28.6%	6	21.4%		
Jaundice	No	8	57.1%	13	46.4%	X ² = 0.42	0.513 NS
	Yes	6	42.9%	15	53.6%		
Anorexia	No	9	64.3%	18	64.3%	X ² = 0.0	1.0 NS
	Yes	5	35.7%	10	35.7%		
Fatigue	No	5	35.7%	11	39.3%	X ² = 0.05	0.822 NS
	Yes	9	64.3%	17	60.7%		
Fever	No	14	100%	27	96.4%	X ² = 0.51	0.474 NS
	Yes	0	0%	1	3.6%		
History of hepatic encephalopathy	No	11	78.6%	22	78.6%	X ² = 0.0	1.0 NS
	Yes	3	21.4%	6	21.4%		
Weight loss	No	11	78.6%	21	75%	X ² = 0.06	0.798 NS
	Yes	3	21.4%	7	25%		
Abdominal enlargement	No	8	57.1%	13	46.4%	X ² = 0.42	0.513 NS
	Yes	6	42.9%	15	53.6%		

Table 2: Comparison between two patients' groups regarding history assessment. This table shows: There was no statistically significant difference (p-value > 0.05) between the type of esophageal varices by endoscope and the history of patients.

		Type of varices				Stat. test	P-value
		Low risk (N = 14).		High risk (N = 28).			
Pallor	No	6	42.9%	10	35.7%	X ² = 0.2	0.653 NS
	Yes	8	57.1%	18	64.3%		
Jaundice	No	8	57.1%	13	46.4%	X ² = 0.42	0.513 NS
	Yes	6	42.9%	15	53.6%		
Palmer erythema	No	6	42.9%	5	17.9%	X ² = 3.01	0.082 NS
	Yes	8	57.1%	23	82.1%		
Splenomegaly	No	6	42.9%	12	42.9%	X ² = 0.0	1.0 NS
	Yes	8	57.1%	16	57.1%		
Ascites	No	10	71.4%	17	60.7%	X ² = 0.46	0.495 NS
	Mild	0	0%	3	10.7%		
	Moderate	1	7.1%	6	21.4%		
	Tense	3	21.4%	2	7.1%		
Lower limb edema	No	10	71.4%	15	53.6%	X ² = 1.23	0.266 NS
	Yes	4	28.6%	13	46.4%		

Table 3: Comparison between two patients' groups regarding general and local examinations. This table shows: There was no statistically significant difference (p-value > 0.05) between the type of esophageal varices by endoscope and clinical examination.

		Type of varices		T	P-value
		Low risk (N = 14).	High risk (N = 28).		
Hb	Mean	9.2	9.6	0.62	0.538 NS
	±SD	2.1	1.8		
TLC	Mean	6.1	7.5	0.86	0.393 NS
	±SD	2.2	5.9		
PLTs	Mean	97.5	111.8	1.18	0.245 NS
	±SD	36.5	37.3		
ALT	Mean	29.9	33.5	0.35	0.723 NS
	±SD	19.1	35.2		
ALB	Mean	3.0	2.7	1.8	0.079 NS
	±SD	0.4	0.5		
Bilirubin total	Mean	2.2	3.1	1.5	0.129 NS
	±SD	1.1	2.2		
Bilirubin direct	Mean	0.6	1.1	1.33	0.192 NS
	±SD	0.4	1.3		
INR	Mean	1.4	1.4	0.47	0.638 NS
	±SD	0.2	0.3		
Creatine	Mean	1.2	1.1	1.02	0.310 NS
	±SD	0.2	0.3		

Table 4: Comparison between two patients' groups regarding laboratory data. This table shows: There was no statistically significant difference (p-value > 0.05) between the type of esophageal varices by endoscope with laboratory data.

		Studied patients (N = 50).	
EGD	No	8	16%
	Yes	42	84%
EGD type (n = 42%).	Low risk (small-sized varices)	14	33.3%
	High risk (medium and large-sized varices)	28	66.7%

Table 5: Description of EGD results in all studied patients. This table shows: There were no EVs in 8 patients (16%). There were EVs in 42 patients (84%), who were classified into low risk in 14 patients (33.3%) and high risk in 28 patients (66.7%).

		Studied patients (N = 50).	
CT	No (score I)	11	22%
	Yes	39	78%
CT type (n = 39%).	Low risk (score II)	11	28.2%
	High risk (score III & IV)	28	71.8%

Table 6: Description of esophageal varices by CT in all studied patients. This table shows: There were no EVs in 11 patients (22%). There were EVs in 39 patients (78%), who were classified into low risk in 11 patients (28.2%) and high risk in 28 patients (71.8%).

The ability of MDCT to identify esophageal Varices as compared to EGD was listed in (Table 7).

(n = 50).	True positive		True negative		False positive		False negative	
MDCT	39	78%	8	16%	0	0%	3	6%
	Sensitivity		Specificity		PPV		NPV	
MDCT	92.8%		100%		100%		72.7%	
	Accuracy						94%	

Table 7: Evaluation of C.T. as a screening test for E.V.s versus endoscope. This table shows: EGD detected eight negative cases, 14 cases had low-risk EVs, and 28 cases had high-risk EVs. Upper endoscopy revealed small, low risk EVs in 2 male and 1 female cases who had been misdiagnosed with no EVs by CT scan (3 false-negative patients by CT scan), The total CT sensitivity for detecting EVs was 92.8%, with 100% specificity, 100% PPV, and 72.7% NPV. When compared to the gold standard EGD, MDCT sensitivity was 78.5% in patients with low-risk EVs and 100% in cases with high-risk EVs.

		EGD (N = 42).		CT (N = 39).		X ²	P-value
Varices type	Low risk	14	33.3%	11	28.2%	0.24	0.617 NS
	High risk	28	66.7%	28	71.8%		

Table 8: Comparison between MDCT and EGD in differentiating patients with high-risk bleeding from those with low risk. This table shows: There is no statistically significant difference (p-value > 0.05) between EGD, and CT as regards varices type. Clinical and laboratory findings in patients without EVs compared with those with varices (Table 8).

		EGD results				Stat. test	P-value
		No varices (N = 8).		Varices (N = 42).			
Age (years).	Mean	48.1		55.8		MW = 97	0.061 NS
	±SD	10.9		11.2			
Sex	Male	4	50%	25	59.5%	X ² = 0.25	0.617 NS
	Female	4	50%	17	40.5%		
CHILD score	A	2	25%	6	14.3%	X ² = 2.3	0.315 NS
	B	0	0%	9	21.4%		
	C	6	75%	27	64.3%		

Table 9: shows the correlation between EDG results and other personal study data. This table shows: There was no statistically significant relation (p-value > 0.05) between EDG results in patients without EVs compared with those with varices and other studied personal data (age, sex, and CHILD score).

		EGD results				X ²	P-value
		No varices (N = 8).		Varices (N = 42).			
Abdominal pain	No	5	63%	32	76.2%	0.65	0.418 NS
	Yes	3	38%	10	23.8%		
Jaundice	No	2	25%	21	50.0%	1.69	0.193 NS
	Yes	6	75%	21	50.0%		
Anorexia	No	5	63%	27	64.3%	0.009	0.923 NS
	Yes	3	38%	15	35.7%		
Fatigue	No	1	13%	16	38.1%	1.96	0.161 NS
	Yes	7	88%	26	61.9%		
Fever	No	7	87.5%	41	97.6%	1.79	0.180 NS
	Yes	1	12.5%	1	2.4%		
Weight loss	No	6	75%	32	76.2%	0.005	0.942 NS
	Yes	2	25%	10	23.8%		
History of hepatic encephalopathy	No	7	87.5%	33	78.5%	2	0.156 NS
	Yes	1	12.5%	9	21.4%		
Abdominal enlargement	No	1	13%	21	50.0%	3.8	0.050 NS
	Yes	7	88%	21	50.0%		

Table 10: Comparison between two patients' groups regarding history assessment. This table shows: There was no statistically significant relation (p-value > 0.05) between EDG results and the history of patients.

		EGD results				X ²	P-value
		No varices (N = 8).		Varices (N = 42).			
Pallor	No	8	100%	16	38.1%	10.3	0.001 S
	Yes	0	0%	26	61.9%		
Jaundice	No	2	25%	21	50.0%	1.69	0.193 NS
	Yes	6	75%	21	50.0%		
Palmer erythema	No	3	38%	11	26.2%	0.42	0.514 NS
	Yes	5	63%	31	73.8%		
Splenomegaly	No	6	75%	18	42.9%	2.78	0.095 NS
	Yes	2	25%	24	57.1%		
Ascites	No	3	38%	27	64.3%	2	0.156 NS
	Mild	2	25%	3	7%		
	Moderate	2	25%	7	16.6%		
	Tense	1	12.5%	5	11.9%		
Lower limb edema	No	2	25%	25	59.5%	3.22	0.073 NS
	Yes	6	75%	17	40.5%		

Table 11: Comparison between two patients' groups regarding general and local examinations. This table shows: There was no statistically significant relation (p-value > 0.05) between EDG results and clinical examination except pallor; there was a statistically significant difference (p-value = 0.001) as there was an increased percentage of pallor (26 patients, 61.9%) in patients with varices when compared with patients with no varices (0 patient, 0%).

		EGD results		MW	P-value
		No varices (N = 8).	Varices (N = 42).		
Hb	Mean	11.5	9.5	65	0.005 S
	±SD	0.5	1.9		
TLC	Mean	6.6	7.0	135	0.397 NS
	±SD	2.1	5.0		
PLTs	Mean	127.5	107.0	157	0.785 NS
	±SD	86.3	37.2		
ALT	Mean	30.0	32.3	161	0.866 NS
	±SD	28.6	30.6		
ALB	Mean	2.9	2.8	153	0.707 NS
	±SD	0.6	0.5		
Bilirubin Total	Mean	3.4	2.8	127	0.290 NS
	±SD	1.9	1.9		
Bilirubin Direct	Mean	1.3	0.9	145	0.694 NS
	±SD	1.1	1.1		
INR	Mean	1.5	1.4	108	0.117 NS
	±SD	0.2	0.3		
Create	Mean	1.3	1.1	95	0.054 NS
	±SD	0.2	0.3		

Table 12: Comparison between two patients' groups regarding laboratory data. This table shows: There was no statistically significant relation (p -value > 0.05) between EDG results and studied laboratory data except Hb; there was a statistically significant difference (p -value = 0.005) as there was increased anemia (9.5 ± 1.9) in patients with varices when compared with patients with no varices (11.5 ± 0.5).

		EGD results				X2	P-value
		No varices (N = 8).		Varices (N = 42).			
PEV	No	4	50%	28	66.7%	0.81	0.368 NS
	Yes	4	50%	14	33.3%		
PVT	No	7	88%	37	88.1%	0.002	0.962 NS
	Yes	1	13%	5	11.9%		
HCC	No	6	75%	33	78.6%	0.05	0.823 NS
	Yes	2	25%	9	21.4%		
Splenomegaly	No	5	63%	11	26.2%	4.07	0.044 S
	Yes	3	38%	31	73.8%		
Splenic collaterals	No	4	50%	26	61.9%	0.39	0.529 NS
	Yes	4	50%	16	38.1%		
Gall bladder stones	No	8	100%	33	78.6%	2.09	0.148 NS
	Yes	0	0%	9	21.4%		
Ascites	No	2	25%	22	52.4%	2.01	0.155 NS
	Yes	6	75%	20	47.6%		
Gastric varices	No	8	100%	40	95.2%	0.39	0.529 NS
	Yes	0	0%	2	4.8%		

Table 13: Comparison between two patients' groups regarding extraesophageal CT findings. This table shows: There was no statistically significant relation (p -value > 0.05) between EDG results and extra-esophageal findings except splenomegaly; there was a statistically significant difference (p -value = 0.044) as there was an increased percentage of splenomegaly (31 patients, 73.8%) in patients with varices when compared with patients with no varices (3 patients, 38%).

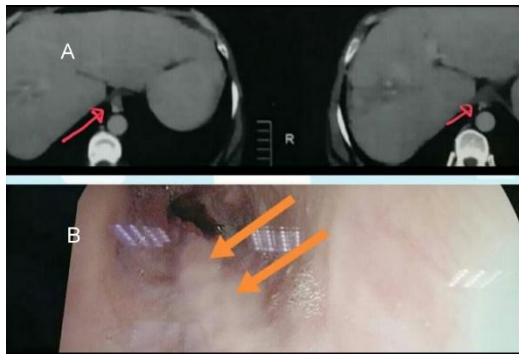
Case 1:

Fig 1: CT section of the lower esophagus, picture (A) showing a low-risk varix; picture (B) the same patient's endoscopic picture showing a small-sized low-risk varix.

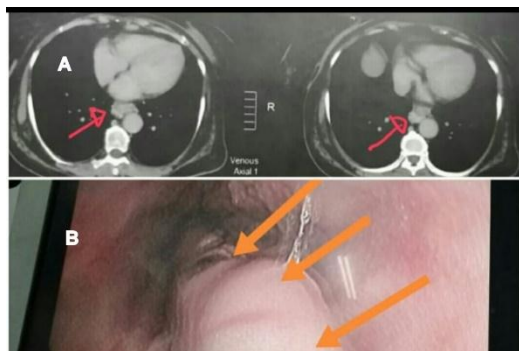
Case 2:

Fig 2: CT section of the lower esophagus, picture (A) showing a high-risk varix; Picture (B) showing the same patient's endoscopic picture showing a large-sized high-risk varix.

DISCUSSION

EGD is routinely performed in cirrhotic patients to evaluate EVs and prevent life-threatening EVs bleeding.⁹

Screening is recommended yearly for cases with non-risky EVs and every 2-3 years in cases with no varices to allow for the start of primary prophylactic treatment; As a result, many cirrhotic patients are subjected to unnecessary endoscopic examinations.¹⁰

Because pain, anxiety, choking, and abdominal pain are very common, and severe complications of EGD have been documented in 0.05 percent of patients, in addition to the procedure's cost, endoscopy appears to require a non-invasive alternative.^{11&12}

MDCT is considered a less invasive, less expensive, and better tolerated screening tool with high sensitivity and specificity for diagnosing risky EVs would allow for a more accurate selection of cases for endoscopic intervention on risky EVs.¹³

The aim of the present study is to evaluate the use of contrast enhanced MDCT to detect EVs and differentiate between EVs at low risk and those at high risk for bleeding in comparison with the endoscope as the gold standard.

The 50 cases presented with a variable range of symptoms related to their chronic liver disease and its complications (such as HCC and portal HTN). The most common symptom was fatigue, which was present in 66% of the patients. by abdominal enlargement (56%).

Cases were classified into three groups based on CT findings: group I: 11 cases without EVs (22%) (SCORE I), consisting of six males and five females; group II: 11 cases with low-risk EVs (22%) (SCORE II), consisting of seven males and four females; and group III: 28 cases with high-risk EVs (56%) (SCORE III & IV), consisting of 16 males and 12 females.

While the EGD findings were as follows: Group I (no varices) includes eight cases with no EVs (16%), consisting of four males and four females. Group II (low-risk varices) includes 14 cases with small-sized EVs (28%), consisting of nine males and five females. Group III (high-risk group): including medium and large-sized EVs, was detected in 28 cases (56%), consisting of 16 males and 12 females.

Upper endoscopy revealed small, low-risk EVs in two male and one female patients who had been misdiagnosed with no EVs by C.T. scan (3 false-negative patients). False negative cases can be attributed to a variety of factors. First, small EVs are presumably more prone to hemodynamic and respiratory factors. Second, small enhancing EVs almost embedded in the esophageal wall can be difficult to detect because the wall itself enhances to varying degrees.

The total CT sensitivity for detecting EVs was 92.8%, with 100% specificity, 100% PPV, and a 72.7% NPV. When compared to the gold standard EGD, MDCT sensitivity was 78.5% in patients with low-risk EVs (Group II), and 100% in cases with high-risk EVs (Group III).

This result agrees with Moftah et al.,¹⁴ who found that the overall CT sensitivity was (96%), specificity (100%), compared to the gold EGD. The CT sensitivity between patients with low-risk E.V.s was 94.12%, compared to 100% among patients with high-risk EVs. Deng et al.,¹⁵ also used the conventional triphasic CT protocol. The results revealed sensitivity and specificity (95.56%) and (71.43%), respectively. While Yu et al.,⁷ had a sensitivity of 96%. Dessouky et al.,¹⁶ found that the sensitivity, specificity, PPV, NPV, and accuracy of MDCT for diagnosing EVs in all grades were 99.5%, 99.6%, 99.4%, 99.5%, and 99.5%, respectively. Yara et al.,¹⁷ found that CT sensitivity for EVs detection was 96.7%, specificity 100%, PPV 100%, and NPV 66.7%. The CT sensitivity for high-risk EV (100%) was higher than that for low-risk EVs (92.3%).

In our study, para esophageal varices were found in 18 patients (36%); 13 of them (72.2%) had high-risk EVs, while five patients had low-risk E.V.s (27.8%), which reflects the importance of detection of para esophageal varices. This result agrees with Moftah et al.,¹⁴ study, which found that para esophageal varices were detected in 18.5% of patients.

Portal vein thrombosis was detected in 12% of patients. This result agrees with Moftah et al.,¹⁴ who found that PV thrombosis was detected in 9% of patients. Although P.V.T. may have increased the high-risk EV group by raising portal hypertension.¹⁸ In those cases, there was no statistical difference between the low-risk and high-risk EVs.

HCC is a common and major complication of cirrhosis.¹⁹ In our study, 11 (22%) were diagnosed to have HCC, four of them were previously diagnosed, and seven cases were first discovered. While in the Moftah et al.,¹⁴ study, HCC was in 33 (61%) of patients.

There was no statistically significant relation (p-value > 0.05) between EDG results in patients without EVs compared with those with varices and other studied personal data (age, sex, and CHILD score).

There was no statistically significant relation (p-value > 0.05) between EDG results in patients without EVs compared with those with varices regarding history assessment and clinical examination except pallor (p-value = 0.001). Also, there was no statistically significant relation (p-value > 0.05) between EDG results and studied laboratory data except for Hb (p-value = 0.005).

There was no statistically significant relationship (p-value > 0.05) between EDG results in patients without EVs compared with those with varices and extra-esophageal findings except splenomegaly (p-value = 0.044).

According to our results no statistically significant difference in patients distribution of age, sex, clinical and laboratory findings between patients with low and high-risk EVs.

There was a strong correlation and agreement between the endoscopic and CT grading of EVs. As a result, MDCT is a good alternative diagnostic tool to traditional diagnostic EGD for screening EVs and grading their risk of bleeding in cirrhotic patients.

There is a limitation for MDCT as compared to EGD findings, including the presence of red signs, which is one of the predictors of EV bleeding. However, red signs are rarely seen in patients with low-risk esophageal varices.

CONCLUSION

EGD is still the gold standard in EV diagnosis and therapy. Triphasic CT abdomen is an excellent

noninvasive alternative tool for detecting and grading EVs. Good compliance with CT scanning compared to endoscopy allows better results in surveillance and early detection of varices, so better prognosis. The CT scan reduces the overuse of diagnostic endoscopy, saves its cost for therapy, and evaluates other items that cannot be evaluated by endoscopy.

REFERENCES

1. Tripathi D, Stanley A, Hayes P, et al. UK guidelines on the management of variceal haemorrhage in cirrhotic patients. *Gut*. 2015;64(11):1680-704.
2. Garcia Tsao G, Abraldes J, Berzigotti A, et al. Portal hypertensive bleeding in cirrhosis: Risk stratification, diagnosis, and management: 2016 practice guidance by the American Association for the study of liver diseases. *Hepatology*. 2016;65(1):310-35.
3. Perri R, Chiorean M, Fidler J, et al. A prospective evaluation of computerized tomographic (CT) scanning as a screening modality for esophageal varices. *Hepatology*. 2008;47(5):1587-94.
4. Chakrabarti R, Sen D, Khanna V. Is non-invasive diagnosis of esophageal varices in patients with compensated hepatic cirrhosis possible by duplex Doppler ultrasonography? *Indian Journal of Gastroenterology*. 2016;35(1):60-66.
5. Kim H, Choi D, Gwak G, Lee J, Park M, Lee H et al. Evaluation of esophageal varices on liver computed tomography: Receiver operating characteristic analyses of the performance of radiologists and endoscopists. *Journal of Gastroenterology and Hepatology*. 2009;24(9):1534-1540.
6. Kim H. High-risk esophageal varices in patients treated with locoregional therapy for hepatocellular carcinoma: Assessment with liver computed tomography. *World Journal of Gastroenterology*. 2012;18(35):4905.
7. Yu N, Margolis D, Hsu M, Raman S, Lu D. Detection and Grading of Esophageal Varices on Liver CT: Comparison of Standard and Thin-Section Multiplanar Reconstructions in Diagnostic Accuracy. *American Journal of Roentgenology*. 2011;197(3):643-649.
8. Macedo G. Reliability in endoscopic diagnosis of portal hypertensive gastropathy. *World Journal of Gastrointestinal Endoscopy*. 2013;5(7):323.
9. Elwakil R, Al Breedy A, Gabal H. Effect of endoscopic variceal obliteration by band ligation on portal hypertensive gastro-duodenopathy: endoscopic and pathological study. *Hepatology International*. 2016;10(6):965-973.
10. Maurice J, Brodtkin E, Arnold F, Navaratnam A, Paine H, Khawar S et al. Validation of the Baveno VI criteria to identify low risk cirrhotic patients not requiring endoscopic surveillance for varices. *Journal of Hepatology*. 2016;65(5):899-905.
11. Ben-Menachem T, Decker G, Early D, Evans J, Fanelli R, Fisher D et al. Adverse events of upper GI endoscopy. *Gastrointestinal Endoscopy*. 2012;76(4):707-718.

12. Amornyotin S. Sedation-related complications in gastrointestinal endoscopy. *World Journal of Gastrointestinal Endoscopy*. 2013;5(11):527.
13. Tseng Y, Zeng X, Chen J, Li N, Xu P, Chen S. Computed tomography in evaluating gastroesophageal varices in patients with portal hypertension: A meta-analysis. *Digestive and Liver Disease*. 2016;48(7):695-702.
14. Mofteh S, Kamal S, Hanna A. CT esophagography: Noninvasive screening and grading of esophageal varices in cirrhosis. *The Egyptian Journal of Radiology and Nuclear Medicine*. 2014;45(2):263-270.
15. Deng H, Qi X, Zhang Y, Peng Y, Li J, Guo X. Diagnostic accuracy of contrast-enhanced computed tomography for esophageal varices in liver cirrhosis: a retrospective observational study. *Journal of Evidence-Based Medicine*. 2017;10(1):46-52.
16. Dessouky B, Abdel Aal E. Multidetector CT oesophagography: An alternative screening method for endoscopic diagnosis of oesophageal varices and bleeding risk. *Arab Journal of Gastroenterology*. 2013;14(3):99-108.
17. Yara Youssef, Mahmoud. Role of contrast enhanced Computed Tomography in detection and grading of Esophageal Varices in patients with liver cirrhosis. *Zagazig University Medical Journal*. 2018;23(6).
18. Lin, G. S et al. Clinical features of liver cirrhosis complicated by portal vein thrombosis and related risk factors. *Chinese journal of hepatology*. 2016;24(7): 513-517.
19. Balogh J, Victor D, Asham E, Burroughs S, Boktour M, Saharia A et al. Hepatocellular carcinoma: a review. *Journal of Hepatocellular Carcinoma*. 2016; Volume 3:41-53.