



3-1-2022

Inverted V-Y and fibrofatty Flap technique for columellar lengthening and tip augmentation in adults post bilateral cleft lip nasal deformity

Mohamed Khalifa

Plastic surgery and burn department, Faculty Of Medicine Al Azhar University,
mohamedhosny.6@azhar.edu.eg

Follow this and additional works at: <https://aimj.researchcommons.org/journal>



Part of the [Medical Sciences Commons](#), [Obstetrics and Gynecology Commons](#), and the [Surgery Commons](#)

How to Cite This Article

Khalifa, Mohamed (2022) "Inverted V-Y and fibrofatty Flap technique for columellar lengthening and tip augmentation in adults post bilateral cleft lip nasal deformity," *Al-Azhar International Medical Journal*: Vol. 3: Iss. 3, Article 4.

DOI: <https://doi.org/10.21608/aimj.2022.123217.1848>

This Case Series is brought to you for free and open access by Al-Azhar International Medical Journal. It has been accepted for inclusion in Al-Azhar International Medical Journal by an authorized editor of Al-Azhar International Medical Journal. For more information, please contact dryasserhelmy@gmail.com.

Inverted V-Y And Fibrofatty Flap Technique For Columellar Lengthening And Tip Augmentation In Adults Post Bilateral Cleft Lip Nasal Deformity

Mohammed Hossni, ¹ MD.

** Corresponding Author:*

Mohammed Hossni

mohamedhosny.6@azhar.edu.eg

Received for publication February 23, 2022; Accepted March 19, 2022; Published online March 19, 2022.

Copyright The Authors published by Al-Azhar University, Faculty of Medicine, Cairo, Egypt. Users have the right to read, download, copy, distribute, print, search, or link to the full texts of articles under the following conditions: Creative Commons Attribution-Share Alike 4.0 International Public License (CC BY-SA 4.0).

doi: 10.21608/aimj.2022.123217.1848

¹Plastic Surgery Department, Faculty of Medicine, Al-Azhar University, Cairo, Egypt.

ABSTRACT

Background: Short columella and dropped tip are frequent finding in the cleft lip nasal deformity. Many techniques have been utilized to correct these deformities.

Aim of the study: This study proposes a novel inverted incision and fibrofatty flap technique for Columellar lengthening and more tip definition.

Patients and Methods: a case series study. That evaluates the safety and outcome off this technique.

Results: Functional and aesthetic outcomes were highly improved with the proposed technique. Confidence interval reached 98%.

Conclusion: the proposed technique could be a reliable and valuable alternative tool to improve in bilateral cleft lip nasal deformity associated depressed tip and short columella.

Keywords: Deformity; Post Cleft lip; inverted VY; proposed technique

Disclosure: The author has no financial interest to declare in relation to the content of this article. The Article Processing Charge was paid for by the authors.

Authorship: The author has a substantial contribution to the article.

INTRODUCTION

Bilateral cleft lip nasal deformity is a complex presentation that interferes with the child respiration, feeding, growth and speech. Early surgery is required to minimize the post cleft lip nasal deformity complications.¹ However, with best hands usually, there are somewhat of nasal deformities presented after puberty² that affects patient social integration and may limit nasal function. Short columella and the short depressed nasal tip are the common features in post cleft lip nasal deformities.³ Moreover, many associated deformities could be present like flared wide ala, disturbed external nasal valve, disturbed nasal facial aesthetic angles of the nose e.g., columello-labial, and nasolabial angles.⁴ Lower lateral cartilage shows lateral displacement of the domes on both sides with diversion away from the middle septum.⁵

Although, the literature shows many different techniques to overcome these unpleasant presentations, but tissue deficiencies and scars' contractions are usually challenging problems are facing the surgeons during design for reconstruction.⁶

This study proposes Inverted v-y incision and fibrofatty Flap technique for columellar lengthening and tip augmentation in post bilateral cleft lip nasal deformity. Study also evaluates the safety and outcome of this technique.

MATERIALS AND METHODS

This is a case series preliminary study that includes 8 patients (2 female, and 6 male) were presented with post bilateral cleft lip nasal deformity. This study was conducted as a university-based practice in a period from January 2017 to 2020. The age of the patients ranged from 16 to 27 years old. The functional and aesthetic outcomes were evaluated by an objective assessment.

Postoperative complications such as wound dehiscence, infection, hematoma, partial or total flap loss were reported during the follow up.

A nasal obstructive symptom rating scale was used to measure nasal function both subjectively and objectively (NOSE).⁷ Analyzed factors included difficulty breathing via the nose and difficulty sleeping, as well as difficulties in inhaling air through the nose during exercising and effort. A linear symptom rating scale was used to assess overall breathing difficulties both before and after surgery.

Objective aesthetic assessments included two independent board-certified plastic surgeons and digital photography. The analysis included frontal, lateral, oblique, and basal profiles. (Table1) The aesthetic analysis of the nasal profile was performed

with the following angles and landmarks (Figure 1A, B)

Nasofrontal angle, the dorsal aesthetic line, nasal facial angle, naso-mental angle, nose to chin angle, pre-nasale, columella peak, sub-nasale, and alar curvature points. Basal nasal profiles were evaluated with the columellar height in term of the ratio of columellar height to nasal height, the ratio of columellar height to alar base width. Columellar height is (columella peak to the subnasale), the ratio of columellar height to nasal height (the pronasale to the subnasale), the ratio of columellar height to alar base (distance between alar curvature points).

The measurements were achieved with the aid of digital photography of the different nasal profile views, pre-operative, intra operative, 3 weeks postoperative and at 6th months follow up.

Subjective questionnaire for degrees of the improvement of the air entry and overall satisfaction of the patients was also reported in terms of mild moderate and marked improvement/ satisfaction (Table 2). Statistical analysis of the data was used to determine the confidence interval and the probability of the proposed alternative technique hypothesis and P-value significance using SSS package system. In this study the degree of statistical significance depends on the level of significance. If p-value is more than 0.05 is considered statistically significant while less than 0.01 is a highly statistically significant.

The paired Student's t-test was used to compare preoperative and postoperative continuous variables. (Measurements and angles).

Informed patients' consents and institutional ethical approval were obtained.

Surgical techniques

Five patients underwent local anesthesia with sedation and three patients underwent general anesthesia. 2% lidocaine in a 1:100,000 epinephrine solution was frequently injected into the dorsum of the nose, the nasal tip, and along the columellar tissue to ensure appropriate hemostasis. The nasal tamponade is then inserted into the nose.

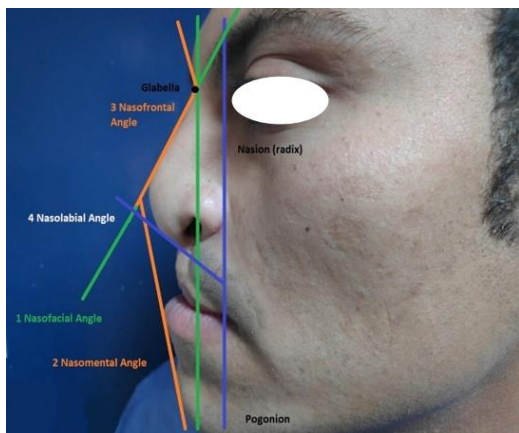


Fig. 1 a: Angles and landmarks which used as pre-operative basics in the objective assessment: Nasofrontal angle, the dorsal aesthetic line, nasal facial angle, naso-mental angle (nose to chin angle),

pre-nasale, columella peak, sub-nasale and alar curvature points.

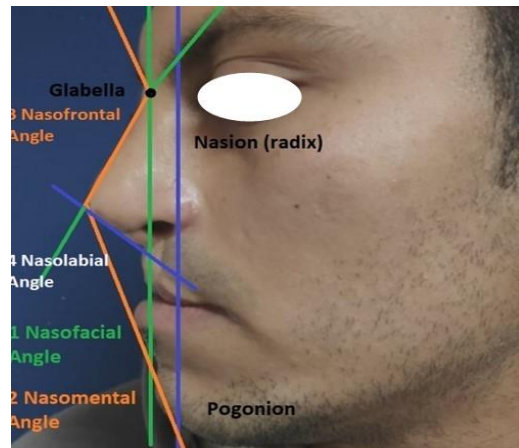


Fig. 1 b: Same angles and landmarks in post-operative objective assessment.

Incision: Open rhinoplasty with inverted V-columellar incision started in infra lobular area to steel skin from the tip towards the deficient Columella (Figure 2). The incisions in the infra-lobule area are continued till fuse with rim incisions to complete open approach (Figure 3). Then subcutaneous dissection of the skin of the tip is continued laterality and cephalic till complete exposure of the tip. Gentle dissection and caution are practiced preserving fibrofatty tissue. Fibrofatty tissue is randomly elevated, and the flap remains attached and based caudally to preserve blood supply (Figure 4).

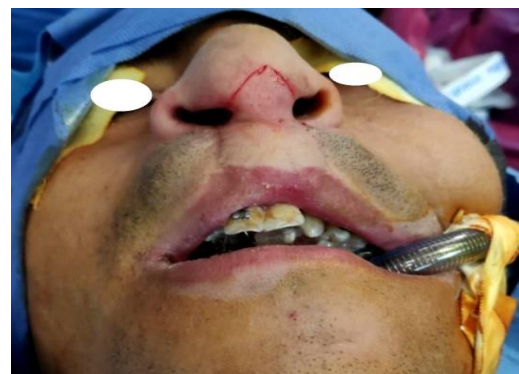

Fig. 2: shows an inverted V- columellar incision started in infra lobular area.

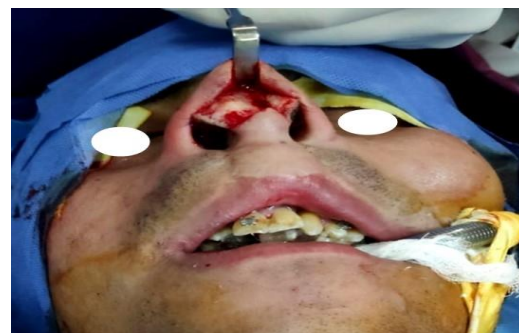

Fig. 3: shows the incisions in the infra-lobule area that were continued till fused with the rim incisions to complete the open approach.

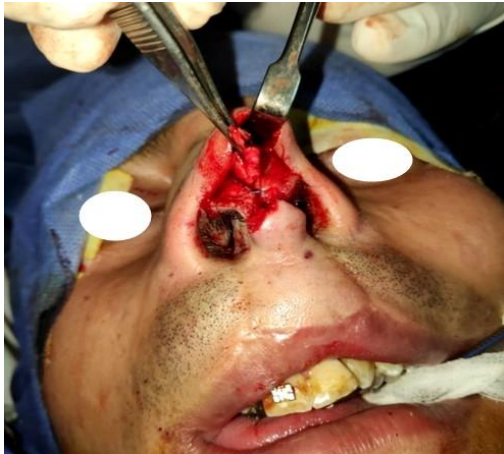

Figure 4: shows a fibrofatty tissue was elevated and the flap remained attached randomly and based caudally to preserve blood supply. Also, it shows the medial crura suture that were carried on as usual. Then the fibrofatty flap was ready to be turned on towards the columellar base.

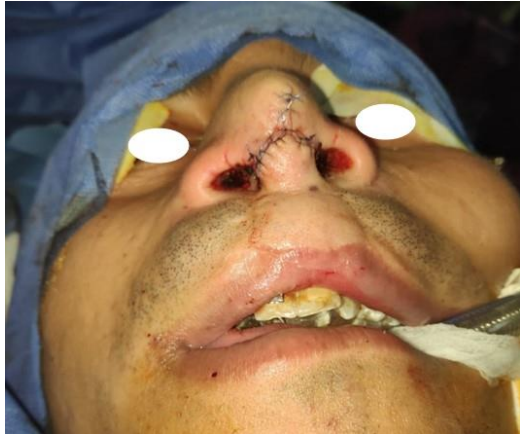

Figure 5: shows that the incised V was closed in Y manner to address the final shape of the nose after tip definition and columellar lengthening.

Sliding, suturing, and reshaping of the medial crura of lower lateral cartilage in both sides achieved to give a cartilaginous columellar length. Inter-domal suture was carried on as usual. Then the fibrofatty flap is turned over towards the columellar base, giving a bulge that enhances the infra tip lobule and gives the sloping shape of infra tip area as well as it modulates up the depressed tip. Then closure of the

V in Y manner to address the final shape of the nose after tip definition and columellar lengthening (Figure 5). Lastly alar reduction, then the skin is finally closed by proline 6-0 and the internal nasal mucosa is closed by Vicryl 5/0. No nasal back is usually needed but splint for one week to minimize oedema and for protection.

Post-operative antibiotic Augmentin (825 amoxicillin, 125 mg clavulanic acid) twice daily, anti-edematous (Chymotrypsin) and nonsteroidal anti-inflammatory drug (NSAID) as analgesic used for one week.

Later, CO₂ laser was done after three weeks of operations and continuous every month for 2-4 sessions for more improvement of the scar. A fractional CO₂ laser was done after three weeks of operations and continuous every month for 2-4 sessions was used with irradiation parameters set as follows: output power 10 W, pulse width 600 μ s, dot spacing 800 μ m, and stack 2 (irradiation output power 0.91 J/cm²) for more improvement of the scar.

RESULTS

During the 6-month follow up, there were no problems such as wound dehiscence or infection, hematoma, partial or entire flap loss in any of the patients. A two-day hospital stay was the average.

The scars were inconspicuous at 6th months follow up, and no scar contracture was seen in the late postoperative period. (Figures 6-9)

In accordance with this study's results, functionally all patients have completed the nasal obstructive symptoms evaluation scale and the linear symptom evaluation scale pre- and post-operative showed improvement of the respiration (Table 3). Objective aesthetic assessments of Facial angles and nasal facial landmarks (Figure 1A, B) showed marked improvement of the columellar height in relation to the nasal height in all cases. The dropped nasal tip has been improved in all cases with near normal projection. Confidence interval showed that more than 98% improvement in both functional and aesthetic outcomes. Most patients were most satisfied with their postoperative results when measured by the visual analogue scale (VAS), with the dorsum, uneven alar bases, and the nostril coming in close behind. Each of the patients was happy with the results of the procedure, and several even said they would have it done again in the future if required.

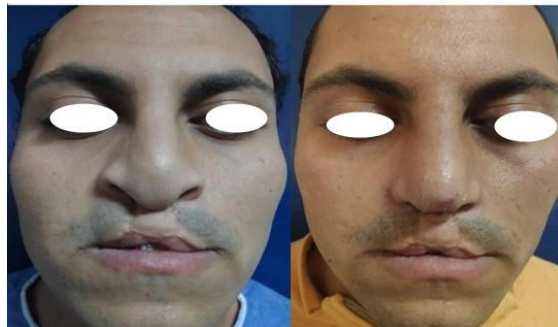

Fig. 6: 26 years old male patient presented by post bilateral cleft nasal deformity. Pre and 12 months post-operative submission to the proposed technique. Front views.

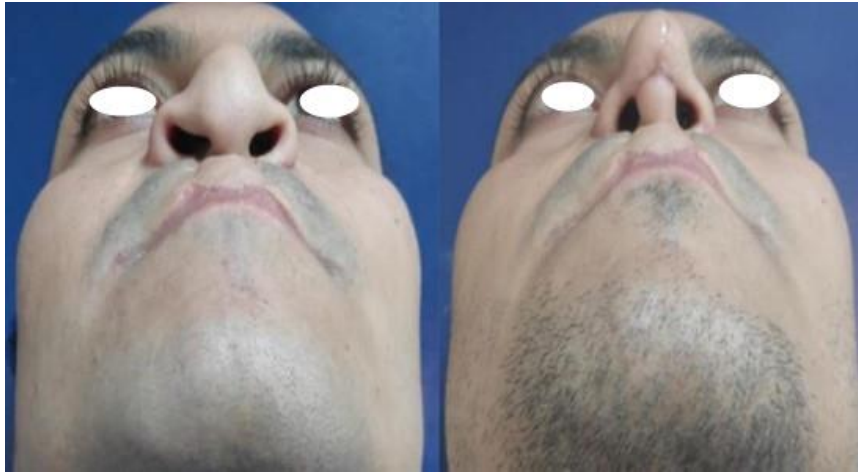

Fig. 7: 26 years old male patient presented by post bilateral cleft nasal deformity. Pre and 12 months post-operative submission to the proposed technique. Basal views.

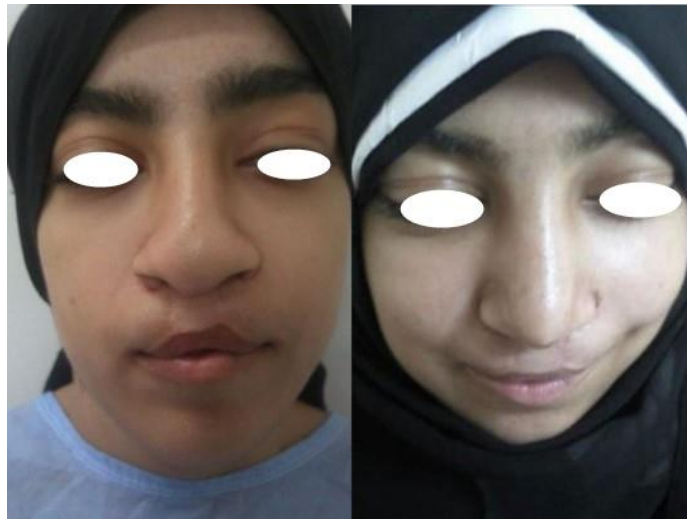

Fig. 8: 18 years old female patient presented by post bilateral cleft nasal deformity. Pre and 6 months post-operative submission to the proposed technique. Frontal views.

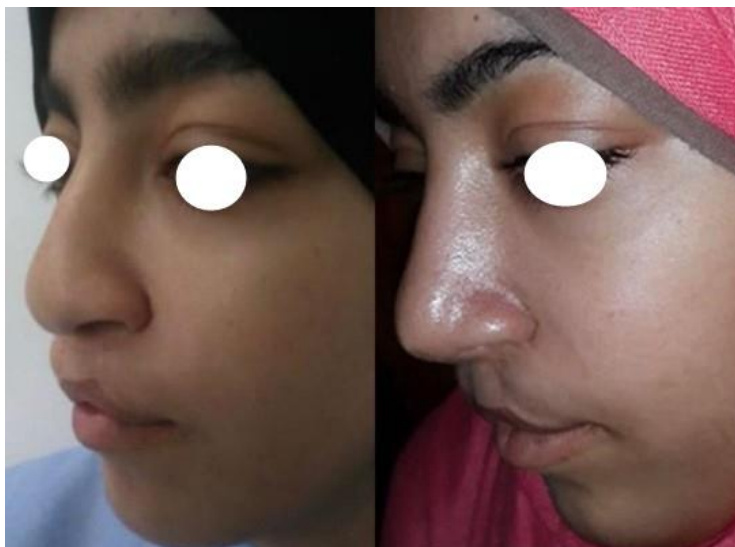

Fig. 9: 18 years old female patient presented by post bilateral cleft nasal deformity. Pre and 6 months post-operative submission to the proposed technique. Lateral views.

The most improved anatomical sites after operation	Worse	Unremarkable	Satisfactory	Good	Excellent
Nasal symmetry	-	-	1	2	5
Nasal tip	-	-	-	1	7
Dorsum of nose	-	-	1	3	4
Nasal alae	-	-	-	2	6
Nasal apertures	-	-	1	2	5

Table 1: Objective aesthetic assessments included two independent board-certified plastic surgeons and digital photography.

Gender	No. of patients	Degree of satisfaction		
		good	fair	poor
Male	6	5	1	-
Female	2	2	-	-

Table 2: Patients and parents' satisfaction were good in 7 out of 8 cases.

Symptoms	Case 1		Case 2		Case 3		Case 4		Case 5		Case 6		Case 7		Case 8	
	Pre	Post	Pre	Post	Pre	Post	Pre	Post	Pre	Post	Pre	Post	Pre	Post	Pre	Post
Pre and post Operative																
Nasal congestion	2	1	4	2	3	1	2	1	2	0	2	0	3	2	4	1
Nasal obstructiveness	3	1	3	1	2	2	1	0	1	0	2	0	2	1	3	0
Troublesome breathing through nose	2	1	1	0	1	0	2	0	2	1	3	1	2	2	1	0
Troublesome sleeping	4	2	4	2	4	2	3	1	2	0	3	1	4	1	2	0
Problem while inhaling air through nose while exercising and exertion.	3	0	2	0	3	1	3	0	3	0	2	0	3	0	2	1

Table 3: Functional analysis of outcome after proposed technique that includes rhinoplasty nasal congestion or stuffiness, nasal blockage or obstructiveness, troublesome breathing through nose, troublesome sleeping and problem while inhaling air through nose while exercising and exertion.

DISCUSSION

The management of cleft lip nose considers a stigma to the cleft lip patient.⁸ It is important for these patients to receive not only a functional correction but also aesthetic restoration of the external nose to camouflage the patient's facial disfigurement.⁹ According to Toriumi,¹⁰ nasal tip setting, and reposition begin with stabilization of the nasal base. Columella is one of the nasal tip concretes is usually deficient in post cleft lip nasal deformity and has an aesthetic and functional defiance.¹⁰

Author explained the technique in detail as it differs totally from other techniques in tackling the one of the main problems in post bilateral cleft lip nasal deformity. The short columella was lengthened by Y-V non scarred skin, as well as recycling the fibrofatty tissue to support the tip without strut and compared study results with all other techniques. Fibrofatty technique is simply the use of fibrofatty tissue based distally to augment the tip without cartilaginous no donor site morbidity and less lengthy operation.

In this preliminary study findings, more than 98% of the patients had a significant improvement in their visual analogue scale (VAS) ratings at the nasal tip,

followed by the dorsum, uneven alar bases and the nostril.

Many techniques¹¹ have been described for post bilateral cleft lip nose. Authors discussed results and advantages of their techniques. Tajima and Maruyama¹² described a reverse-U incision combined with a suture suspension of the repositioned cleft lower lateral cartilage. Their technique agrees with this study regards the management of LLC but depends mainly on the skin of short banked forked flap for columellar lengthening. However, this study describes a technique that steals skin from broad infra nasal tip lobule to length the columella and project the tip.

William et al.¹³ described L- shape strut using costal cartilage graft for post cleft lip patients' and showed a good result but added more donor site scars. However, this proposed technique recycles the fibrofatty tissue to elevate the tip, and the technique is simple, easier with no donor site morbidity.

Yilmaz et al.¹⁴ used iliac bone graft but reported many complications in patients with post bilateral cleft lip nose. They reported wound dehiscence over the trans-columellar incisions and displacement of dorsum on lay graft in such cases as well as donor site scar. This study technique does not utilize a

cartilaginous tissue grafting but used the fibrofatty tissue to add tip definition.

Nakajima et al.,¹⁵ adjusted a procedure that adds a Z-plasty in the lateral nasal vestibule repair the alar-columellar web and avoid vestibular region tightness was modified. Also, they utilize the muco-chondrial flap but reported a problem of insufficient elongation of the columella that leads to tip dropping later. In this study follow up did not report a tip drop after 24th months and results showed that, fibrofatty flap is enough for tip definition in post cleft nasal deformity. However longer follow up and wider scale studies are required.

Cronin and Denkler¹⁶ described V-Y plasty of the nasal mucosa and advancement of the lateral crus. This study proposes an inverted V-Y (inverted V incision and Y closure) that steals from the characteristic wide skin over bulbed infra-tip in post cleft lip and palate deformity.

Furthermore, Maeda et al.¹⁷ described Secondary reconstruction of cleft lip or nasal deformity with a bilateral reverse-U incision, however Nakajima and Yoshimura also employed a bilateral reverse-U incision paired with a short banked forked flap.

The Abbé flap¹⁸ also has been introduced to correct the secondary deformity of bilateral cleft lip nasal deformity. The Abbé flap gives more skin and could be safely and effectively correct the upper lip skin shortage of the pro-libuim.

However, Abbé flap¹⁸ has a marked donor site affection postoperatively when compared with this proposed technique. Furthermore, many of the above-mentioned techniques have the disadvantages of adding more scars to the lip, later contraction in addition to the marked dissection which may affect nasal ligaments and leads to functional problems.

Simply, in this study authors used the skin from the broad ill-defined nasal tip to elongate the columella by inverted V-Y flap. This technique gives more skin to the columella and the fibrofatty tissue augments the tip. There-after the alar cartilage repositioned and sutured. Although in this study the cases' number is small, this study could have a promising preliminary conclusion.

Interestingly, according to the findings in this proposed technique there is no need for columellar strut. Furthermore, fibrofatty flap was enough for tip support and definition. Fibrofatty tissue is highly vascular and versatile that does not collapse, and the tip did not show a re-drop up to 2 years follow up.

Functionally, Nasal function in this study has been measured by nasal obstruction symptoms evaluation scale. Cartilage re-orientation and suture reposition improved the breathing by restoring the external nasal valve configuration.

Author re-oriented the cartilage but without cartilage grafting, just depended on the inverted y-v to give ample skin coverage for the fibrofatty flap.

This paper suggests the use of an inverted V to Y incision in the nasal tip allowing open access for the

usual bilateral cleft rhinoplasty. This is an inversion of Harold McComb's V to Y of the nasal tip in his primary bilateral cleft rhinoplasty.^{19,20}

Harolds prefer bilat Tajimas with an open rhinoplasty and strong cartilage grafts to shape the tip and stretch the defatted skin. This avoids the visible scars that are the major drawback of this technique. The major advantage of the authors technique over his one, is that the V to Y elongates the skin distance from the radix to the lip columella junction, so there is less tension and strong cartilage grafts are not necessary. This would result in a softer tip reconstruction at the expense of the visible tip scars.

In this study objective aesthetic assessments, showed marked improvement of the columellar height compared to the nasal height in all cases. The dropped nasal tip has been improved in all cases with near normal projection. All of the patients were pleased with the results of the operation, and several even said they would have it done again if required. The patient and parent satisfactions regard functional and aesthetic jobs were mild to marked in all cases. Every day there are many ideas and innovations regarding precise job in rhinoplasty,²¹ aesthetic surgery²² and reconstructive surgery.^{23,24} That includes nasal reconstruction,²³ cleft lip and palate nasal deformity²⁵ regarding appearance,²⁶ function, respiratory problems²⁷ and skeletal maturation²⁸ which are still points of research that shows a flow of ideas and innovations.

CONCLUSION

This Preliminary study proposes a technique that could be a reliable and valuable alternative tool to improve the depressed tip and short columella in bilateral cleft lip nasal deformity.

REFERENCES

- 1- Fisher, D. M., and Mann, R. J. A model for the cleft lip nasal deformity. *Plast. Reconstr. Surg.* 101: 1448, 1998.
- 2- Randall, P. History of cleft lip nasal repair. *Cleft Palate Craniofac. J.* 29: 527, 1992.
- 3- Stal S and Hollier L. Correction of secondary deformities of the cleft lip nose. *Plast Reconstr Surg.* 2002; 109:1386-92.
- 4- Jackson IT. Repair of secondary cleft lip and nose deformities. In: McCarthy JG Current therapy in plastic Surgery, 1st ed, Vol. 11. Philadelphia: Saunders Elsevier; 2006. p.458-61.
- 5- Allen L. and et al. Cleft Rhinoplasty *Plast. Reconstr. Surg* September 15, 2004.
- 6- Farrior, R. T. The cleft lip nose: An update. *Facial Plast. Surg.* 9: 241, 1993.
- 7- Spiekermann, C., Savvas, E., Rudack, C. et al. Adaption and validation of the nasal obstruction symptom evaluation scale in German language (D-NOSE). *Health Qual Life Outcomes* 16, 172 2018: <https://doi.org/10.1186/s12955-018-1004-x>

- 8- Mulliken, J. B. Correction of the bilateral cleft lip nasal deformity: Evolution of a surgical concept. *Cleft Palate Craniofac. J.* 29: 540, 1992.
- 9- Cutting CB. Secondary cleft lip nasal reconstruction: State of the art. *Cleft Palat Craniofac J.* 2000; 37:538-40.
- 10- Toriumi DM. Nasal Tip Contouring: Anatomic Basis for Management. *Facial Plast Surg Aesthet Med.* 2020 Jan/Feb;22(1):10-24. doi: 10.1089/fpsam.2019.29006.tor. PMID: 32053427.
- 11- Celik, M., and Tuncer, S. Nasal reconstruction using both cranial bone and ear cartilage. *Plast. Reconstr. Surg.* 105: 1624, 2000.
- 12- Tajima S, Maruyama M. Reverse-U incision for secondary repair of cleft lip nose. *Plast. Reconstr. Surg.* 1977; 60:256-61.
- 13- Yoav Kaufman, MD1 Edward P. Buchanan, MD1 Erik M. Wolfswinkel, BS2 William M. Weathers, MD1 Samuel Stal, MD1 Cleft Nasal Deformity and Rhinoplasty *Semin Plast Surg* 2012;26:184–190.
- 14- M. Yilmaz, H. Vayvada, A. Menderes, F. Mola, and A. Atabey, "Dorsal nasal augmentation with rib cartilage graft: long-term results and patient satisfaction," *Journal of Craniofacial Surgery*, vol. 18, no. 6, pp. 1457–1462, 2007.
- 15- Nakajima T, Yoshimura Y, Kami T. Refinement of the "reverse-U" incision for the repair of cleft lip nose deformity. *Br J. Plast. Surg.* 1986; 39:345-51.
- 16- Cronin TD, Denkler KA. Correction of the unilateral cleft lip nose. *Plast Reconstr Surg.* 1988; 82:419-32.
- 17- Maeda K, Ojimi H, Yoshida T. A new method of secondary correction of the bilateral cleft lip nose. *Br J Plast. Surg.* 1987; 40:52-60.
- 18- Nitin J. Mokal, Manpreet Juneja; Secondary bilateral cleft lip-nose deformity correction by rhinoplasty with simultaneous Abbe flap; *Indian J Plast Surg.* 2014;47:20-4.
- 19- Harold McComb's. V to Y of the nasal tip in his primary bilateral cleft rhinoplasty. *Brit. J Plast. Surg.* 28:262, 1975 and *PRS* 77:701, 1986 and 86:882, 1990)
- 20- Harold McComb's HK. Primary repair of the bilateral cleft lip nose: a long-term follow-up. *Plast Reconstr Surg.* 2009 Nov;124(5):1610-1615. doi: 10.1097/PRS.0b013e3181b98b5d. PMID: 20009848
- 21- Ali YH, Alandejani T. Rhinoplasty Assisted by Endoscopic Septoplasty: Precise Job and an Educational Tool. *J Craniofac Surg.* 2020 May/Jun;31(3):847-850. doi: 10.1097/SCS.0000000000006117. PMID: 32168123.
- 22- Helmy YA. Laser-assisted Lipolysis Burn Safety: Proposed Detailed Parameters with Assessment of Their Efficacy and Safety. *Plast Reconstr Surg Glob Open.* 2018;6(10):e1934. Published 2018 Oct 3. doi:10.1097/GOX.0000000000001934.
- 23- Ali YH, Al Sheikh AE. Nonmicrosurgical Grafting for Facial Nerve Branches with Permanent Sensational Functional Outcome. *Plast Reconstr Surg Glob Open.* 2019;7(5):e2195. Published 2019 May 16. doi:10.1097/GOX.0000000000002195
- 24- Alshahat O., Ali Y.H., Farahat, A., Eldosoky, I. Reconstruction of Alar Lining and Nostril Base by Oral Mucosal Flap on Muscular Pedicle. *Al-Azhar International Medical Journal*, 2020; 1(1): 1-5. doi: 10.21608/aimj.2019.19565.1000
- 25- Sakamoto, Yoshiaki MD*; Miyamoyo, Junpei MD†; Kishi, Kazuo MD* Beware of Optical Illusion of the Alar Base in Unilateral Cleft Lip Nasal Deformity, *Plastic and Reconstructive Surgery - Global Open:* April 2021 - Volume 9 - Issue 4 - p e3523 doi: 10.1097/GOX.0000000000003523
- 26- Rossell-Perry P, Olivencia-Flores C, Delgado-Jimenez MP, Ormeño-Aquino R. Surgical Nasoalveolar Molding: A Rational Treatment for Bilateral Cleft Lip Nose and Systematic Review. *Plast Reconstr Surg Glob Open.* 2020;8(9):e3082. Published 2020 Sep 24. doi:10.1097/GOX.0000000000003082
- 27- Rochlin DH, Shekter CC, Khosla RK, Lorenz HP. Rates of Revision and Obstructive Sleep Apnea after Surgery for Velopharyngeal Insufficiency: A Longitudinal Comparative Analysis of More Than 1000 Operations. *Plast Reconstr Surg.* 2021 Aug 1;148(2):387-398. doi: 10.1097/PRS.00000000000008193. PMID: 34398089; PMCID: PMC8371713.
- 28- Yarholar LM, Shen C, Wangsrimongkol B, Cutting CB, Grayson BH, Staffenberg DA, Shetye PR, Flores RL. The Nasoalveolar Molding Cleft Protocol: Long-Term Treatment Outcomes from Birth to Facial Maturity. *Plast Reconstr Surg.* 2021 May 1;147(5):787e-794e. doi: 10.1097/PRS.00000000000007828. PMID: 33890899.