



3-1-2022

## Meta-analysis of secondary cleft lip deformities management

sultan Metwally

*Resident of plastic surgery and burn, Faculty Of Medicine, Al Azhar University,*  
sultanelsherbini1666@gmail.com

Ahmed Taha

*Plastic Surgery And Burn, Faculty Of Medicine, Al Azhar University,* ahmedtaha67@gmail.com

Khallad Shalkamy

*Plastic Surgery And Burn, Faculty Of Medicine, Al Azhar University,* dr\_khallad@azhar.edu.eg

Follow this and additional works at: <https://aimj.researchcommons.org/journal>



Part of the [Medical Sciences Commons](#), [Obstetrics and Gynecology Commons](#), and the [Surgery Commons](#)

### How to Cite This Article

Metwally, sultan; Taha, Ahmed; and Shalkamy, Khallad (2022) "Meta-analysis of secondary cleft lip deformities management," *Al-Azhar International Medical Journal*: Vol. 3: Iss. 3, Article 3.

DOI: <https://doi.org/10.21608/aimj.2022.107419.1679>

This Meta Analysis is brought to you for free and open access by Al-Azhar International Medical Journal. It has been accepted for inclusion in Al-Azhar International Medical Journal by an authorized editor of Al-Azhar International Medical Journal. For more information, please contact [dryasserhelmy@gmail.com](mailto:dryasserhelmy@gmail.com).

## Meta-analysis of secondary cleft lip deformities management

Sultan Rasmy Metwally,<sup>1</sup> MBBCH, Ahmed Taha,<sup>1</sup> MD, Khallad Shalkamy,<sup>1</sup> MD.

### \* Corresponding Author:

Sultan Rasmy Metwally  
[sultanelsherbini1666@gmail.com](mailto:sultanelsherbini1666@gmail.com)  
 Received for publication  
 November 22, 2021; Accepted  
 March 18, 2022; Published  
 online March 18, 2022.

**Copyright** The Authors  
 published by Al-Azhar  
 University, Faculty of Medicine,  
 Cairo, Egypt. Users have the  
 right to read, download, copy,  
 distribute, print, search, or link  
 to the full texts of articles under  
 the following conditions:  
 Creative Commons Attribution-  
 Share Alike 4.0 International  
 Public License (CC BY-SA 4.0).

**doi:** 10.21608/aimj.2022.107419.1679

<sup>1</sup>Plastic Surgery And Burn  
 Department, Faculty of Medicine,  
 Al-Azhar University, Cairo, Egypt.

### ABSTRACT

**Background:** A congenital cleft lip is a physical and psychological abnormality that occurs at birth. Following primary lip surgery, secondary cleft lips are prevalent and have a major detrimental effect on quality of life. Creating symmetry in a cleft-lip is best done during the original repair. These include rebuilding a new philtral column or augmenting lip volume.

**Aim of the study:** to investigate the best management for common secondary cleft lip deformities through Meta-analysis.

**Methods:** A literature search was performed in PubMed, PLOS and Cochrane library. Several of the search engines have been used comprising Egyptian Knowledge Bank (EKB) platform to transfer the articles from Scopus and Clarivate databases. The study retrieved the Information of articles published beginning from 2011 to 2021.

**Results:** complication observed in whistling deformity correction with abbe flap mainly in the form of postoperative edema, infection occurred in 3 cases with curved line method, conspicuous scars in 29 cases with abbe flap, hypertrophic scarring in 6 cases with curved-line method, smiling difficulties in 2 cases with whistle flap procedure. Patients showed very good satisfaction after corrections in 97 cases with abbe flap and 21 cases with curved line or whistle flap. Lowest complications were founded in the form of pain and hematoma only in 1 case with fat grafting. In short lip, Complications founded were mainly in Diamond-Shaped Excision in 8 cases in the form of needing for scar revision. no other complications were recorded.

**Conclusion:** In this study we conclude that There is no differences of statistical importance as regard different methods of correction of each deformity and choice of method of correction depends mainly on good analysis of the presenting deformities and surgeon preference.

**Keywords:** secondary cleft lip; cleft lip; whistling deformity.

**Disclosure:** The authors have no financial interest to declare in relation to the content of this article. The Article Processing Charge was paid for by the authors.

**Authorship:** All authors have a substantial contribution to the article.

### INTRODUCTION

A congenital cleft lip is a physical and psychological abnormality that occurs at birth. Repairing a cleft lip malformation successfully is a difficult but rewarding task. Unilateral or bilateral cleft lips are possible. They can be found on their own or in conjunction with a cleft palate. Clefts of the lip and palate can be linked to other congenital abnormalities or be part of a hereditary syndrome.<sup>1</sup>

Following main lip repair, secondary cleft lip deformities are prevalent, with some estimates estimating as many as 1.1 revisions for every primary surgery.<sup>2</sup>

Secondary cleft abnormalities have a complex aetiology. The nature and severity of the cleft, as well as the original repair technique, are the most important variables in the development of a secondary deformity. Scarring, Lip deformities

(abnormal proportions or hallmark distortions of the philtral columns, Cupid's bow, and lateral lip segments), Vermillion deformities, muscular abnormalities, and buccal sulcus deformities are all examples of secondary cleft malformations. Although the severity and kind of secondary cleft malformations vary, the most frequent is a small lip, which accounts for about 30% of all secondary corrections.<sup>3</sup>

More importantly, secondary cleft lip deformities have a significant negative impact on the quality-of-life of affected individuals.<sup>4</sup>

The first repair is the best time to achieve symmetry in a cleft lip. Secondary malformations, on the other hand, are not uncommon, and they might leave the patient with a cleft stigma. Whistle deformity, a poorly defined philtrum, upper lip notching, lateral lip segment bulging, and volume shortage at the upper vermilion are all examples of secondary

deformity. Secondary correction is frequently desired for practical, cosmetic, and psychological reasons. Due to scarring and tissue insufficiency in the healed cleft lip, however, this subsequent reconstruction is significantly more difficult.<sup>5</sup>

Many procedures for secondary cleft lip correction have been published, however there has yet to be a standard treatment. The goal of these procedures is to rebuild a new philtral column, increase lip volume, and, if necessary, improve unfavourable scar results from earlier surgeries.<sup>5</sup>

Despite these advancements, no single therapy has proven to be totally successful. Furthermore, the best time for secondary surgical correction of a cleft lip is still up for debate.<sup>6</sup>

We aimed in this study to investigate the best management for common secondary cleft lip deformities through Meta-analysis.

### MATERIALS AND METHODS

A literature search was performed in PubMed, PLOS and Cochrane library. Several of the search engines have been used comprising Egyptian Knowledge Bank (EKB) platform to transfer the articles from Scopus and Clarivate databases.

The study retrieved the Information of articles published beginning from 2011 to 2021. All published articles studying secondary cleft lip deformities and their management were included in the study.

The search terms and their synonymous and closely applicable words were used in this study including (secondary cleft lip deformities, post cleft lip repair deformities, revisional surgery in cleft lip).

#### Eligibility Criteria:

The involved studies were original randomized controlled trials and cohort studies done on secondary cleft lip deformities and their management.

We disqualified duplicate studies, case reports, or case series with a sample size <10 and articles with an average follow-up time <6 months.

Studies were primary involved or left out by title and abstract. Titles were recorded via Endnote by Clarivate and Mendeley by Scopus. Two independent surgeons did information extraction systematically, adhering to the preferred reporting items for systemic review and meta-analysis (PRISMA) guidelines. Summary measures were assembled in a random-effects model meta-analysis. Study assessed the best management of secondary cleft lip deformities through meta-analysis.

All randomized control study and observational studies either cohort study or retro-analysis which are

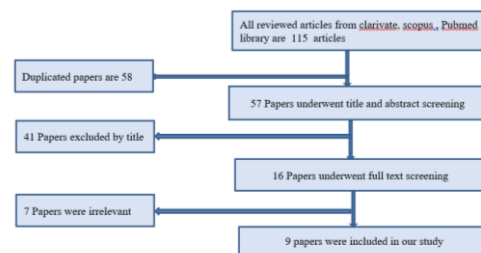
discussing management of common secondary cleft lip deformities were included in this study.

### RESULTS

In This study most common deformities founded after cleft lip repair were whistling deformity, vermilion notching, short lip. A literature search was performed in PubMed, PLOS and Clarivate – Scopus listed articles. We used many research engines including EKB to download the articles for the last 10 years.

The data bases search resulted in a total of 115 articles. 58 articles were excluded as they were duplicated. Screening of the title and abstract lead to the exclusion of 41 studies as they are irrelevant. The remaining 16 clinical trials were selected for full-text screening. After full text screening 9 papers were included in this meta-analysis. (Fig:1)

Reasons for exclusion of the 7 studies were that they were Case report, review studies or case-series studies. From these 9 papers 4 papers were investigating whistle deformity, 3 papers about short lip and the remaining 2 papers were about vermilion notching. Papers investigating other deformities were excluded as they were irrelevant.



**Fig 1:** Flow chart of the study. The characteristics of the included studies.

4 studies were included with whistling deformity with a total number of cases 204 cases, mean age was 16.5 years, M\F was 130\72

Type of correction done was Abbe Flap in 29 case, modified Abbe flap in 47 cases, double movable mucomuscular complex flaps procedure in 60 cases, fat grafting in 15 cases, curved line method in 30 cases and The Whistle Flap Procedure in 21 cases (Table1).

2 studies were included with vermilion notching with a total number of 7 cases and mean age 26.6 years, M\F 4\3 and vermilion deficiency grade was grade I (n1), grade II (n3), grade III (n2), grade IV(n1), type of correction was fat grafting in 1 case and V-flap technique in 6 cases. (Table 2).

3 studies were included with short lip deformity with a total number of 91 cases with mean age 13.4 years, M\F was 49\42, mean follow up 37.85 months

Methods of correction were diamond –shaped excision, surgical redo, Z plasty technique. (table3)

The following tables showing the patient satisfaction and complications following most common secondary cleft lip deformities management (whistle deformity, short lip )

Author	type of deformity	method of correction	Number of cases	Age	m\ f
Jian X et al. <sup>7</sup>	Whistling Deformities	Abbe Flap (n29), modified Abbe flap(n47),double mucomuscular flaps procedure(n60)	138	15.6	98\38
Baum SH et al. <sup>8</sup>	Whistling Deformities	fat grafting	15	21	1\14
Yin NB et al. <sup>9</sup>	Whistling Deformities	curved- line method	30	14	21\9
Grewal NS et al. <sup>10</sup>	Whistling Deformities	The Whistle Flap Procedure	21	15.4	10\11

**Table 1:** Study characteristics in whistling deformities.

Author	type of deformity	type of correction	number	Age	m\ f	vermilion grade	deficiency
Jackson OA et al. <sup>11</sup>	vermilion notching	Fat Grafting	1		1\0	Grade III	
Tan Baser N et al. <sup>12</sup>	vermilion notching	V-flap technique	6	26.6	3\3	grade I (n1),grade II (n3),grade III(n1),,grade IV(n1),	

**Table 2:** Study characteristics in vermilion notching.

Author	type of deformity	type of correction	number	Age	m\ f	follow up
Han K et al. <sup>13</sup>	short lip	Diamond-Shaped Excision	23	19.7	15\8	42
Hsu P-J et al. <sup>14</sup>	short lip	surgical redo	13	10.7	4\9	33.7
Reddy RR et al. <sup>14</sup>	short lip	Z-plasty technique	55	13	30\25	

**Table 3:** Study characteristics in short lip.

The following tables showing the patient satisfaction and complications following most common secondary cleft lip deformities management (whistle deformity, short lip)

Most common complication observed was edema and it was noticed in all cases with abbe flap, infection occurred only in 3 cases with curved line method , conspicuous scars in 29 cases with abbe flap , hypertrophic scarring in 6 cases with curved- line method , smiling difficulties in 2 cases with whistle flap procedure , scabbing of malpositioned wet vermilion in only 1 case with whistle flap procedure ,lowest complications were founded in the form of pain and hematoma only in 1 case with fat grafting , and future minor cleft lip revisions in 5 cases with whistle flap procedure (Table 4).

Patients showed very good reaction after corrections in 97 cases with abbe flap procedure and 21 cases in curved line method and in whistle flap procedure and in fat grafting was in 12 cases, good reaction founded in 7 cases corrected by curved line method and in 31 cases with abbe flap , acceptable reaction in 2 cases in curved line method and in 10 cases with abbe flap , 3 cases was not satisfied in fat grafting correction ,

feeling pressure founded in 4 cases in fat grafting (Table 5).

Complications founded were mainly in Diamond-Shaped Excision in 8 cases in the form of needing for scar revision, also in scar redo complications were found in 3 cases in the form of scar reversion. no other complications were recorded (Table 6).

#### Meta analysis

As P 0.0021\* and I2 (inconsistency) equal 83.72% so these studies showed heterogeneity as regarding to this patient's satisfaction in whistling deformities Type of correction, so we use total random effect and rate was 66 % with 95% CI of rate 50.94–94.60 with absence of publication bias (Table 7).

As P 0.1641 and I2 (inconsistency) equal 44.67% so these studies showed no heterogeneity as regarding to this the complication in whistling deformities Type of correction, so we use total random effect and rate was 66 % with 95% CI of rate 0.00 – 83.54 with absence of publication bias (Table 8).

As P <0.0001\*and I2 (inconsistency) equal 92.22% so these studies showed heterogeneity as regarding to this the complication in short lip Type of correction,

so we use total random effect and rate was 91 % with 95% CI of rate 80.47 – 96.90with absence of publication bias (Table 9).

Author	Grewal NS et al.	Yin NB et al.	Baum SH et al.	Jian X et al.
<b>Type of deformity</b>	Whistling Deformities	Whistling Deformities	Whistling Deformities	Whistling Deformities
<b>Type of correction</b>	The Whistle Flap Procedure	curved-line method	fat grafting	Abbe, Flap (n29), modified Abbe flap(n47),double movable mucomuscular complex, flaps procedure(n60)
<b>Complications number</b>	9	9	2	167
<b>Infection</b>		3		
<b>Edema</b>				138
<b>smiling difficulties</b>	2			
<b>scabbing of malpositioned wet vermilion conspicuous scars.</b>	1			29
<b>Pain</b>	1		1	
<b>hypertrophic scarring</b>		6		
<b>Hematoma</b>			1	
<b>future minor cleft lip revisions</b>	5			

**Table 4:** The complication in whistling deformities.

Author	Grewal NS et al.	Yin NB et al.	Baum SH et al.	Jian X et al.
<b>Type of deformity</b>	Whistling Deformities	Whistling Deformities	Whistling Deformities	Whistling Deformities
<b>Type of correction</b>	The Whistle Flap Procedure	curved-line method	fat grafting	Abbe, Flap (n29), modified Abbe flap(n47), double movable mucomuscular complex, flaps procedure(n60)
<b>Very good</b>	21	21	12	97
<b>Good</b>		7		31
<b>Acceptable</b>		2		10
<b>Not satisfied</b>			3	
<b>feeling of pressure</b>			4	

**Table 5:** Patient's satisfaction in whistling deformities.

Author	Han K et al.	Hsu P-J et al.	Reddy RR et al.
<b>Type of deformity</b>	short lip	short lip	short lip
<b>Method of correction</b>	Diamond-Shaped Excision	surgical redo	Z-plasty technique
<b>Number of complications</b>	8	3	0
0	3	8	<b>Scar revision</b>

**Table 6:** Complications in short lip deformity.

Type of correction	Total number	Event	Event rate (%) (Proportion)	95% CI of rate (%)
Fat grafting	15	12	80.0	51.911 – 95.669
Curved-line method	30	21	70.0	50.604 – 85.265
The Whistle Flap Procedure	21	21	100.0	83.890 – 100.00
Total (fixed effects)	66		84.08	73.291 – 91.782
Total (random effects)	66		85.22	59.180 – 99.076
Test for heterogeneity				
Q	12.2876			
DF	2			
Significance level	0.0021*			
I <sup>2</sup> (inconsistency)	83.72%			
95% CI for I <sup>2</sup>	50.94–94.60			

**Table 7:** Meta-analysis for the very good patient's satisfaction in whistling deformities.

Type of correction	Total number	Event	Event rate (%) (Proportion)	95% CI of rate (%)
Fat grafting	15	2	13.333	1.658 – 40.460
Curved-line method	30	9	30.000	14.735 – 49.396
The Whistle Flap Procedure	21	9	42.857	21.820 – 65.979
Total (fixed effects)	66		30.577	20.047 – 42.837
Total (random effects)	66		30.019	16.515 – 45.586
Test for heterogeneity				
Q	3.6146			
DF	2			
Significance level	0.1641			
I <sup>2</sup> (inconsistency)	44.67%			
95% CI for I <sup>2</sup>	0.00 – 83.54			

**Table 8:** Meta-analysis for the complication in whistling deformities.

Short lip	Total number	Event	Event rate (%) (Proportion)	95% CI of rate (%)
Diamond-Shaped Excision	23	8	34.783	16.376 – 57.266
surgical redo	13	3	23.077	5.038 – 53.813
Z-plasty technique	55	0	0.000	0.000 – 6.487
Total (fixed effects)	91		7.662	3.186 – 15.016
Total (random effects)	91		15.238	0.0009 – 51.369
Test for heterogeneity				
Q	25.7107			
DF	2			
Significance level	<0.0001*			
I <sup>2</sup> (inconsistency)	92.22%			
95% CI for I <sup>2</sup>	80.47 – 96.90			

**Table 9:** Meta-analysis for the complication in short lip.

## DISCUSSION

Four studies with whistling deformity were included, with a total of 204 patients, a mean age of 16.5 years, and an MF of 13072. Abbe Flap in 29 cases, modified Abbe flap in 47 cases, double movable mucomuscular complex flaps technique in 60 cases, fat grafting in 15 cases, curved line method in 30 cases, and The Whistle Flap Procedure in 21 cases were the types of corrections performed.

Jian et al.<sup>7</sup> enrolled 136 cases (98 were men (72.0 percent) with ages ranging from 9 to 34 years, and the average age was 15.6 years) among these

patients, 60 (44.2 percent) suffered from grade I whistling deformity and 47 (34.5 percent) suffered from grade II deformity, and repair was performed by means of the double movable mucomuscular complex flaps procedure and modified Abbe flap transfer procedure, respectively.<sup>7</sup>

In addition, Baum et al.<sup>8</sup> conducted a pilot trial in which 15 patients were engaged in a 4.5-year study in which 17 autologous fat grafts were performed. Females made up 14 of the patients. Their ages ranged from 15 to 70 years old, with a median age of 21. Six of the patients had a complete unilateral cleft lip, whereas the other nine had a complete unilateral

cleft lip and palate. The average period of follow-up was 19 months. The study by Yin et al.<sup>9</sup> introduced the curved-line method for correcting secondary deformities of bilateral complete cleft lip (BCCL) and assesses its short-term results, they enrolled 30 patients with bilateral cleft lip (21 males and 9 females) ages 4–27 years (mean age 14 years, 2 months) who had formerly experienced surgery to treat BCCL via the lateral columellar flap procedure or the straight-line procedure.<sup>9</sup>

Furthermore, a study by Grewal et al.<sup>10</sup> utilized the whistle flap procedure for correction of secondary cleft lip deformity, they enrolled 21 patients with secondary cleft lip deformity, (bilateral, n = 13; unilateral, n = 8). The usual age at surgery was 15.4 years (varies from 13 to 21 years). Study patients with secondary cleft lip deformity had inadequate central lip volume (100 %), lip contour asymmetries (86 %), vermilion bottom scarring (86 %), or excess lateral lip volume (90 %). In addition, they were documented as having worsening whistle deformity on activation (81 %), and restriction of dynamic lip movement (71 %). The average follow-up was 27.6 months.<sup>10</sup>

Regarding outcome, The mean resorption rate was reported to be 53% (range 30–80%) in Baum et al's study<sup>8</sup>, indicating that all patients improved their whistling deformity. The preoperative and postoperative ratios (vertical lip length) were 0.87 and 0.93, respectively (p = 0.001). The resorption rate was 50% or above in 13 of the 17 operations. Three individuals had under-correction as a result of resorption. Two of these under-corrections might be addressed with additional fat grafting six and twelve months later, respectively, but the third patient refused.

According to Baum et al.<sup>8</sup> all patients were satisfied with the outcome after surgery. Three patients (20%) were not completely satisfied at the 6-month follow-up because they had hoped for a (long-lasting) volume effect. After the correction, the patients who had the second lipofilling were similarly satisfied. From a medical standpoint, 10 out of 15 patients expressed pleasure. There was no evidence of a relapse after 6 months due to increasing resorption.<sup>8</sup>

Comparative lip measures revealed improvement in vermilion height, according to a research by Yin et al.<sup>9</sup> When follow-up ratios of upper-to-lower labial measurements were compared to preoperative measurements, the vertical height of the median lip was found to have increased by 152.20% (P 0.05). In addition, the left Cupid's bow point vermilion height increased by 87.34 percent, whereas the right Cupid's bow point vermilion height increased by 91.5 percent (P 0.05). Twenty-one of the thirty patients rated their results as "excellent," seven rated them as "good," and only two rated them as "acceptable." According to Grewal et al.<sup>10</sup> all patients had very good to exceptional functional results with no alteration in their capacity to grin. They also found that the mean raises the upper lip, with a right-angled distance of 117.12mm (p 0.05) from the N-ANS line (nasion to

the anterior nasal spine) to the anterior lip projection point. In terms of volumetric and surface area assessments, they also found that after the Whistle flap treatment, upper lip symmetry improved. A mean preoperative symmetry score of 29.4 was improved to a mean follow-up symmetry score of 3.1 (p0.05) in volumetric assessments. Three-dimensional volumetric analysis by Grewal et al.<sup>10</sup> demonstrated a nearly even volume distribution of the upper lip in follow-up patients. Posttreatment asymmetry was approximately 0.9% (mouth closed, lips parted, and frontal view) and 0.6 percent (mouth open, worm's-eye view). The second representative patient was a unilateral cleft patient demonstrating the following: II. Mouth open: whole lip surface area, 823.90 mm<sup>2</sup>; right hemilip, 414.57 mm<sup>2</sup>; left hemilip, 409.33 mm<sup>2</sup>.<sup>9</sup>

In the curved line method by Yin et al.<sup>9</sup> they reported that there was a significant improvement over previous methods used to correct secondary BCCL deformity. Their postoperative measurements displayed, the mean increases in central upper vermilion height and the vermilion heights of Cupid's bow points were 152 ± 20% (central upper vermilion), 87 ± 34% (left Cupid's bow point), and 91 ± 5% (right Cupid's bow point) (P B 0.05). Of the 30 patients, 21 were very satisfied with their outcomes, while seven patients graded their outcomes as good.<sup>9</sup>

As regard complications: Jian et al.<sup>7</sup> reported that the complications of bleeding, infection, or dehiscence were not found. All patients developed mild to moderate postoperative edema of the upper lip, with 29 cases (21.3%) developing conspicuous scars. Other cases showed inconspicuous scars.<sup>7</sup>

While Baum et al.<sup>8</sup> reported that a hematoma was found in one patient (7%) and a feeling of pressure in four patients (27%). Another patient had a repeated pain in the lip area (7%). None of the complications required an intervention. Fistulas, infections, liquefaction of the transplant, lasting pain, or peritonitis were not observed.<sup>8</sup>

In addition, Yin et al.<sup>9</sup> reported that three patients had mild infections that resolved after a course of oral antibiotics. Six patients developed minor hypertrophic scarring on the white lip. In the follow-up period, no recurrence of whistling deformity was found in any patient.<sup>9</sup>

Furthermore, Grewal et al.<sup>10</sup> reported that in the perioperative course, minimal complications occurred: wound breakdown (0 percent), bleeding (9 percent), infection (14 percent) that resolved after a course of oral antimicrobial, hypertrophic scarring (4 percent), functional lip difficulties during the first 6 weeks postoperatively (9 percent), or overall number of patients with any complications (21 percent).<sup>10</sup>

Our meta-analysis for these studies showed that as P=0.0021\* and I2 (inconsistency) equal 83.72% so these studies showed heterogeneity as regarding to patient's satisfaction in whistling deformities Type of

correction so we use total random effect and rate was 66 % with 95% CI of rate 50.94–94.60 with absence of publication bias.

Two studies were included with vermilion notching with a total number of 7 cases and mean age 26.6 years, M\F 4\3 and vermilion deficiency grade was grade I (n1), grade II (n3), grade III (n2), grade IV(n1), type of correction was fat grafting in 1 case and V-flap technique in 6 cases.

The study by Jackson et al.<sup>11</sup> aimed to describe a novel lip augmentation technique to address vermilion deficiencies after cleft lip repair, they enrolled one male patient of vermilion deficiency grade III. They achieve vermilion symmetry on this case.<sup>11</sup>

Furthermore, Baser et al.<sup>12</sup> performed a reconstruction of vermilion deficiencies using the running V-flap technique, they enrolled six patients (three female and three male) aged 16-42 years. Vermilion deficiencies in the upper lip were graded as grade I (n1), grade II (n3), grade III and grade IV. The patients had no complaint of dryness or crusting in their lip's mucosa. There were no color mismatches or scarring over the lip mucosa in all patients' mouths.<sup>12</sup>

Our meta-analysis of the studies revealed that  $P=0.1641$  and  $I^2$  (inconsistency) equal 44.67% so these studies showed no heterogeneity as regarding to the complication in whistling deformities Type of correction so we use total random effect and rate was 66 % with 95% CI of rate 0.00 – 83.54 with absence of publication bias.

Three studies were included with short lip deformity with a total number of 91 cases with mean age 13.4 years, M\F was 49\42, mean follow up 37.85 months.

The study by Han et al.<sup>13</sup> presented curvilinear transformation method for the Z-shaped upper lip scar by diamond-shaped excision and estimated the results using photogrammetric analyses, the study enrolled 23 patients with ages ranged from 8 to 35 years (mean age, 19.7 years). Of a total of 23 patients, 15 were male. Sixteen patients were on the left side of the upper lip, and 7 patients were on the right side. The mean follow-up time was 42 months.<sup>13</sup>

As regard Outcome measures, the study by Han et al.<sup>13</sup> reported that the width of the postoperative curvilinear scar was 4.6 6 1.6 mm. There was a statistically significant diminution between the preoperative central limb of the Z-shaped scar and the width of the postoperative curvilinear scar ( $P < .000$ ) after the scar revision. The difference between the two values was not statistically significant. There was no statistical difference in the pre- and post-revisionary Cupid's bow height difference.<sup>13</sup>

Furthermore, Reddy et al.<sup>14</sup> reported that a reliability of  $<0.8$ , a large duplicate measurement error (DME), or a Pvalue  $<0.05$  are indicators of relatively low

measurement performance, for 18 out of 25 outcomes, the differences between the two measurements showed statistically significant reliability.<sup>14</sup>

Regarding complications, The study by Han et al.<sup>13</sup> reported that 8 patients asked for scar revision because of scar widening, and results of the scar revision were relatively good.<sup>13</sup>

Our meta-analysis of the studies revealed that  $P < 0.0001$  and  $I^2$  (inconsistency) equal 97.16% so these studies showed heterogeneity as regarding to Type of correction, so we use total random effect and rate was 91 % with 95% CI of rate 94.35 – 98.57 with absence of publication bias.

It was also found that  $P < 0.0001$  and  $I^2$  (inconsistency) equal 92.22% so these studies showed heterogeneity as regarding to the complication in short lip Type of correction, so we use total random effect and rate was 91 % with 95% CI of rate 80.47 – 96.90 with absence of publication bias.

## CONCLUSION

In conclusion there are no differences of statistical importance as regard different methods of correction of each deformity and choice of method of correction depends mainly on good analysis of the presenting deformities and surgeon preference.

## REFERENCES

1. Shkoukani, M.A., M. Chen, and A.J.F.i.p. Vong, Cleft lip—a comprehensive review. *Frontiers in pediatrics*. 2013; 1: 53.
2. Morzycki, A., Morzycki A, Wong A, Hong P, et al., Assessing attentional bias in secondary cleft lip deformities: an eye-tracking study. *The Cleft Palate-Craniofacial Journal*. 2019; 56(2): 257-64.
3. Choi, W.Y., Yang JY, Kim GB, et al., Surgical correction of whistle deformity using cross-muscle flap in secondary cleft lip. *Archives of plastic surgery*. 2012; 39(5): 470.
4. Sinko, K., Jagsch R, Prechtel V, et al., Evaluation of esthetic, functional, and quality-of-life outcome in adult cleft lip and palate patients. *Archives of plastic surgery*. 2005; 42(4): p. 355-61.
5. Nadjmi, N., Amadori S and Van de Castele E. Secondary cleft lip reconstruction and the use of pedicled, deepithelialized scar tissue. *Plastic and Reconstructive Surgery Global Open*. 2016; 4(10).
6. Lim, A.A., Allam KA, Taneja R, et al. Constructing the philtral column in the secondary cleft lip deformity: utilizing the palmaris longus graft. *Annals of Plastic Surgery*. 2013; 70(3): 296-300.



7. Jian, X., Jian, Y., Wu, X., et al., Strategy for Correction of the Whistling Deformity in Secondary Cleft Lip Reconstruction. *Plast Reconstr Surg Glob Open*. 2020; 8(9): 3156.
8. Baum, S.H., et al., Correction of whistle deformity using autologous free fat grafting: first results of a pilot study and review of the literature. *Oral Maxillofac Surg*. 2017; 21(4): 409-18.
9. Yin, N.B., Gao, F., Wang, Y.Q., et al. Correction of secondary bilateral complete cleft lip and whistling deformities: the advance and rearrangement of the bilateral lip tissues. *Aesthetic Plast Surg*. 2011; 35(5): 750-5.
10. Grewal, N.S., Kawamoto, H.K., Kumar, A.R., et al., Correction of secondary cleft lip deformity: the whistle flap procedure. *Plast Reconstr Surg*. 2009; 124(5): 1590-8.
11. Jackson, O.A., Lee, A., Nikovina, E., et al. Precision Dermal Fat Grafting for Vermillion Deficiencies in Patients with Unilateral and Bilateral Cleft Lip. *Cleft Palate Craniofac J*. 2020; 57(1): 127-31.
12. Baser, N.T., Terzioglu, A, and G. Aslan G. Reconstruction of vermilion deficiencies: the running V-flap technique. *J Plast Reconstr Aesthet Surg*. 2012; 65(10):1331-4.
13. Han K, Jeong H, Hyun Choi T, et al. Curvilinear transformation of z-shaped upper lip scar by diamond-shaped excision in secondary cleft lip deformities: a photogrammetric evaluation. *Cleft Palate Craniofac J*. 2015; 52(2):143-51.
14. Reddy RR, Reddy SG, Banala B, et al. Use of a modified Furlow Z-plasty as a secondary cleft palate repair procedure to reduce velopharyngeal insufficiency. *Int J Oral Maxillofac Surg*. 2016; 45(2):170-6.