



2-1-2022

## Evaluation of Endoscopic and Trans-Blepharoplasty Approaches for Brow Lifting

Mohab Sharafuddin

*Independent Plastic Surgery Specialist, mohabsharaf@azhar.edu.eg*

Ahmed Taha

*Plastic Surgery Dep., Al-Azhar University, ahmedesprs@hotmail.com*

Abd El Monem Houta

*Plastic Surgery Dep., Al-Azhar University, sghplastic@gmail.com*

Follow this and additional works at: <https://aimj.researchcommons.org/journal>



Part of the [Medical Sciences Commons](#), [Obstetrics and Gynecology Commons](#), and the [Surgery Commons](#)

### How to Cite This Article

Sharafuddin, Mohab; Taha, Ahmed; and Houta, Abd El Monem (2022) "Evaluation of Endoscopic and Trans-Blepharoplasty Approaches for Brow Lifting," *Al-Azhar International Medical Journal*: Vol. 3: Iss. 2, Article 20.

DOI: <https://doi.org/10.21608/aimj.2022.100179.1601>

This Original Article is brought to you for free and open access by Al-Azhar International Medical Journal. It has been accepted for inclusion in Al-Azhar International Medical Journal by an authorized editor of Al-Azhar International Medical Journal. For more information, please contact [dryasserhelmy@gmail.com](mailto:dryasserhelmy@gmail.com).

## Evaluation of Endoscopic and Trans-Blepharoplasty Approaches for Brow Lifting

Mohab Abdulkafy Sharafuddin<sup>1</sup> MSc, Ahmed Taha Sayed<sup>1</sup> MD, Abd El Monem Hussain Hassan Houta<sup>1</sup> MD.

### \* Corresponding Author:

Mohab Abdulkafy Sharafuddin  
[mohabsharaf@azhar.edu.eg](mailto:mohabsharaf@azhar.edu.eg)

Received for publication October 21, 2021; Accepted February 22, 2022; Published online February 22, 2022.

**Copyright** The Authors published by Al-Azhar University, Faculty of Medicine, Cairo, Egypt. Users have the right to read, download, copy, distribute, print, search, or link to the full texts of articles under the following conditions: Creative Commons Attribution-Share Alike 4.0 International Public License (CC BY-SA 4.0).

**doi:** 10.21608/aimj.2022.100179.1601

<sup>1</sup>Plastic and burn surgery Care Department, Faculty of Medicine, Al-Azhar University, Cairo, Egypt.

### ABSTRACT

**Background:** Brow lift can be done by numerous methods, whether for rejuvenation due to aging or ptosis due to nerve damage, surgical correction can be done through trans-blepharoplasty and endoscopic approaches.

**Aim of the study:** To Compare the endoscopic and trans-blepharoplasty approaches for brow lifting and to evaluate the outcome according to anthropometric measurements of the medial and lateral ends of the eyebrow in relation to the nasal ala, along with patient satisfaction.

**Patients and Methods:** The study included 20 patients having eyebrow lift procedures in two groups, Group 1: treated by Trans-blepharoplasty approach Group 2: treated by Endoscopic approach. Follow up was done in 6 months duration.

**Results:** Trans-blepharoplasty achieved best results in patients having mild brow ptosis with upper eyelid dermatochalasis. Although it gave a fair amount of lift post-operative, the amount of relapse in the first 6 month was substantial. Endoscopic approach is the best in eyebrow reshaping more than mere lift that cannot be done with other approaches, relapse started as early as one-month post-operative and continued gradually till 6 months post-operative.

**Conclusion:** Trans-blepharoplasty is best in treating mild cases which also complain of upper eyelid dermatochalasis, where Endoscopic approach is best in eyebrow reshaping when performing eyebrow lift.

**Keywords:** Brow lift; Brow ptosis; Endoscopic brow lift; Blepharoplasty

**Disclosure:** The authors have no financial interest to declare in relation to the content of this article. The Article Processing Charge was paid for by the authors.

**Authorship:** All authors have a substantial contribution to the article.

### INTRODUCTION

The orbit and the periorbital region are the master of the facial expressions, they give the general impression of sadness, happiness, and anger. The eyebrow shape and position define the young, desirable, and beautiful face.<sup>1</sup>

The definition of an ideal eyebrow may seem impossible, yet criteria for eyebrow position to look younger and attractive includes that the eyebrow should start medially at a line extending upwards from nasal ala passing through medial canthus, then curve upwards and laterally and peaks at a line extending above the lateral limbus, at that point the lateral third starts.<sup>2</sup>

These criteria must be adjusted to suite the difference in face shape, gender, age, ethnicity, and many other facial features. Nevertheless, there is a general agreement on the relationship between the eyebrow and the bony orbit, as for females the eyebrow lies and

arch just above the supraorbital rim, while in males the eyebrow lies directly over the supraorbital rim.<sup>1</sup>

Facial aging usually starts in periorbital area. Volume loss, brow shape and position, eyelid position and dermatochalasis, dynamic and static rhytids can also contribute to this process.<sup>3</sup>

Patients often be irritated by brow ptosis in many different ways, this can make the presentation vary widely from just correcting the ptosis for cosmetic purpose, as correcting the sad, angry or the unrested look that the ptotic eyebrow gives, or complaining about heavy brow, to a more functional complaints as superior visual field restriction, brow ache, headache or manifestations of facial nerve palsy.<sup>4</sup>

Correction of brow ptosis can be classified into two main categories, the first is non-surgical methods or minimally invasive, which are non- permanent and short-term solution with short learning curve and their complications can be corrected simply. The Surgical techniques, on the other hand, may offer

more longevity, and have longer learning curve to master the techniques.<sup>5</sup>

The aim of this study is to compare the endoscopic and trans-blepharoplasty approaches for brow lifting and evaluation of the outcome according to anthropometric measurements of the medial and lateral ends of the eyebrow in relation to the nasal ala, along with patient satisfaction.

### PATIENTS AND METHODS

The study included 20 patients undergoing brow lift procedures; the patients will be divided into 2 main groups; Group 1: 10 patients treated by Trans-blepharoplasty approach of Brow lifting. Group 2: 10 patients treated by Endoscopic Approach.

The criteria for inclusion in the study were any male or female between 18 years and 70 years, with brow ptosis. Patients were excluded if they were below 18 years or over 70 years, unfit for operations, had blood disease or coagulopathy, had generalized muscle disease, with corneal exposure, lagophthalmos, dry eye, cranial bone lesion, body dysmorphic disorder or had recent botulinum toxin type A injection.

#### Pre-operative preparation:

Anthropometric brow lift measurement of the patient brow was done by measuring the distance between ala nasi and lateral tail of eyebrow (NALB), distance between ala nasi and medial end of the eyebrow (NAMB), hairline position and shape, forehead length, forehead shape, and upper and lower eyelid position.

Dermatochalasis of the upper eyelid was assessed by the amount of skin excess by skin pinch test and position of the eyelid by margin gap reflex distance (MRD I).

Also detailed history of pre-existing ocular conditions was obtained, complete medical history was elicited to discover any comorbidities that may have ocular manifestations.

Ophthalmological examination of the patient was done, which include visual acuity, extraocular muscle assessment, visual field by confrontation test, lacrimal secretion, corneal sensation, pupillary assessment, the presence or absence of a Bell phenomenon, and exclusion of glaucoma.

Physical examination of the patient and examination of the cranial nerves specifically the oculomotor nerve (cranial nerve III), Trochlear nerve (cranial nerve IV), Abducens nerve (cranial nerve VI) for the extraocular muscle movement, Facial nerve (cranial nerve VII) for the facial muscle movement, and Trigeminal nerve (cranial nerve V) for the facial sensation are also included, with pre-operative lab investigations.

Medical Photography: Frontal and lateral views.

A consent form was signed by the patients involved in the study. And approved by Al-Azhar Ethical committee.

#### Post-Operative Measures, Objective, and Subjective Evaluation:

Objective evaluation included anthropometric brow lift measurements was reassessed at 1 months, 3 months, and 6 months. Medical photography: same views as pre-operative assessment. Subjective evaluation was in the form of a questionnaire for patient satisfaction about scar appearance, visual field improvement, time needed to resume social activity, psychological impact, and cost. Also, Global Aesthetic Improvement scale (GAIS) questionnaire.

#### Operative Steps:

Patients were marked in sitting position; procedures done in operating room under the influence of general anesthesia. Then the patient was injected with saline adrenaline 1:200,000 with the addition of 10 ml Lidocaine 2% through the incision line and dissection track. The patient is sterilized and draped, and the table is tilted 30 degrees in semi-sitting position.

#### Surgical procedure

Through elliptical traditional blepharoplasty incision, dissection proceeded toward the eyebrow in orbicularis muscle plane towards the superior orbital rim. The periosteum over the orbital rim is then exposed along the full length of the eyebrow with caution not to injure the neurovascular bundle. Dissection is extended laterally to release the orbital retaining ligaments. Superior lateral part of the orbicularis is then excised, and Brassiere sutures are done between the orbicularis oculi muscle and fat pads and attach it to the periosteum of the superior orbital rim or just slightly above it in women assessed intraoperative according to every patient ranging from 5 mm to 10 mm<sup>6</sup>, 3 or 4 suspension sutures in an arch manner from medial to lateral to achieve the maximum aesthetic outcome.

Endoscopic approach requires five incisions, one central incision for visualization behind the hairline, two paracentral behind the hairline for instrumentation and two horizontal temporal incisions behind the temporal hairline.

Equipment includes a 5-mm endoscope, with a 30-degree angle connected to a light source and viewing screen. dissection done by a curved dissectors and curved periosteal elevators, the high-speed drill and mini plates and screws are used as fixation device.

Dissection is carried out in supra periosteal plane in forehead till 2 cm above the supra orbital rim, then continue in subperiosteal plane to avoid injury of the neurovascular bundles. Dissection continuous

laterally to mobilize the lateral tail of the eyebrow from the supraorbital rim, also, arcus marginalis is released from lateral supraorbital rim. Then dissection proceeds between the superficial and deep temporal fascia, avoiding injury to the superficial temporal vessels and the temporal branch of facial nerve by identifying the sentinel vein. The temporal line of fusion is then released. Then the subperiosteal frontal dissection are connected with both temporal incisions.

Forehead flap is then elevated, and the excess skin is excised, the temporal flap is secured in a posterior-superior vector. We use the suture suspension technique and pass 3 -5 suspension non-absorbable 2/0 or 3/0 sutures from the eyebrow and tied around mini plate through the paracentral incision. The desired location of the eyebrow is then achieved with the account for relapse we tend to overcorrect the eyebrow, the skin is draped to its new position and closed in layers.

**Post-operative**

The patients are discharged with simple analgesic and fresh tears eyedrops for five days, anti-edematous tablets and prophylactic antibiotic for seven days. Instructions were given to the patients to avoid any facial massage, to sleep in a semi-sitting position for one week and to avoid vagarous eyebrow movement for 24 hours. The patient is informed about post lift oedema and ecchymosis and that they are considered a normal sequel after the brow lift. Sutures were removed after 7 – 9 days post-operative.

**Statistical analysis:**

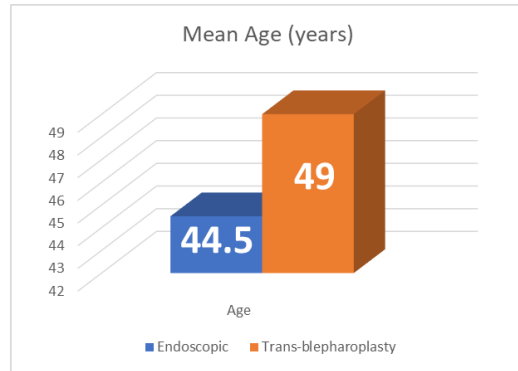
Data were collected, revised, coded, and entered to the Statistical Package for Social Science (IBM SPSS) version 23. The quantitative data were presented as mean, standard deviations and ranges when parametric and median, inter-quartile range (IQR) when data found non-parametric. Also, qualitative variables were presented as number and percentages.

The comparison between two groups regarding quantitative data and parametric distribution was done by using independent t-test.

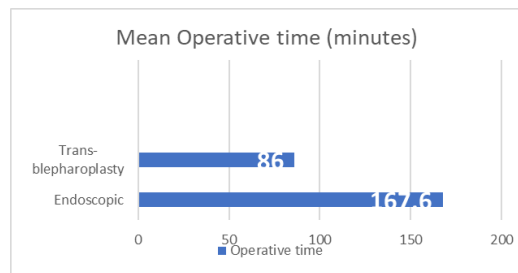
The confidence interval was set to 95% and the margin of error accepted was set to 5%. So, the p-value was considered significant as the following: P-value > 0.05: Nonsignificant (NS), P-value < 0.05: Significant (S) and P-value < 0.01: Highly significant (HS).

**RESULTS**

The study was conducted on 20 patients 5 were males and 15 females, the youngest was 28 years old and the oldest 60 years old (Figure 1).



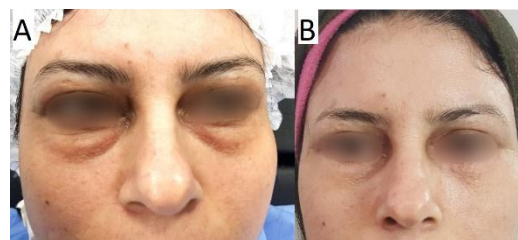
**Fig 1:** Mean age distribution.



**Fig 2:** Mean operative time.

**Objective Evaluation**

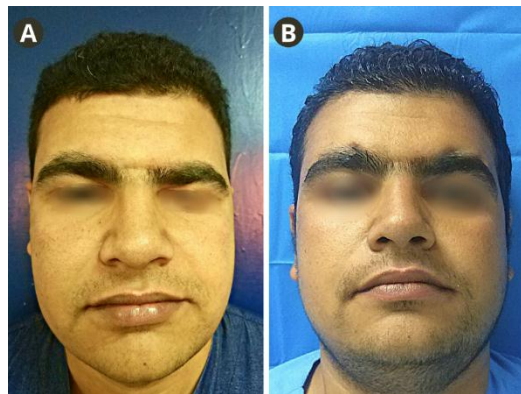The Trans-blepharoplasty brow lift achieved initial mean lift in lateral brow by 0.54 cm ± 0.11 cm in the Right side and 0.58 cm ± 0.13 cm in Left side, on follow up the relapse started as early as 1-month post-operative, after 6 months of follow up, the final mean lift was 0.30 cm ± 0.10 cm in the Right side and 0.28 cm ± 0.13 cm in the Left side. As regard the medial brow, the initial mean lift in medial brow by 0.20 cm ± 0.07 cm in the Right side and 0.24 cm ± 0.05 cm in Left side, on follow up after 6 months the final mean lift was 0.20 cm ± 0.07 cm in both the Right and the Left side (Figure 3; Table 1, 2).



**Fig 3:** Trans-blepharoplasty A) pre-operative B) 6 months post-operative.

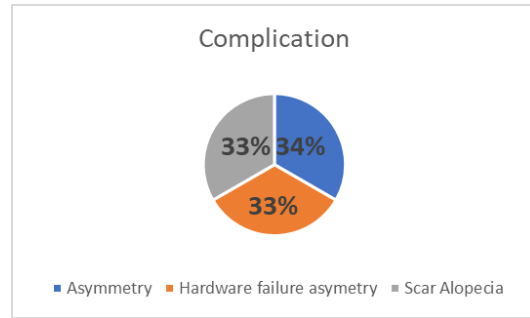
Results obtained from the endoscopic eyebrow lift shows initial mean lift in lateral brow by 0.77 cm ± 0.37 cm in the Right side and 0.86 cm ± 0.37 cm in Left side, on follow up the relapse started as early as one-month post-operative and continued gradually till 6 months post-operative. The final mean lift was 0.66 cm ± 0.33 cm in the Right side and 0.72 cm ± 0.40 cm in the Left side. The medial brow was lifted and showed initial mean lift in medial brow by 0.39 cm ± 0.30 cm in the Right side and 0.35 cm ± 0.32 cm in Left side. After 6 months of follow up the final mean lift was 0.29 cm ± 0.29 cm in the Right side

and 0.33 cm ± 0.31 cm in the Left side (Figure 4) (Table 1 , 2).

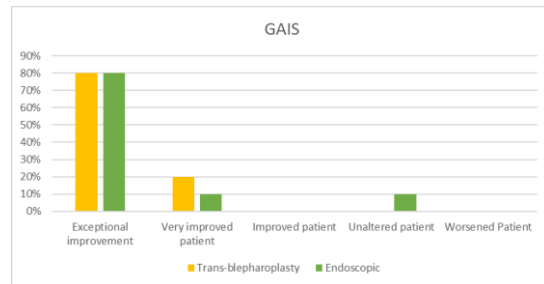


**Fig 4:** Endoscopic A) pre-operative B) 6 months post-operative, note the dimples of the suspension suture above the eyebrow which resolve over time.

Complications are represented in (Figure 5). As regard subjective evaluation, results of the questionnaire are represented in (Table 3), while results of GAIS questionnaire are represented in (Figure 6).



**Fig 5:** Endoscopic A) pre-operative



**Fig 6:** results of GAIS questionnaire.

NALB	Trans-blepharoplasty		Endoscopic		Test value	P-value	Sig.
	Mean ± SD	Range	Mean ± SD	Range			
<b>Right</b>							
Pre vs early post	0.54 ± 0.11	0.40 – 0.70	0.77 ± 0.37	0.00 – 1.20	-1.910•	0.072	NS
Early post vs 1 month	-0.10 ± 0.07	-0.20 – 0.00	-0.06 ± 0.08	-0.20 – 0.00	-1.177•	0.255	NS
1 month vs 3 month	0.00 ± 0.00	0.00 – 0.00	-0.01 ± 0.03	-0.10 – 0.00	1.000•	0.331	NS
3-month vs 6 month	-0.14 ± 0.05	-0.20 – -0.10	-0.04 ± 0.07	-0.20 – 0.00	-3.638•	0.002	HS
Pre Vs 6 month	0.30 ± 0.09	0.20 – 0.40	0.66 ± 0.33	0.00 – 1.20	-3.343•	0.004	HS
Early post vs 6 month	-0.24 ± 0.08	-0.30 – -0.10	-0.11 ± 0.13	-0.30 – 0.00	-2.672•	0.016	S
<b>Left</b>							
Pre vs early post	0.58 ± 0.12	0.40 – 0.70	0.86 ± 0.37	0.20 – 1.50	-2.245•	0.038	S
Early post vs 1 month	-0.18 ± 0.23	-0.60 – 0.00	-0.11 ± 0.17	-0.50 – 0.00	-0.780•	0.446	NS
1 month vs 3 month	0.00 ± 0.00	0.00 – 0.00	-0.02 ± 0.10	-0.30 – 0.10	0.612•	0.548	NS
3-month vs 6 month	-0.12 ± 0.08	-0.20 – 0.00	-0.01 ± 0.03	-0.10 – 0.00	-4.093•	0.001	HS
Pre Vs 6 month	0.28 ± 0.12	0.10 – 0.40	0.72 ± 0.40	0.10 – 1.20	-3.308•	0.004	HS
Early post vs 6 month	-0.30 ± 0.18	-0.60 – -0.10	-0.14 ± 0.17	-0.50 – 0.00	-2.058•	0.054	NS

**Table 1:** Right and Left NALB mean distribution, range, p-value, and significance

NAMB	Trans-blepharoplasty		Endoscopic		Test value	P-value	Sig.
	Mean ± SD	Range	Mean ± SD	Range			
<b>Right</b>							
Pre vs early post	0.20 ± 0.07	0.10 – 0.30	0.39 ± 0.30	0.00 – 0.80	-1.956•	0.066	NS
Early post vs 1 month	0.00 ± 0.00	0.00 – 0.00	-0.07 ± 0.22	-0.70 – 0.00	1.000•	0.331	NS
1 month vs 3 month	0.00 ± 0.00	0.00 – 0.00	-0.01 ± 0.03	-0.10 – 0.00	1.000•	0.331	NS
3-month vs 6 month	0.00 ± 0.00	0.00 – 0.00	-0.02 ± 0.06	-0.20 – 0.00	1.000•	0.331	NS
Pre Vs 6 month	0.20 ± 0.07	0.10 – 0.30	0.29 ± 0.29	0.00 – 0.80	-0.961•	0.349	NS
Early post vs 6 month	0.00 ± 0.00	0.00 – 0.00	-0.10 ± 0.22	-0.70 – 0.00	1.430•	0.170	NS
<b>Left</b>							
Pre vs early post	0.24 ± 0.05	0.20 – 0.30	0.35 ± 0.32	0.00 – 1.00	-1.071•	0.298	NS
Early post vs 1 month	-0.04 ± 0.08	-0.20 – 0.00	0.00 ± 0.00	0.00 – 0.00	-1.500•	0.151	NS
1 month vs 3 month	0.00 ± 0.00	0.00 – 0.00	0.00 ± 0.00	0.00 – 0.00			
3-month vs 6 month	0.00 ± 0.00	0.00 – 0.00	-0.02 ± 0.04	-0.10 – 0.00	1.500•	0.151	NS
Pre Vs 6 month	0.20 ± 0.07	0.10 – 0.30	0.33 ± 0.31	0.00 – 1.00	-1.285•	0.215	NS
Early post vs 6 month	-0.04 ± 0.08	-0.20 – 0.00	-0.02 ± 0.04	-0.10 – 0.00	-0.671•	0.511	NS

**Table 2:** Right and Left NAMB mean distribution, range, p-value, and significance.



Questionnaire		Trans-blepharoplasty No. (%)	Endoscopic No. (%)
Scar appearance	Fair	0 (0.0%)	0 (0.0%)
	Good	0 (0.0%)	0 (0.0%)
	Very good	2 (20.0%)	1 (10.0%)
	Excellent	8 (80.0%)	9 (90.0%)
Visual Field improvement	Not Complaining	6 (60.0%)	5 (50.0%)
	Fair	0 (0.0%)	0 (0.0%)
	Good	0 (0.0%)	0 (0.0%)
	Very good	0 (0.0%)	1 (10.0%)
	Excellent	4 (40.0%)	4 (40.0%)
Recovery Time	Fair	0 (0.0%)	0 (0.0%)
	Good	0 (0.0%)	0 (0.0%)
	Very good	0 (0.0%)	3 (30.0%)
	Excellent	10 (100.0%)	7 (70.0%)
Psychological Impact	Fair	0 (0.0%)	0 (0.0%)
	Good	0 (0.0%)	1 (10.0%)
	Very good	1 (10.0%)	3 (30.0%)
	Excellent	9 (90.0%)	6 (60.0%)
Social Activity	Fair	0 (0.0%)	0 (0.0%)
	Good	2 (20.0%)	0 (0.0%)
	Very good	0 (0.0%)	4 (40.0%)
	Excellent	8 (80.0%)	6 (60.0%)
Cost	Fair	0 (0.0%)	0 (0.0%)
	Good	0 (0.0%)	0 (0.0%)
	Very good	0 (0.0%)	4 (40.0%)
	Excellent	10 (100.0%)	6 (60.0%)

**Table 3:** Results of the questionnaire.

## DISCUSSION

Brow lifting whether done for cosmetic or functional complain still very common procedure within the patients seeking facial rejuvenation. Patient needs and desires with the presenting complain, anatomy of the periorbital area, eyebrow and lid shape and position, hairline, forehead morphology and type and depth of facial rhytids, all these factors have a great role in type of procedure to be done.<sup>7</sup>

Various authors have evaluated different eyebrow lifting techniques by using different fixed anatomical points and use their relationship to quantify the amount of change and to standardize the measurements.<sup>3</sup> In our study we used nasal ala, lateral brow, medial brow, lateral canthus) and lines passing through them to create NALB and NAMB to standardize follow up measurement.

*Mokhtarzadeh et al.*,<sup>8</sup> expressed in his study that lateral eyebrow was corrected by trans-blepharoplasty approach by 2.29 mm and 1.47 mm for the central brow. These results are in close similarity with what we achieved in our thesis. Performing Brassiere suture technique, also, amplifies the projection and improve fullness in the superior lateral part of the superior orbital rim, which provide long-lasting results after brow lift surgery according to *Li, et al.*,<sup>9</sup>.

As a result of the Brassiere suture technique with internal browpexy which is used in our thesis may validate the variance of the total and final amount of lift comparing the very narrow difference in results obtained and reported by other studies. In the context

of the follow up although the long-term effectiveness of a browpexy is questionable, our study suggests a brow lift persists during 6 months of follow-up, yet, with substantial amount of relapse, this is consistent between our result with *Zandi et al.*,<sup>10</sup> results.

Endoscopic approach with repositioning and reshaping of the eyebrow through suture fixation technique was mentioned and used by *Drolet et al.*,<sup>11</sup> in which he had stable result for a long follow up period and high patient satisfaction for the aesthetic outcome for the whole upper third of the face not only the eyebrows. In *Karimi et al.*,<sup>5</sup> narrative review about the brow lift he mentioned that endoscopic lift can give eyebrow elevation of 0.29 cm at the lateral canthus, 0.25 cm for the lateral limbus, 0.23 cm for the medial limbus, and 0.22 cm at the medial canthus after six months of follow up. However, with different fixation devices and techniques, the results obtained from different studies may alter, we think that our method with suture fixation through the eyebrow tissue to a cortical mini plate and screw fixation produce more lift, help with better eyebrow reshaping with multiple vectors through the number of sutures passing along and less prone to relapse as it is not dependent on forehead skin tension rather than suture fixation tension. It is worth mentioning that according to *Perenack*,<sup>12</sup> relapse of about 4 to 6 mm could be predicted subjected to the presentation of the ptotic brow and skin condition preoperatively, nevertheless we had less relapse in 6-month duration, a longer follow up may produce more relapse.

## CONCLUSION

Trans-blepharoplasty is best in lifting the eyebrow in mild cases which also complain of upper eyelid dermatochalasis, still there was considerable amount of relapse after 6 months of follow up, where Endoscopic approach is best utilized as a tool for brow reshaping along with lifting, although the relapse started as early as first month post operative and progressed gradually till 6 months post operative, yet the final amount of lift was satisfactory with the overall eyebrow shape.

## REFERENCES

1. Pelle-Ceravolo M and Angelini M. Transcutaneous Brow Shaping: A Straightforward and Precise Method to Lift and Shape the Eyebrows. *Aesthet Surg J*. 2017;37(8):863-75.
2. Foustanos A, Drimouras G and Panagiotopoulos K. Lateral Brow Lift: A Multi-Point Suture Fixation Technique. *Arch Plast Surg*. 2015;42(5):580.
3. Shadfar S and Perkins S. Surgical Treatment of the Brow and Upper Eyelid. *Facial Plast Surg Clin North Am*. 2015;23(2):167-183.
4. Shaw L and Phelps P. The basics of brow ptosis. *Disease-a-Month*. 2020;66(10):101038.
5. Karimi N, Bahmani Kashkouli M, Sianati H, et al. Techniques of Eyebrow Lifting: A Narrative Review. *Journal of Ophthalmic and Vision Research*. 2020;15(2): 218.
6. Broadbent T, Mohktarzadeh A and Harrison A. Minimally invasive brow lifting techniques. *Curr Opin Ophthalmol*. 2017;28(5):539-43.
7. Chi J. Periorbital Surgery. *Facial Plast Surg Clin North Am*. 2016;24(2):107-17.
8. Mokhtarzadeh A, Massry G, Bitrian E, et al. Quantitative efficacy of external and internal browpexy performed in conjunction with blepharoplasty. *Orbit*. 2017;36(2):102-9.
9. Li T, Zhang D, Li B, et al. A Technique for the Prevention of Recurrent Eyebrow Ptosis After Brow Lift Surgery. *Ann Plast Surg*. 2018;81(3):263-268.
10. Zandi A, Ranjbar-Omidi B and Pourazizi M. Temporal brow lift vs internal browpexy in females undergoing upper blepharoplasty: Effects on lateral brow lifting. *J Cosmet Dermatol*. 2017;17(5):855-61.
11. Drolet B, Phillips B, Hoy E, et al. Finesse in Forehead and Brow Rejuvenation. *Plast Reconstr Surg*. 2014;134(6):1141-50.
12. Perenack J. The Endoscopic Brow Lift. *Atlas Oral Maxillofac Surg Clin North Am*. 2016;24(2):165-73.