



4-1-2021

## TAP Block with dexamethasone as a Pain Treatment Modality after Lower Abdominal Gynecological Procedures

Abeer Farhat

*The Department of Anesthesia, Intensive Care & Pain Management, Faculty of Medicine for Girls, Al-Azhar University, Cairo, Egypt., f\_abeer@yahoo.com*

Mona Elkafrawy

*The Department of Obstetrics and Gynecology, Faculty of Medicine for Girls, Al-Azhar University, Cairo, Egypt., elkafrawym64@yahoo.com*

Doaa Effat

*The Department of Obstetrics and Gynecology, Faculty of Medicine for Girls, Al-Azhar University, Cairo, Egypt., doaaeffat4560@yahoo.com*

Follow this and additional works at: <https://aimj.researchcommons.org/journal>



Part of the [Medical Sciences Commons](#), [Obstetrics and Gynecology Commons](#), and the [Surgery Commons](#)

### How to Cite This Article

Farhat, Abeer; Elkafrawy, Mona; and Effat, Doaa (2021) "TAP Block with dexamethasone as a Pain Treatment Modality after Lower Abdominal Gynecological Procedures," *Al-Azhar International Medical Journal*: Vol. 2: Iss. 4, Article 2.

DOI: <https://doi.org/10.21608/aimj.2021.62238.1413>

This Original Article is brought to you for free and open access by Al-Azhar International Medical Journal. It has been accepted for inclusion in Al-Azhar International Medical Journal by an authorized editor of Al-Azhar International Medical Journal. For more information, please contact [dryasserhelmy@gmail.com](mailto:dryasserhelmy@gmail.com).

## TAP Block with Dexamethasone as a Pain Treatment Modality after Lower Abdominal Gynecological Procedures

Abeer E. Farhat<sup>1,\*</sup> MD., Mona E. Elkafrawy<sup>2</sup> MD. , Doaa M. Effat<sup>2</sup> MD.

### \* Corresponding Author:

Abeer E. Farhat  
f\_abeer@yahoo.com

Received for publication February 23, 2020; Accepted April 27, 2021; Published online April 27, 2021.

**Copyright** 2020 The Authors published by Al-Azhar University, Faculty of Medicine, Cairo, Egypt. All rights reserved. This an open-access article distributed under the legal terms, where it is permissible to download and share the work provided it is properly cited. The work cannot be changed in any way or used commercially.

doi: 10.21608/aimj.2021.62238.1413

<sup>1</sup>Department of Anesthesia, Intensive Care & Pain Management, Faculty of Medicine for Girls, Al-Azhar University, Cairo, Egypt.

<sup>2</sup>Department of Obstetrics and Gynecology, Faculty of Medicine for Girls, Al-Azhar University, Cairo, Egypt.

### ABSTRACT

**Background:** The transversus abdominis plane block (TAP block) can give a good analgesia after lower abdominal surgery. The administered local anesthetics determine the TAP block duration, so administration of adjuvants can be utilized to extend local anesthesia time and increase efficiency.

**Aim of the work:** To assess the efficacy of TAP block with dexamethasone on pain relief after lower abdominal gynecological procedures.

**Patients and methods:** A randomized controlled study was performed on 100 women, aged 25-56 years, ASA I&II. Listed for lower abdominal gynecological procedures under general anesthesia, TAP block was performed bilaterally at the end of surgery. Patients were randomly divided into two groups: Group I (n=50) bilaterally received 15ml of 0.2% levobupivacaine plus 1.5 ml normal saline. Group II (n=50) bilaterally received 15 ml of 0.2% levobupivacaine plus 1.5 ml) 6 mg (Dexamethasone. The primary outcome was visual analogue score (VAS) to assess postoperative pain. The secondary outcomes were the time to first analgesic request, number of patients needed meperidine, overall dose of analgesic consumption/24h and complications.

**Results:** VAS was significantly lower for 12h at rest and for 10h on activity in group II compared to group I (P<0.001), prolonged time to first analgesic request (P <0.001) and less meperidine requirement in group II (P <0.001).

**Conclusion:** Combination of dexamethasone and levobupivacaine in TAP block was effective in decreasing the severity of postoperative pain, overall meperidine consumption and prolonging the time to first analgesic request after lower abdominal gynecological procedures.

**Keywords:** Dexamethasone; Levobupivacaine; TAP block; gynecologic operations.

**Disclosure:** The authors have no financial interest to declare in relation to the content of this article. The Article Processing Charge was paid for by the authors.

**Authorship:** All authors have a substantial contribution to the article.

### INTRODUCTION

Lower Pfannenstiel incisions are the most usually utilized surgical procedures worldwide.<sup>1</sup> A Pfannenstiel is one type of abdominal incisions used for abdominal surgery.<sup>2</sup> It is used for gynecologic operations, orthopedic pelvic operations,<sup>3</sup> as well as Cesarean sections today. Pfannenstiel incision is used in hysterectomy operations<sup>4</sup>. Large uterine size is a common reason to do the abdominal hysterectomy as an enlarged uterus requires better visualization and exposure to avoid the risk of blood loss, injury to other organs, and long operative time.<sup>5</sup> Although laparoscopic operation is a less invasive technique, the surgical pain is predictable in the first 24h postoperative.<sup>6</sup>

Post-operative pain is the most common problem in medicine especially in obstetrics and gynecology operations. Adequate postoperative analgesia can enhance recovery and increase patient comfort and decrease Post-operative complications.<sup>7</sup>

TAP block can give a good analgesia after lower abdominal surgery.<sup>8</sup> The safety and success rate of the TAP block has increased with the use of ultrasound.<sup>9</sup> The ultrasound guided (USG) TAP block for pain relief after surgery is utilized as a modality in lower abdominal surgeries.<sup>10</sup>

The administered local anesthetics determine the TAP block duration, so administration of adjuvants can be utilized to extend the time of local anesthesia, also enhance the efficacy.<sup>11</sup>

Dexamethasone is a glucocorticoid that provides anti-inflammatory action. It extends the action time of local anesthetics when utilized in peripheral blocks as an adjuvant.<sup>12</sup>

Dexamethasone improves the efficacy and extends the time of the local anesthetic by inhibiting the discharge of inflammatory mediators, decreasing ectopic neuronal release and depressing potassium channel-mediated discharge of nociceptive C-fibers.<sup>13</sup>

Glucocorticoids have a direct impact on the nerve conduction; also they induce perineural vasoconstriction resulting in delayed absorption of local anesthetics used.<sup>14</sup>

The aim of this work is to assess the efficacy of TAP block with dexamethasone on pain relief after lower abdominal gynecological procedures.

## PATIENTS AND METHODS

After approval of local ethics committee and patient's written informed consent. A prospective randomized, controlled double-blinded study was performed at obstetrics and gynecology department of Al-Zahraa University Hospital from October 2018 to November 2019. Study included 100 women, American Society of Anesthesiologists physical status (ASA) I & II listed for elective lower abdominal gynecological procedures e.g. (hysterectomy; myomectomy; laparoscopy; ectopic pregnancy and ovarian cystectomy) under general anesthesia. Patients were excluded in case of refusal to participate in the study, history of allergy to the study drugs, uncontrolled hypertension, diabetes, cardiac disease, infection, coagulopathy, chronic pain and long-standing steroid therapy.

Pre-operative assessment was done for all women a day before operation.

All patients were trained on visual analogue score (VAS) during the preoperative assessment by anesthesia resident.

VAS, which was used for pain assessment is a horizontal line, 10 cm in length ranging from

0= (no pain) to 10= (worst pain).

The primary outcome was to assess postoperative pain scores using VAS at rest and on activity e.g. (cough, mobilization), immediately postoperative then every 2 hours in the next six hours, and at 10, 12, 18 and 24 hours. The secondary outcomes were time to first analgesic request, number of patients needed meperidine, overall dose of meperidine consumption and complications.

Patients were randomly allocated by computer generated number and sealed envelope technique into two groups: Group I (n=50): bilaterally received 15ml 0.2% levobupivacaine (Abbvie, Curida AS, Norway, Italy) plus 1.5 ml normal saline. Group II (n=50): bilaterally received 15 ml 0.2% levobupivacaine plus 1.5ml (6 mg) Dexamethasone (Amriya Pharmaceutical, Alexandria, Egypt). The medications for the TAP block were prepared by an anesthesia resident who was not a part of the study. Surgical technique:

Gynecological procedures were carried out by Pfannenstiel incisions. The incision is often 1-2 fingerbreadths above the pubic crest. 10-14 cm is enough incision, made via the subcutaneous tissue, fat to the fascia. The rectus muscle is dissected away from the fascia. and separated from each other. The peritoneum is incised to complete a Pfannenstiel

incision.<sup>15</sup> 2gm Cefazolin IV was taken before the surgery.

Assessment parameters: Hemodynamics Heart rate (HR) and mean arterial blood pressure (MAP) were recorded before induction of anesthesia and each 15 minutes through the time of operation, immediately post-operative then every two hours in PACU for next six hours and at 10, 12, 18 and 24 hours. VAS to assess postoperative pain scores at rest and on activity, time of first analgesic request, number of patients needed meperidine, overall dose of meperidine consumption/24h and complications were also recorded. Meperidine 30 mg IV was given when VAS  $\geq$  4 or patient request analgesia, can be repeated up to 3 times.

Bradycardia is defined as fall in HR < 60 b/min and managed by IV atropine (0.01mg/kg). Hypotension is defined as fall in MAP > 20% of baseline value and was managed by IV crystalloid solution and ephedrine 6mg IV increments. Nausea and vomiting were managed by ondansetron 8mg.

In operating theatre, 18-G peripheral intravenous cannula was inserted for all patients and ringer lactate solution (10ml/kg/h) was infused. Patient was connected to the standard monitor (Electrocardiography, heart rate (HR), non-invasive blood pressure, and pulse oximetry). Baseline readings were recorded. All patients were given general anesthesia after preoxygenation with fentanyl (1 $\mu$ g /kg), propofol (2 mg/kg) and cisatracurium (0.15 mg/kg) to facilitate endotracheal intubation. Anesthesia was maintained by sevoflurane (2%), oxygen: air mixture (1:1) and maintenance dose cisatracurium (0.03mg/kg) as required.

After the operation was done, ultrasound guided (USG) TAP block was performed under aseptic precaution, linear US probe (high frequency 6–13 MHz) was used to identify the abdominis muscle plane with Ultrasound Machine (Sonosite, M- Turbo, Fujifilm Sonosite, Inc, Washington, USA). The probe was placed in mid axillary line in the transverse plane to obtain a transverse view of abdominal layers, after visualization of abdominal layers; a 22 G/80 mm blunt needle was introduced medial to the probe and was advanced using in- plain technique between the internal oblique and transversus abdominis muscles. Accurate placement of tip of the needle was facilitated by injection of (2ml) saline to hydro dissect the appropriate plane. After negative aspiration 15 ml 0.2% levobupivacaine plus either 1.5 ml of normal saline in group I (n=50) or 1.5ml (6mg) dexamethasone in group II (n=50) was injected on each side, distribution of local anesthetic was detected by appearance of a hypoechoic fluid pocket immediately deep to the hyperechoic fascial plane between the internal oblique and transversus abdominis muscles. The injection was performed by an anesthesiologist who was blind to the composition of the injectate. After completion of surgery, muscle relaxant was antagonized by neostigmine (0.04 mg/kg) and atropine (0.01 ml/kg). Patient was extubated on meeting all criteria for extubation. Then patient was

transferred to Post-Anesthesia Care Unit for further monitoring.

Statistical analysis was done by SPSS v25 (IBM®, Armonk, NY, USA). Quantitative data were expressed as mean ± SD & Median, “Interquartile range (IQR). Qualitative data were expressed as number or percentage. comparison between two means was done by using Independent t-test. Mann Whitney z test for two-group comparisons in non-parametric data. p-value ≤0.05 was considered significant.

Sample size calculation: Prior to the study; the number of women needed per group was given after a power calculation depending on data collected (Fouad et al., 2016). In the study, VAS score at 12h movement in group I was 5.20±0.41 and Group II was 4.24±0.83, and a large effect size (f =0.3497). A sample size of 48 patients was determined in each group to give 80% power for independent samples T test at 5% significance level using G. Power 3.19.2 software.

**RESULTS**

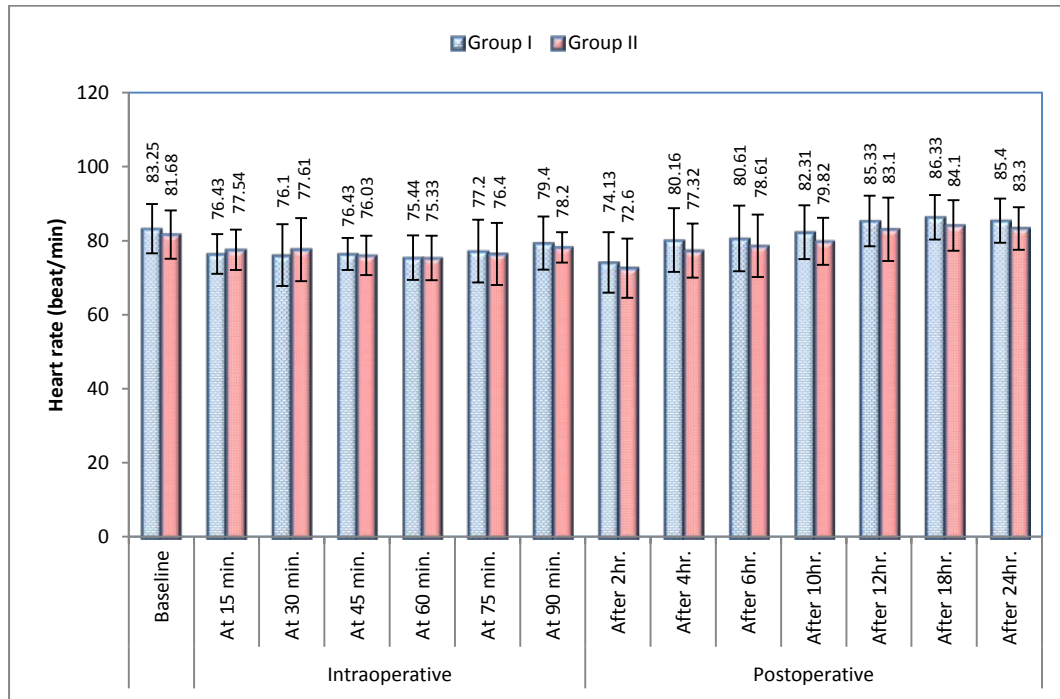
Demographic and operative data were comparable between both groups as shown in table (1).

Variable	Group I (n=50)	Group II (n=50)	Test value	P-value
Age (years)	33 ± 5.15	35 ± 7.22	1.5946•	0.114
Weight (kg)	76 ± 4.33	77 ± 5.1	1.0569•	0.2931
Height (cm)	165 ± 3.72	166 ± 4.26	1.2503•	0.2142
Types of operations:				
Hysterectomy	15 (30%)	14 (28%)	0.0486*	0.8256
Myomectomy	10 (20%)	12 (24%)	0.2331*	0.6292
Laparoscopy	10 (20%)	12 (24%)	0.2331*	0.6292
Ectopic Ovarian cystectomy	5 (10%)	4 (8%)	0.1221*	0.7268
Surgical duration (min)	80 ± 10.13	78 ± 12.3	0.8875•	0.3770
ASA				
I	33 (67%)	32 (63%)	0.044*	0.8339
II	17 (33%)	18 (37%)		

P-value <0.05: Significant(S). Data are presented as (Mean ± SD) or number (%).

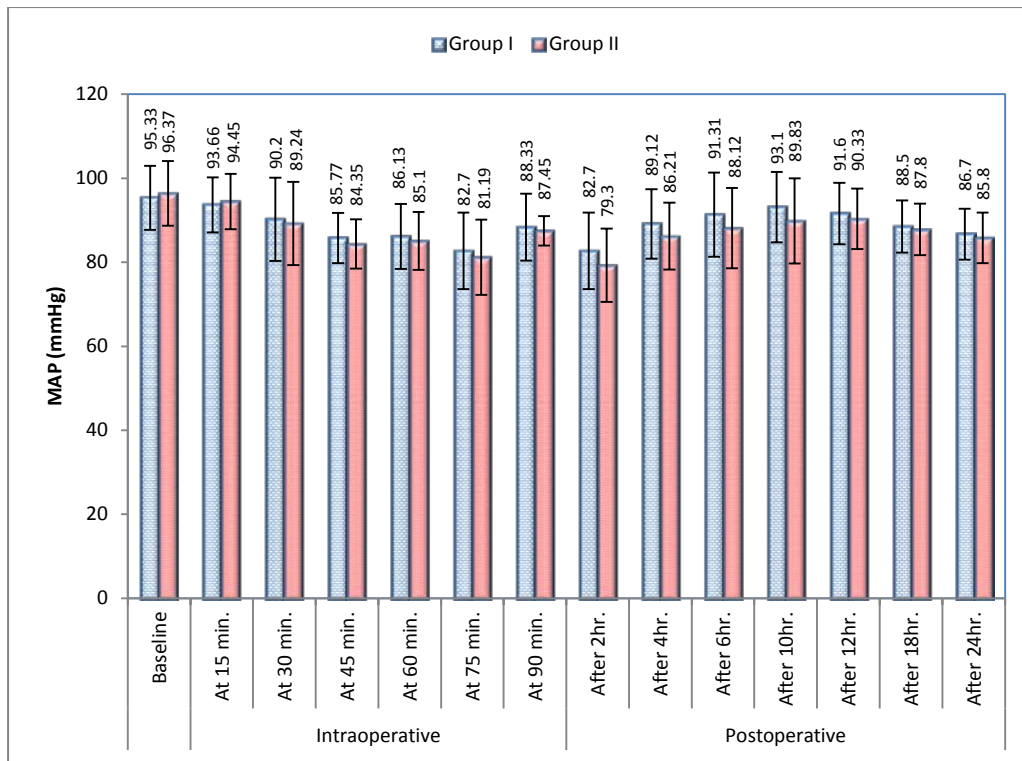
**Table 1:** Demographic and operative data in both groups.

There was no significant difference between both groups as regard HR at different times as shown in figure (1).



**Fig. 1:** Comparison between both groups as regard heart rate changes at different times. Data are presented as (Mean ± SD).

Regarding MAP (mmHg) we found no significant difference between both groups at different times as shown in figure (2)



**Fig. 2:** Comparison between both groups as regard MAP changes at different times. Data are presented as (Mean ± SD).

VAS scores at rest were significantly lower in group II compared to group I for 12hr postoperative as shown in Table (2).

VAS Rest	Group I (n=50)	Group II (n=50)	z-test	P-value
	Median (IQR)	Median (IQR)		
At 0hr.	1 (0-2)	0 (0-1)	2.414	0.045*
After 2hrs.	2 (1-4)	1 (0-2)	2.125	0.018*
After 4hrs.	3 (2-5)	1 (1-2)	2.315	0.011*
After 6hrs.	4 (3-7)	2 (1-3)	3.187	0.009*
After 10hrs.	6 (4-8)	3 (2-5)	3.316	0.008*
After 12hrs.	5 (3-7)	4 (2-5)	2.212	0.023*
After 18hrs.	3 (2-4)	3 (2-4)	0.485	0.631
After 24hrs.	3 (2-4)	3 (2-4)	0.513	0.396

**Table 2:** Comparison between both groups regarding VAS score at rest. Data are presented as Median (IQR).

VAS scores on activity were significantly lower in group II compared to group I for 10 hr. postoperative as shown in Table (3).

VAS Activity	Group I (n=50)	Group II (n=50)	z-test	P-value
	Median (IQR)	Median (IQR)		
At 0hr.	1 (0-2)	0 (0-1)	2.414	0.045*
After 2hrs.	2 (1-4)	1 (0-2)	2.315	0.011*
After 4hrs.	4 (3-7)	2 (1-3)	3.187	0.009*
After 6hrs.	5 (3-8)	3 (2-4)	3.279	0.004*
After 10hrs.	6 (4-8)	3 (2-4)	4.266	<0.001**
After 12hrs.	4 (3-7)	4 (3-6)	1.616	0.117
After 18hrs.	3 (2-4)	3 (2-4)	0.485	0.631
After 24hrs.	3 (2-4)	3 (2-4)	0.513	0.396

**Table 3:** Comparison between both groups regarding VAS score on activity. Data are presented as Median (IQR).

Time to first analgesic request was significantly longer in group II compared to group I (P<0.001), total dose of meperidine was less in group II (P<0.001) as shown in table (4).

Variable	Group I (No=50)	Group II (No=50)	Test value	P-value
Time of first analgesic request (hr.)	4.38 ± 1.08	10.24 ± 1.56	16.0483•	<0.0001
Total dose of meperidine (mg/patient)	60 ± 10.48	30 ± 5.43	13.2070•	<0.0001
Number of patients requiring meperidine	48 (96%)	10 (20%)	59.2775*	<0.00001

**Table 4:** Comparison between both groups as regard analgesic consumption. Data are presented as (Mean ± SD) or number (%).

Side effects	Group I (No=50) No. %	Group II (No=50) No %	Test value	P-value
Nausea	6 (12%)	2 (4%)	2.1739*	0.1404
Vomiting	4 (8%)	2 (4%)	0.7092*	0.3997
Hypotension	4 (8%)	2 (4%)	0.7092*	0.3997
Shivering	4 (8%)	2 (4%)	0.7092*	0.3997

**Table 5:** Comparison between both groups regarding side effects. Data are presented as number (%).

## DISCUSSION

Adequate postoperative pain relief can enhance recovery and increase patient satisfaction<sup>13</sup>.

USG TAP block for postoperative pain relief is more often utilized as a modality in lower abdominal operations<sup>12</sup>. In this study we assess the impact of USG TAP block when adding dexamethasone to levobupivacaine on postoperative pain on 100 women, ASA I&II, listed for lower abdominal gynecological procedures under general anesthesia regarding VAS, time before first requested analgesia, number of patients needed meperidine, total dose of meperidine consumption postoperative, and complications.

Regarding postoperative pain scores measured by VAS there was significantly lower in VAS for 12 h at rest and for 10 h on activity with group II compared to group I. This reflects the ability of dexamethasone to improve the efficacy and extend the time of the local anesthetic, this may be explained by dexamethasone inhibiting the discharge of inflammatory mediators, decreasing ectopic neuronal release, depressing potassium channel-mediated discharge of nociceptive C-fibers.<sup>13</sup>

The result of the present study is matching with the results conducted by Amany and Mahmoud<sup>16</sup> who studied sixty females undergoing abdominal hysterectomy and demonstrated that combination of dexamethasone to bupivacaine in TAP block significantly reduced VAS score over 48h postoperative.

Nareman and Mohamed<sup>17</sup> reported that addition of dexamethasone to bupivacaine in TAP block prolonged the analgesic effect of TAP block by

significantly reducing VAS score over 48 h postoperative.

Liu et al.<sup>18</sup> reported that resting postoperative VAS scores were less in dexamethasone group compared to ropivacaine group; dexamethasone with ropivacaine can extend the time and accelerate the analgesic effect of ropivacaine.

Gnanasekar et al.<sup>19</sup> recorded that addition of dexamethasone to ropivacaine was significantly improved the analgesic effect of the drug with significant decrease in pain scores. Akkaya et al.<sup>20</sup> & Gülhaş et al.<sup>21</sup> reported lower postoperative pain scores when adding dexamethasone to USG TAP block.

Gupta et al.<sup>22</sup> studied 90 patients, with TAP block after cesarean sections; demonstrated that VAS scores were significantly less in dexamethasone group than ropivacaine group, usage of dexamethasone with ropivacaine increases the analgesic time of TAP block in women subjected to cesarean sections.

Vetriselvan et al.<sup>23</sup> studied the impact of dexamethasone on analgesic efficacy of TAP block in laparoscopic gynecological operations and concluded that administration of dexamethasone with levobupivacaine enhances the quality of analgesia in women subjected to bilateral TAP block.

On the other hand, Wegner et al.<sup>8</sup> studied the impact of dexamethasone as adjuvant to ropivacaine in TAP block for patients undergoing inguinal hernia repair and spermatocelectomy and found that no significant prolongation of TAP blocks with 0.2% ropivacaine when (8mg) dexamethasone was added. Regarding the time of first rescue analgesia; we found significant increase in the time to first analgesic request with group II compared to group I. This may be explained by direct effect of glucocorticoids on the nerve conduction; perineural vasoconstriction resulting in slower absorption of the local anesthetics used.<sup>13,14</sup>

Vetriselvan et al.<sup>23</sup> found prolongation in the time needed for first analgesia in perineural group as compared to IV group.

The results go along with the results given by Seervi et al.<sup>24</sup> who reported that time before first requested analgesia was significantly increased with dexamethasone and buprenorphine groups compared to control group.

Gupta et al.<sup>22</sup> demonstrated that time to first rescue analgesia was significantly less in Ropivacaine group compared to dexamethasone group.

Parrington et al.<sup>25</sup> reported that the time of analgesia was significantly longer in dexamethasone group compared to bupivacaine group.

As respect to overall dose of meperidine consumption, it was significantly lower in group II in contrast to group I. This may be explained by

anti-inflammatory effect of steroid or a combination of dexamethasone with levobupivacaine has a synergistic effect. The same result was observed by Amany and Mahmoud.<sup>16</sup> who demonstrated longer time of first analgesic request and less postoperative opioid required in dexamethasone group in contrast to bupivacaine group. The study results go along with the study of Kartalov et al;<sup>13</sup> who demonstrated reduction of morphine consumption in 24h postoperative in dexamethasone group. Also, we go along with the study results of Fouad et al;<sup>11</sup> Gnanasekar et al;<sup>19</sup> Seervi et al;<sup>24</sup> and Akkaya et al;<sup>20</sup>

Regarding the hemodynamics; we found no significant difference between group I and group II at different times of the observation period.

This study results go along with the study results of Seervi et al;<sup>24</sup>

Nareman et al;<sup>17</sup> noticed that analgesic impact of TAP block improved the hemodynamics post hysterectomy operation. On contrary, Gupta et al;<sup>22</sup> reported that post-operative hemodynamics were significantly higher in Ropivacaine group than Dexamethasone group.

As regards side effects; our results presented by nausea and vomiting in 10 patients (20%) in group I versus 4 patients (8%) in group II and 4 (8%) patients versus 2 (4%) patient having hypotension or shivering.

Gupta et al;<sup>22</sup> demonstrated that incidence of nausea was more in Ropivacaine group than Dexamethasone group; there was no observation of vomiting or any other block-related complication in any patient. Fouad et al;<sup>11</sup> reported less incidence of nausea and vomiting with dexamethasone group than bupivacaine group. Vetrivelan et al;<sup>23</sup> recorded no nausea and vomiting; this may be due to less opioid intake and antiemetic effect of dexamethasone.

## CONCLUSION

Combination of dexamethasone and levobupivacaine in TAP block was successful in decreasing the severity of postoperative pain, overall analgesic consumption and prolonging the time to first analgesic request after lower abdominal gynecological procedures.

## REFERENCES

- Demir B, Senerbahce Z, Guzel AI, et al. Abdominal wall endometriosis following cesarean section: report of five cases. *Clin Exp Obstet Gynecol*. 2011; 38(3):288-90.
- Vitale SG, Marilli I, Cignini P, et al. Comparison between modified Misgav-Ladach and Pfannenstiel-Kerr techniques for Cesarean section: review of literature. *Journal of prenatal medicine*. 2014;8(3-4):36-40.
- Hoffman B, Schorge J, Schaffer J, et al. Cunningham. (2012-04-12). Williams Gynecology, Second Edition. McGraw Hill Professional. ISBN 9780071716727.
- Laberge P, Leyland N, Murji A, et al. Endometrial ablation in the management of abnormal uterine bleeding. *J Obstet Gynaecol Can*. 2015; 37(4):362-79.
- Ito TE, Vargas MV, Moawad GN, et al. Minimally Invasive Hysterectomy for Uteri Greater Than One Kilogram. *JSLs*. 2017; 21(1) 1-7.
- Ekstein PP, Szold A, Sagie B, et al. Laparoscopic surgery may be associated with severe pain and high analgesia requirements in the immediate postoperative period. *Ann Surg* 2006; 243:41-6.
- Deelereq F, Cunningham DK, Johnson C, et al. Mothers' reports of postpartum pain associated with vaginal and cesarean deliveries. Results of a national survey. *Birth J* 2008; 35:16-24.
- Wegner R, Akwar D, Reyes S, et al. Evaluating the adjuvant effect of dexamethasone to ropivacaine in transversus abdominis plain block for inguinal hernia repair and spermatocelectomy: A Randomized control trial. *Pain Physician* 2017; 20:413-18.
- Hebbard P, Fujiwara Y, Shibata Y, et al. Ultrasound-guided transversus abdominis plain (TAP) block. *Anaesth Intensive Care*. 2007;35:616-7.
- Abdallah FW, Halpern SH and Margarido CB. Tran versus abdominis plain block for postoperative analgesia after caesarean delivery performed under spinal anesthesia. A systemic review and metaanalysis. *Br J Anesth* 2012; 109: 679-87.
- Fouad H A, Sabry AM, Mohammed YM, et al. Efficacy of preemptive dexamethasone added to bupivacaine in ultrasound guided trasversus abdominis plain block for post-operative analgesia after inguinal herniorrphy. *American journal of Research Communication*. 2016; 4(5):27-41.
- Rasmussen SB, Saied NN, Bowens C, et al. Duration of upper and lower extremity peripheral nerve blockade is prolonged with dexamethasone when added to ropivacaine: a retrospective database analysis. *Pain Medicine*. 2013; 14(8):1239-47.
- Kartalov A, Jankulovski N, Kuzmanovska B, et al. Effect of adding dexamethasone as a ropivacaine adjuvant in ultrasound-guided transversus abdominis plane block for inguinal hernia repair. *Pril (Makedon Akad Nauk Umet Odd Med Nauki)* 2015; 36:35-41.
- Shishido H, Kikuchi S, Heckman H, et al. Dexamethasone decreases blood flow in normal nerves and dorsal root ganglia. *Spine*. 2002; 27: 581-6.
- Robert VH and Warner KH. Abdominal Incisions and Sutures in Gynecologic Oncological Surgery Updated: Nov 30, 2016. <https://emedicine.medscape.com/article/271349-overview>.
- Amany SA and Mahmoud KM. Effect of adding dexamethasone to bupivacaine on transversus

- abdominis plane block for abdominal hysterectomy: A prospective randomized controlled trial. *Saudi J Anaesth.* 2012; 6(3): 229–33.
17. Nareman E and Mohamed GE. Ultrasound guided TAP block by using Bupivacaine alone or when mixed with dexamethasone or dexmedetomidine for pain relief Among abdominal hysterectomy patients. *JGWH.* 2020; 5(3): 70-7.
  18. Liu HL, Zhou RH, Luo LL, et al. Ultrasound-guided transversus abdominis plane block for cesarean delivery: injection site pain as a new complication and dexamethasone reduced incidence. *Journal of Pain Research.* 2020; 13:565.
  19. Gnanasekar N, Kumar G D, Kurhekar P, et al. Comparative evaluation of ropivacaine and ropivacaine with dexamethasone in transversus abdominis plane block for lower abdominal surgery: A prospective randomized double-blind study. *Anesthesia Essays Res.* 2018;12: 937-42.
  20. Akkaya A, Yildiz I, Tekelioglu UY, et al. Dexamethasone added to levobupivacaine in ultrasound-guided transversus abdominis plain block increased the duration of postoperative analgesia after caesarean section: a randomized, double blind, controlled trial. *Eur Rev Med Pharmacol Sci* 2014; 18: 717-22.
  21. Gülhaş N, Kayhan G, Şanlı M, et al. Effect of Adding Dexamethasone to Bupivacaine on Transversus Abdominis Plane Block [Transversus Abdominis Plane Bloğa Eklenen Deksametazonun Etkisi] [doi: 10.5455/medscience.2015.04.8272](https://doi.org/10.5455/medscience.2015.04.8272).
  22. Gupta A, Gupta A and Yadav N. Effect of dexamethasone as an adjuvant to ropivacaine on duration and quality of analgesia in ultrasound-guided transversus abdominis plane block in patients undergoing lower segment cesarean section-A prospective, randomised, single-blinded study. *Indian Journal of Anaesthesia.* 2019; 63(6):469.
  23. Vetrivelvan P, Mandal B, Bhatia N, et al. Effect of dexamethasone on analgesic efficacy of transverse abdominis plane block in laparoscopic gynecological procedures: A prospective randomized clinical study. *Journal of anaesthesiology, clinical pharmacology.* 2019; 35(2):165.
  24. Seervi SN, Singariya G, Kamal M, et al. Effect of addition of buprenorphine or dexamethasone to levobupivacaine on postoperative analgesia in ultrasound guided transversus abdominis plane block in patients undergoing unilateral inguinal hernia repair: a prospective randomized double blind controlled trial. *Korean journal of anesthesiology.* 2019 Jun;72(3):245.
  25. Parrington SJ, O'Donnell D, Chan VW et al. Dexamethasone added to mepivacaine prolongs the duration of analgesia after supraclavicular brachial plexus blockade. *Regional Anesthesia & Pain Medicine.* 2010; 35(5):422-6.