



9-1-2020

## Ultrasound Guided Subcostal Transversus Abdominis Plane Block For Postoperative Analgesia After Laparoscopic Cholecystectomy ( comparative Study Between Bupivacaine Versus Bupivacaine-Ketamine)

Ahmed Ahmed

faculty of medicine alexandria university, ahmedmedhat8765@gmail.com

Follow this and additional works at: <https://aimj.researchcommons.org/journal>



Part of the [Medical Sciences Commons](#), [Obstetrics and Gynecology Commons](#), and the [Surgery Commons](#)

### How to Cite This Article

Ahmed, Ahmed (2020) "Ultrasound Guided Subcostal Transversus Abdominis Plane Block For Postoperative Analgesia After Laparoscopic Cholecystectomy ( comparative Study Between Bupivacaine Versus Bupivacaine-Ketamine)," *Al-Azhar International Medical Journal*: Vol. 1: Iss. 9, Article 12.  
DOI: <https://doi.org/10.21608/aimj.2020.27457.1190>

This Original Article is brought to you for free and open access by Al-Azhar International Medical Journal. It has been accepted for inclusion in Al-Azhar International Medical Journal by an authorized editor of Al-Azhar International Medical Journal. For more information, please contact [dryasserhelmy@gmail.com](mailto:dryasserhelmy@gmail.com).

## Ultrasound Guided Subcostal Transversus Abdominis Plane Block For Postoperative Analgesia After Laparoscopic Cholecystectomy ( Comparative Study Between Bupivacaine Versus Bupivacaine-Ketamine)

Ahmed Medhat Ahmed Abd El-Aatty<sup>1,\*</sup> MSc, Tarek Munir Mahmoud<sup>2</sup> MD,  
Abd EL-Wahab Abd El-Sattar Saleh<sup>1</sup> MD

### \*Corresponding Author:

Ahmed Medhat Ahmed Abd El-Aatty  
[ahmedmedhat8765@gmail.com](mailto:ahmedmedhat8765@gmail.com)

Received for publication April 7, 2020; Accepted October 12, 2020;  
Published online October 12, 2020.

**Copyright** 2020 The Authors published by Al-Azhar University, Faculty of Medicine, Cairo, Egypt. All rights reserved. This an open-access article distributed under the legal terms, where it is permissible to download and share the work provided it is properly cited. The work cannot be changed in anyway or used commercially.

doi: 10.21608/aimj.2020.27457.1190

<sup>1</sup>Anesthesia and Intensive Care Department, Damanhour Medical National Institute, Egypt.

<sup>2</sup>Anesthesia and Intensive Care Department, Faculty of Medicine, Al-Azhar University, Cairo, Egypt.

### ABSTRACT

**Background:** Laparoscopic cholecystectomy is the surgery to remove the gall bladder and is the common treatment of symptomatic gall stone and other GB conditions. Laparoscopic cholecystectomy can be carried out under general anaesthesia that is often related to chronic postoperative pain.

**Aim of work:** Study Compares between adding ketamine to bupivacaine and bupivacaine alone for postoperative pain in patients undergoing ultrasound guided subcostal transversus abdominis plane block (TAPB) after laparoscopic cholecystectomy; time of first application for extra analgesia, pain Ratings, gross analgesic intake and analgesic effectiveness.

**Patient and Methods:** This research was performed out on 28 patient's ages 30 to 60 years at Al-Azhar University hospital. Class I-II American Anesthesiologist Society (ASA) scheduled for laparoscopic cholecystectomy. Patients were randomized, monitored double blind into two similar groups (fourteen people each).

**Results:** The Comparison between the two studied groups was statistically insignificant according to the period before first opioids demand, the block length, opioids demand, early ambulation, patient's satisfaction and occurrence of vomiting and nausea. As regarding patient complication there was no local anaesthetic toxicity in both groups of hematoma or severe tissue damage at the injection site.

**Conclusion:** Adding of ketamine to bupivacaine in patients with ultrasound-guided subcostal TAPB for laparoscopic cholecystectomy results in statistically insignificant in the following: longer span before first opioid requirement and prolonged block duration, less opioid demand, early ambulation and the patient is being more satisfied.

**Keywords:** Bupivacaine, Bupivacaine-Ketamine; Ultrasound; Analgesia; Laparoscopic Cholecystectomy

**Disclosure:** The authors have no financial interest to declare in relation to the content of this article. The Article Processing Charge was paid for by the authors.

**Authorship:** All authors have a substantial contribution to the article.

### INTRODUCTION

Postoperative pain after laparoscopic cholecystectomy leads to a greater use of analgesics and raise the need for rescue analgesics that increase the risk of side effects; particularly, emesis, respiratory distress and anaesthesia that may result in higher stay in the hospital and therapy that decreases the benefits of fast-track operation. Sufficient postoperative medication is correlated with beneficial long-term outcomes for patients like decreased postoperative cognitive changes, enhanced way of life and decreased risk of chronic or persistent postoperative pain.<sup>1</sup>

Therapy for postoperative pain following abdominal surgery is focused on traditional medicines which consist of paracetamol, NSAID and oral or intravenous opioids. These drugs are correlated with negative outcomes such as hypotension sedation,

nausea, and elevated heart load. All negative impacts delay the early discharge and recovery. The function of subcostal transverse abdominal block with local anaesthetic and adjuvant can also be added to this for postoperative pain relieve.<sup>2</sup>

Rafi first described the transversus abdominis plane (TAP) block<sup>3</sup>. By injecting local anaesthetic into the abdominal muscle, it allows pain management by blocking sensory nerves. This method can trigger an improper block, as the position of the needle may not be accurate. There have also been fatal complications such as bowel puncture and liver injury.<sup>4</sup>

Lately, ultrasound-guided subcostal transverse abdominal plane block techniques have been widely utilized to prevent blind procedure complications and to provide better control of a range of postoperative pain following LAP cholecystectomy. Currently it is

used more often as a substitute in upper abdominal surgeries.<sup>5</sup>

Bupivacaine hydrochloride has been employed as a local anaesthetic and is accessible by systemic penetration, caudal, lumbar epidural block, peripheral nerve block and TAP block in sterile isotonic injection solutions. Constant studies are carried out to establish the contribution of different adjuvants on quality improvement and to decrease the period of local anaesthetic action in various peripheral nerves and regional block strategies.<sup>6</sup>

The inclusion of adjuvants as alpha 2 adrenoceptor agonists as clonidine, dexamethasone, adrenaline, midazolam, tramadol, ketamine, adenosine, opioids and NSAID to local anaesthetic medicines in transversus abdominis plane block and their efficacy has been studied.

Ketamine can be utilized for postoperative pain relief. Low-dose ketamine can minimize nausea and vomiting following surgery due to use of morphine. It can also be utilized as an opiate-intravenous analgesic to treat otherwise intractable pain, especially when this pain is neuropathic. Ketamine is the most effective analgesic when used in conjunction with a low-dose opioid, and although it has analgesic impacts on its own, the dosage needed for sufficient pain relief when used as the primary analgesic agent are significantly greater and are much greater likely to cause unnerving side effects.<sup>6</sup>

This research aims to assess the application of ketamine to bupivacaine and bupivacaine alone for postoperative pain in patients receiving ultrasound guided subcostal TAPB after laparoscopic cholecystectomy regarding; time of initial application for further analgesia, pain ratings, gross analgesic intake and analgesic effectiveness.

## PATIENT AND METHODS

This Following the approval of the local ethics committee and informed written consent of every participant, this study was performed in the Al-Azhar University Hospital on 28 adult patient 30-60 years of age. American society of anesthesiologists ASA 1 or 2 for labaroscopic cholecystectomy.

Exclusion criteria were patient refusal, BMI more than 25 kg per square meter, diabetic patients, and patients unable to accurately explain postoperative pain to inspectors (delirium, dementia, psychological and neurological disorders), preoperative opioids, coagulopathy, or NSAIDS, and allergies or anaesthetic agents or contraindication to studied drug.

Participants were randomized and double-blind controlled in two equivalent groups (14 participants each) based on the adjuvant applied to the local anaesthetic in the ultrasonographically performed Subcostal TAP block. The Participants were selected randomly by a colleague without knowing the groups and I had taken the data and followed up first dose required.

Group 1: The patients were received mixture of 20 ml 0.5% bupivacaine and 2 ml of normal saline which conducted in the Subcostal TAP block with US guidance on the right side.

Group 2: The patients were received mixture of 20 ml 0.5 % bupivacaine with 0.5 mg/kg ketamine (total volume of ketamine 2 ml ) which administered in subcostal TAP block performed with US guided at the right side.

Pre-operative assessment and preparedness:

Patient assessment was conducted by thorough history taking, clinical review and routine lab tests (full blood count, bleeding duration, coagulation duration, PT, PTT, INR, creatinine, urea, ALT, AST, and blood sugar level). ECG in patients older than 40 years.

All patients were were told of the U.S. guided subcostal TAP block protocol and were instructed to use the VAS scale.

Pre-anesthetic and premedication:

Nothing a month for 6 hours prior to the surgery, midazolam was premedicated two minutes before anaesthesia in all patients (0.02 mg / kg) IV and a peripheral line cannula (20 G) was inserted in all patients upon admission to the operating room.

The patient was connected to a multichannel monitor for continuous monitoring of the electrocardiography of the heart rate (beat/min), noninvasive arterial blood pressure (NABP) and peripheral oxygen saturation (SPO2 %). Baseline outcome indicators (heart rate, oxygen saturation and blood pressure) have been used.

Intraoperative proceedings:

The same surgeons performed all the operations. After the induction of general anaesthesia, ultrasound guided subcostal TAP blocks with the same technique were made for all patients.

Anesthetic technique:

In both groups, general anaesthesia was caused as follows: Patients were positioned in supine posture and pre-oxygenated with 100% oxygen by face mask of anesthetic breathing system for three minutes. Induction of anesthesia was conducted with intravenous fentanyl (1µg.kg-1) and propofol (2mg.kg-1) administered progressively until contact loss and cisatracurium (0.15mg.kg-1) IV to ease endotracheal intubation using Macintosh laryngoscope of sufficient size. Patients were mechanically ventilated and isoflurane was used to maintain anaesthesia (1.2–1.5%) in 100% oxygen and cisatracurium incremental doses (0.03mg kg<sup>-1</sup>). Subcostal TAP block guided ultrasound was then performed for all patients.

Subcostal TAP block guided ultrasound technique : (Hebbard, 2007)

All the patients were in a supine posture. The abdominal wall was examined after skin disinfection using a multi-beam (6–13 MHz) linear array transducer probe attached to a portable ultrasound

unit (Sonosite M-Turbo). A sterile plastic transducer sheath (Tegaderm) covered the edge of the probe, and a sterile gel added to the skin.

On the upper abdominal wall, along the subcostal margin near the midline, a high frequency ultrasound probe is positioned obliquely. The dot of ultrasound direction was on the lateral side. Rectus abdominis muscle is first defined. Then the ultrasound probe is progressively pushed along the subcostal margin, laterally and obliquely and the muscle of the transversus abdominis may be identified posterior to the muscle of the rectus.

After identification of the neurofacial plane among the rectus abdominal and transverse abdominal muscles, the skin and subcutaneous tissues of the probe are anaesthetized with 1% lignocaine. The block needle is then positioned anteriorly in the ultrasound beam plane at the lateral side of the probe below the dot.

The transducer was shifted throughout insertion with careful manipulation to constantly visualise the shaft, the tip of the needle and the aforementioned structures which were the muscle of the rectus abdominis and the muscle of the transversus abdominis. Saline 0.9% (1 ml) was injected with tiny in-and-out motions to optimize the tip position. When the tip was on the target plane properly positioned, The needle was directed to approach the transversus abdominis plane and on entering the facial plane, 20 ml of 0.5% bupivacaine with 2 cm normal saline( total volume = 22 cm) OR 20 ml of 0.5% bupivacaine with 0.5 mg/kg ketamine( total volume =22 cm) was injected after negative aspiration. The injectate could be seen spreading like a dark oval pocket in the transversus abdominis plane.

Inhalation anaesthesia was halted at the end of the operation; the residual neuromuscular block was antagonized with neostigmine 0.04 mg kg<sup>-1</sup> and atropine 0.01 mg kg<sup>-1</sup> and then extubed and moved the post-operative care unit. In both groups of patients with ketorolac 30 mg intravenously every 6 hours analgesia was controlled postoperatively. In the case of a visual analogue scale (VAS), a rescue dose of nalbuphine 4 mg was administered.

#### Postoperative complications:

Any postoperative complications that occur at any time during the study's 24 hours were observed, registered, and treated accordingly, like: Local anesthetic toxicity (tinnitus, peri-oral numbness and seizures) , post-operative vomiting and nausea, hemodynamic instability (tachycardia  $\geq 100$  beats/minute and bradycardia  $< 60$  beats/minute, blood pressure  $\leq 20$  % of normal), arrhythmias, hematoma at the injection site.

#### Statistical analysis:

Reported data were analyzed using the Statistical Package for Social Sciences, version 20.0 (SPSS Inc., Chicago, Illinois, USA). Quantitative data is expressed as mean  $\pm$  standard deviation (SD). It expressed qualitative data as frequency and percentage.

The following tests were carried out: Independent-samples t-test of significance was utilized when compared among two ways, chi-square ( $\chi^2$ ) test of significance was utilized to compare the ratios among two qualitative parameters and the confidence interval was set at 95 % and the agreed margin of error was set at 5 %. The p-value was regarded substantial as the following possibility (P-value): P-value  $< 0.05$  was considered significant, P-value  $< 0.001$  was deemed extremely significant and P-value  $> 0.05$  was regarded insubstantial.

For each group (14 patients) sample size calculation was 12 where the confidence level was 95% and the margin of error (precision rate) was 0.1.

## RESULTS

This study was performed out on 28 patient's ages 30 to 60 years at Al-Azhar University hospital, Class ASA I or II for elective laparoscopic cholecystectomy.

The technique was successfully performed with no technical problems in 28 cases and were included in the subsequent statistical analysis.

	Group 1 (n = 14)	Group 2 (n = 14)	T	P
Age/years				
Min. –	31.0 –	30.0 –		
Max.	52.0	54.0	0.890	0.381
Mean $\pm$	40.71 $\pm$	43.21 $\pm$		
SD.	6.60	8.17		
BMI/kg/m <sup>2</sup>				
Min. –	25.0 –	25.30 –		
Max.	29.90	29.80	0.890	0.381
Mean $\pm$	27.30 $\pm$	27.03 $\pm$		
SD.	1.70	1.22		

t: Student t-test

P:P value comparing between the two groups statistically significant at  $P \leq 0.05$

Min: minimum SD: standard deviation

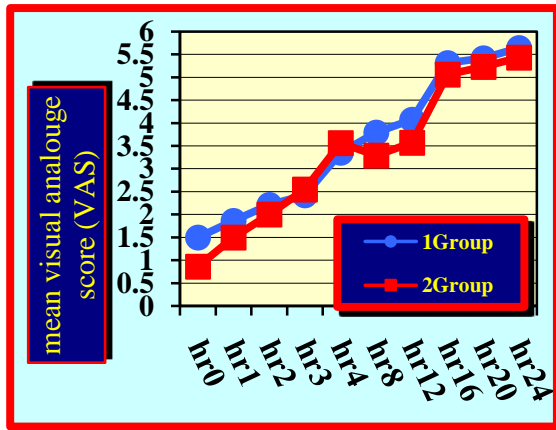
Max: maximum

**Table 1:** Comparison of the two groups studied as to the demographic data.

Age (year): The age of group 1 was ranged between 31 to 52 years with a mean of  $40.71 \pm 6.60$  years while the age of group 2 was ranged between 30 to 54 years with a mean of  $43.21 \pm 8.17$  years and the statistical analysis revealed no statistically significant differences among the two groups regarding to age (p value was 0.381). Table (1)

Body mass index (BMI) (kg/m<sup>2</sup>): BMI of patients in group 1 ranged between 25 – 29.90 with a mean of  $27.30 \pm 1.70$  Kg/m<sup>2</sup>. while BMI of patients in group 2 ranged between 25.30 – 29.80 with a mean of  $27.03 \pm 1.22$  kg/m<sup>2</sup> and the statistical analysis revealed no major statistical variations between both groups regarding BMI (p value was 0.381). Table (1).

Changes in visual analogue scale (VAS)



**Fig 1:** Comparison of the two groups studied as regards VAS  
 No substantial difference was noted in VAS in both group 1 and group 2 when measured post-operative at 0h, 1h, 2h, 3h, 4h, 8h, 12h, 16h, 20h and 24h (P = 0.070, 0.266, 0.275, 0.346, 0.239, 0.097, 0.220, 0.317, 0.364 and 0.238 respectively). Figure(1).

Time till 1 <sup>st</sup> opioid dose (min)	Group I (n = 14)	Group II (n = 14)	T	P
Min – Max	190.0 – 315.0	200.0 – 325.0		
Mean ± SD.	271.86 ± 33.74	283.9 ± 34.09	0.942	0.355

T: Student t-test  
 P: P value comparing between the two groups statistically significant at P ≤ 0.05  
 SD: Standard Deviation      Min: Minimum  
 Max: Maximum

**Table 2:** Comparison of the two groups studied as regards time till 1st opioid dose.  
 No substantial differences were identified among the two studied groups regarding time elapsed till 1st rescue analgesic dose (p=0.355). Table (2)

Duration of analgesia (min)	Group 1 (n = 14)	Group 2 (n = 14)	T	P
Min – Max	240.0 – 375.0	265.0 – 365.0		
Mean ± SD.	330.7 ± 35.73	342.14 ± 33.84	0.869	0.393

T: Student t-test  
 P: P value comparing between the two groups statistically significant at P ≤ 0.05  
 SD: Standard Deviation      Min: Minimum  
 Max: Maximum

**Table 3:** Comparison of the two groups studied as regards analgesic duration.

No substantial differences were found among the two groups examined as to the duration of the analgesia, the mean of group 1 was 330.7 ± 35.73 minutes while in group 2 it was 342.14 ± 33.84 minutes (p=0.393). Table (3)

Total opioid dose (mg)	Group 1 (n = 14)	Group 2 (n = 14)	T	P
Min – Max	20.0 – 32.0	18.0 – 30.0		
Mean ± SD.	25.14 ± 3.30	23.43 ± 3.27	1.379	0.180

T: Student t-test  
 P: P value comparing between the two groups statistically significant at P ≤ 0.05  
 SD: Standard Deviation      Min: Minimum  
 Max: Maximum

**Table 4:** Comparison of the two groups studied as total opioid dose.  
 No substantial differences were identified among the two studied groups regarding total opioid dose consumption, the mean of group 1 was 25.14 ± 3.30 mg while in group 2 it was 23.43 ± 3.27 mg (p=0.180). Table (4).

### DISCUSSION

The goal of this work was to assess the impact of adding ketamine to bupivacaine on postoperative pain in patients undergoing subcostal TAPB guided with ultrasound in laparoscopic cholecystectomy as regard; first order period for more analgesia, pain ratings, total analgesic consumption and analgesic efficacy.

This research was carried out on 28 patient's ages 30 to 60 years at Al-Azhar University hospital. Class I - II American society of anesthesiologists (ASA) scheduled for elective laparoscopic cholecystectomy. Outcomes of the current research found that a balance between the two groups of demographic data (age, sex, and BMI).

In this study there were insignificant intraoperative or postoperative changes (MABP, HR, SPO2%) compared to the preoperative value in both groups. Comparison of vital signs at various periods of MABP, HR, and SPO2 percent revealed statistically insignificant differences among the two groups. Many studies have shown results that are in line with the current study findings.

Study about ultrasound guided subcostal TAPB was performed by Nira et al. <sup>7</sup>. This study showed that Subcostal TAPB is a modern technique of regional anaesthesia that provides analgesic following upper abdominal surgery. The technique requires injection of a single shot into neurofacial plane between the rectal abdominal muscle and the transverse abdominal muscle which can provide dynamic analgesia for 6 to 8 hours. This study is in line with our study since the length of analgesia in both groups is about 6 hours.

Another study was performed by Solizet al. <sup>8</sup> showed that although Subcostal TAPB does not include visceral analgesia and is subject to anatomical variations in the distribution of sensory nerves on the abdominal wall; it looks promising as a useful tool in acute pain management and as part of multimodal analgesic methods. The block in patients undergoing

upper abdominal surgery was shown to provide excellent pain relief. The subcostal TAPB can provide appropriate analgesia for major abdominal operations with or without the co-administration of regular bupivacaine or other adjuncts when used with liposomal bupivacaine. The Subcostal TAPB demonstrates the possibility for prolonging analgesia using a single injection technique or continuous catheter operation.

This study goes with our study because subcostal TAPB provide appropriate analgesia for upper abdominal surgeries whether used with bupivacaine with or without adding adjuvant like ketamine.

Another study was done by Vrsajkov et al.<sup>9</sup> about using subcostal TAPB to improve analgesia after laparoscopic cholecystectomy. This study was done to investigate influence of subcostal TAPB on postoperative pain score and opioid consumption.

In this study 76 patients undergo laparoscopic cholecystectomy, split into 2 groups of 38 individual patients, first group got bilateral ultrasound guided subcostal TAPB presided over by Bupivacaine with 20 ml of 0.33 % prior to surgery and tramadol 1 mg IV for pain breakage, the second group received the normal hospital analgesic protocol tramadol 1 mg/kg/6h after surgery, both groups got acetaminophen 1 gram/8h and metamizole 2.5gram/12h.

This study showed that subcostal TAPB significantly reduces postoperative pain levels relative to standard analgesia at all times following surgery, although tramadol intake was significantly lower in subcostal TAPB than in standard analgesic groups. This study goes with our study about Subcostal TAPB which reduces postoperative pain score and decreases the consumption of opioids. In my opinion we have to double the dose in our study with bilateral ultrasound guided subcostal TAPB.

Another study was performed by Diab and Roshdy<sup>10</sup> to detect the effect of TAPB with ketamine for inguinal hernioplasty.

In this study 28 patients scheduled for elective unilateral inguinal hernioplasty under general anaesthesia were assigned at random to obtain ipsilateral TAPB to the side of surgery with either bupivacaine 0.5% or bupivacaine 0.5% with 0.5 mg/kg ketamine (n=14) for each. The postoperative 24h cumulative morphine consumption, first request for morphine, score of pain in rest, nausea and vomiting score and complications were recorded. This study showed that addition of ketamine 0.5mg/kg allows a lower concentration of levobupivacaine and improves the effectiveness of postoperative analgesia during caudal anaesthesia for lower abdominal surgeries and urological surgeries without loss of clinical effectiveness. In contrast with our study, this study states that ketamine with low dose in combination with bupivacaine can improve the effectiveness of postoperative analgesia.

Another study was performed by Baytaref al.<sup>11</sup> to compare the laparoscopic cholecystectomy between the ultrasound-guided subcostal transversus

abdominis plane block and the quadratus lumborum block.

Results of this research have shown that subcostal TAPB and quadratus lumborum blocks under general anaesthesia have decreased postoperative VAS score and tramadol intake to a similar level prior to surgical incision in laparoscopic cholecystectomies. Overhead abdominal surgery, like laparoscopic cholecystectomy, subcostal TAPB performed with US guidance may be regarded to get the benefits of simpler application compared with QL block and a short time.

This study is part of our study on the efficacy of subcostal TAPB in the reduction of postoperative VAS scores and opioid consumption.

### CONCLUSION

Adding of ketamine to bupivacaine in patients undergoing subcostal TAPB guided with ultrasound for laparoscopic cholecystectomy results in statistically insignificant in the following: longer period until first opioid requirement and prolonged block duration, less opioid requirement, early ambulation and the patient is being more satisfied.

### REFERENCES

1. Luo J, Min S. Postoperative pain management in the postanesthesia care unit: an update. *J Pain Res.*; 2017; 10:2687-98.
2. Şahin AS, Akay MK, Demiraran Y, et al. Analgesic effects of ultrasound-guided transverse abdominis plane block using different volumes and concentrations of local analgesics after laparoscopic cholecystectomy. *J Int Med Res.*, 2017;45(1):211-9.
3. Rafi AN. Abdominal field block: a new approach via the lumbar triangle. *Anaesthesia.*, 2001; 56:1024-6.
4. Hebbard P. Subcostal transversus abdominis plane block under ultrasound guidance. *AnesthAnalg.*, 2008;106:674-5.
5. Tolchard S, Davies R, Martindale S. Efficacy of the subcostal transversus abdominis plane block in laparoscopic cholecystectomy: Comparison with conventional port-site infiltration. *J Anaesthesiol ClinPharmacol.*, 2012;28(3):339-43.
6. Sin B; Ternas T, Motov SM, et al. The Use of Subdissociative-dose Ketamine for Acute Pain in the Emergency Department. *Academic Emergency Medicine*, 2015; 22(3): 251-7.
7. Niraj G, Kelkar A and Powell R. Ultrasound-guided Subcostal Transversus Abdominis Plane Block. *International Journal of Ultrasound and Applied Technologies in Perioperative Care*, 2010; 1(1):9-12.
8. Soliz JM, Lipski I, Hancher-Hodges S, et al. Subcostal Transverse Abdominis Plane Block

- for Acute Pain Management: A Review. *Anesth Pain Med.*, 2017; 7(5): 12923.
9. Vrsajkov V, Mančić N et.al. Subcostal transversus abdominis plane block can improve analgesia after laparoscopic cholecystectomy. *Rev Bras Anesthesiol.*, 2018;68(2):149-53.
  10. Diab DG, Roshdy H. Efficacy of transversus abdominis plane block with ketamine for inguinal hernioplasty: A controlled study. *Ain-Shams J Anaesthesiol.*, 2014;7:346-9.
  11. Baytar Ç, Yılmaz C, Karasu D , et.al . Comparison of Ultrasound-Guided Subcostal transversus abdominis Plane Block and Quadratus Lumborum Block in Laparoscopic Cholecystectomy: A Prospective, Randomized, Controlled Clinical Study. *Pain Res Manag.*, 2019;2019:2815301.