



6-1-2020

Endoscopic management of spontaneous intracerebral haemorrhage

Raed Elabd

Neurosurgery, Damanshour Medical National Institute, raed.elabd@gmail.com

Hamdy Behairy

neurosurgery, faculty of medicine, AL-Azhar university, Cairo, dr.hamdybehairy@hotmail.com

Sherif Ezzat

Neurosurgery Dept, Faculty of Medicine, AL Azhar University, Cairo, sherifezzat10@gmail.com

Follow this and additional works at: <https://aimj.researchcommons.org/journal>



Part of the [Medical Sciences Commons](#), [Obstetrics and Gynecology Commons](#), and the [Surgery Commons](#)

How to Cite This Article

Elabd, Raed; Behairy, Hamdy; and Ezzat, Sherif (2020) "Endoscopic management of spontaneous intracerebral haemorrhage," *Al-Azhar International Medical Journal*: Vol. 1: Iss. 6, Article 3.

DOI: <https://doi.org/10.21608/aimj.2020.25173.1163>

This Case Series is brought to you for free and open access by Al-Azhar International Medical Journal. It has been accepted for inclusion in Al-Azhar International Medical Journal by an authorized editor of Al-Azhar International Medical Journal. For more information, please contact dryasserhelmy@gmail.com.

Endoscopic Management of Spontaneous Intracerebral Haemorrhage

Raed El-Abd^{1,*} MB Bch, Hamdy M. Behairy² MD and Sherif A. Ezzat² MD

*Corresponding Author:

Raed El-Abd
raed.elabd@gmail.com

Received for publication March 4,

2020; Accepted May 15, 2020;

Published online July 15, 2020.

Copyright 2020 The Authors published by Al-Azhar University, Faculty of Medicine, Cairo, Egypt. All rights reserved. This an open-access article distributed under the legal terms, where it is permissible to download and share the work provided it is properly cited. The work cannot be changed in anyway or used commercially.

doi: 10.21608/aimj.2020.25173.1163

¹Damanhour Medical National Institute.

²Neurosurgery Department, Faculty of Medicine, Al-Azhar University, Cairo, Egypt.

ABSTRACT

Background:

Endoscopic evacuation of spontaneous intracerebral haemorrhage has gained accepted popularity in the last decades as a minimally invasive technique alternative to traditional craniotomy with increased range of surgical indications to include the ganglionic haematomas that were previously inaccessible.

Aim of work: To enlighten the endoscopic use for evacuation of intracerebral hemorrhage.

Patient and methods: This study describes a prospective study that was conducted in Al Azhar University hospitals and Damanhour medical national institute hospital from November 2017 to November 2019 to evaluate the use of surgical endoscope in evacuation of spontaneous intracerebral haemorrhage.

Results: the study included 28 patients, the intraoperative time was 75 ± 18.65 minutes, the evacuation rate was $90.98\% \pm 4.6\%$, and the post-operative Glasgow coma scale improved to a mean of 8.50 ± 3.46 .

Conclusion: The endoscopic evacuation of spontaneous intracerebral hemorrhage is less invasive, less destructive, less time consuming and provides better visualization to the cavity of the hematoma and higher evacuation ratios.

Keywords: Endoscopic, spontaneous, intracerebral haemorrhage.

Disclosure: The authors have no financial interest to declare in relation to the content of this article. The Article Processing Charge was paid for by the authors.

Authorship: All authors have a substantial contribution to the article.

INTRODUCTION

Intracerebral haemorrhage is the second most common form of stroke, accounting for 13–20% of first-time strokes.¹ Chronic damage of the cerebral vasculature due to long-standing arterial hypertension is the most important underlying pathophysiological mechanism leading to ICH.² Surgical management of ICH is still a matter of controversy with regard to indications, timing, and method.³ Endoscopic evacuation of intracerebral hemorrhage was first reported by Auer in 1985.⁴

PATIENT AND METHODS

This study was conducted in The Department of Neurosurgery at Al-Azhar University Hospitals and Damanhour medical national institute hospitals, from November 2017 to November 2019. This study included patients who underwent endoscopic evacuation of Spontaneous Supratentorial Intracerebral Hematoma.

Inclusion criteria: Spontaneous supratentorial ICH ≥ 30 ml with GCS 6:12 within 72 hours from the ictus and any age are included.

Exclusion criteria: ICH due to trauma, tumour, vascular anomalies, vasculopathy and haemorrhagic transformation of ischemic stroke, Patients on antiplatelet or anticoagulant therapy, Posterior fossa hematoma, and Patients with end-stage renal or liver disease.

Preoperative protocol:

CT brain is the mainstay of the radiological examination with 3D reconstruction if needed.

The site of hematoma will be classified according to site (right and left) and volume. The volume will be measured according to a bedside method of measuring CT ICH volume. The Broderick's formula $(ABC)/2$ will be used, where A is the greatest hemorrhage diameter by CT, B is the diameter 90 degrees to A and C is the approximate number of 10 mm CT slices with hematoma.

Labs: CBC, Coagulation profile, sGPT, sGOT, Urea, Creatinine, RBS.

Surgical technique: Procedure is performed in an operating room equipped with neuroendoscope, Patient is in supine position, General anaesthesia, Sterilization, Identification of the entry point according to: 1- safe entry point like Kocher's point: 3 cm from the midline to the site of the hematoma and 1 cm in front the coronal suture, 2- shortest entry

point: from the cortex to the hematoma or 3- at longitudinal axis of hematoma: more common through frontal keyhole, the hematoma is decompressed internally by suction with rotational spiral movement, the sheath should reach half of hematoma length at least, the ICP then pushes the sides of the hematoma towards the visual field of the endoscope with little gentle manipulation of the sheath might be needed, Linear scalp incision ~ 6cm is made, 3-4 cm diameter burrhole was created, Cauterization of the dura then cruciate dural incision is made, Tenting dura with 4/0 silk, Identifying the site of the hematoma and creation of a path using brain canula, Cortical incision with bipolar cauterization is made, Balloon dissection by a Foley catheter size 10 with a stylet through gentle inflation and deflation many times by saline. Transparent plastic sheath made from syringes with caliber of 1.5cm is then inserted on the top of inflated Foley then deflation occurs, After establishing the sheath, 0° or 30° endoscope is introduced by free hand with angled suction through the sheath, Evacuation of the hematoma by suction, Dealing with the bleeder if found by bipolar electrocautry, Hemostasis using fibrillar or Gelfoam®, Gradual removal of the transparent sheath and dealing with any hematoma residual or bleedings, Closing of the skin incision in two layers. (Figures1,2)

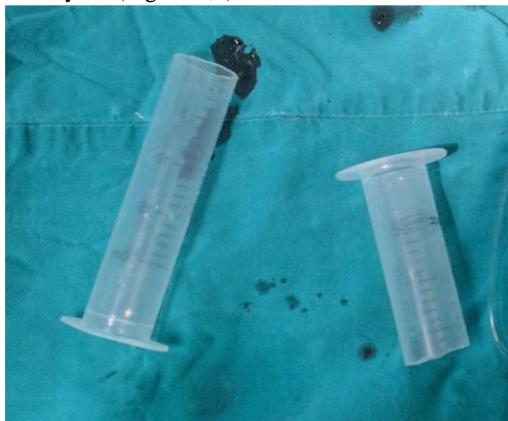

Fig. 1: Transparent sheath.

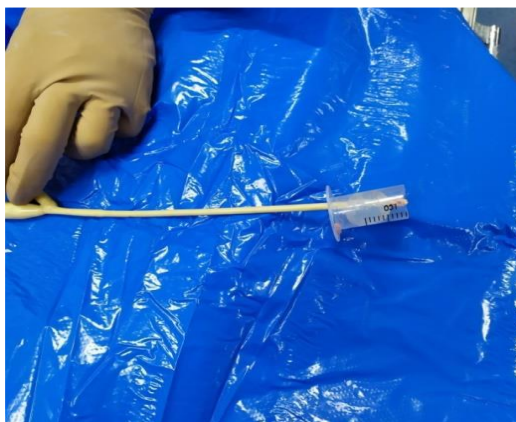

Fig. 2: Foley catheter used as balloon dissector.

Post-operative: Patient is transported to the ICU department, sedated and ventilated for 48 hours then extubated according to his clinical vitals. In the ICU,

Postoperative systolic blood pressure must be strictly controlled at <160 mmHg with MAP ~ 120 mmHg, and the presence of excessive fluids not allowed; blood glucose levels, PH, should be strictly controlled. After stabilizing the patient brain CT scan was arranged for all patients undergoing hematoma evacuation. Post-operative hematoma volumes were calculated presented by percentage as: (preoperative volume – postoperative volume) / preoperative volume.

Follow up: Patients were followed up clinically and radiologically for 1 and 3 months by GCS, GOS and serial CT brain. (Figures 3-5)

Statistical analysis: All statistical analysis performed using SPSS version 20.

RESULTS

This study included 28 patients, 20 (71.4%) were males and 8 (28.6%) were females. The age of patients in this study ranged from 36 to 73 years, with a mean age of 60.43 years and a median 61.50 years. Out of 28 patients constituting this study, 9 (32.14%) were <60 years and 19 (67.86%) were ≥60 years. 20 patients (71.4%) were hypertensive while 8 patients (28.57%) were normotensive. Nine patients (32.1%) were diabetic.

The time between ictus (1st CT brain) & surgery of patients in this study ranged from 6 to 24 hours with a mean time 10.79 hours and a median time 8 hours. The preoperative hematoma volume of patients in this study ranged from 30 to 80 ml with a mean volume 46.96ml and a median volume 45 ml while the postoperative hematoma volume of patients in this study ranged from 1 to 10 ml with a mean volume 4.32ml and a median volume 5 ml.

The evacuation rate of ICH in this study ranged from 78% to 98 % with a mean 90.98 % and a median 91.55%. The operative time in this study ranged from 50 to 120 minutes with a mean time 75 minutes and a median time 75 minutes.

The preoperative GCS of patients in this study ranged from 6 to 11 with a mean 7.25 and a median 6 while the postoperative (7th day) GCS of patients in this study ranged from 3 to 15 with a mean 8.50 and a median 8. The GOS of patients in this study ranged from 1 to 5 with a mean 2.82 and a median 3. In this study, 4 patients (14.29%) had a ventricular drain, 7 patients (25%) died from uncontrolled blood pressure, severe pneumonia, cardiac failure, septicemia and other causes in ICU.

Three patients (10.7%) had infection postoperatively in the ICU. 10 patients (35.71%) had favorable outcome according to GOS and 18 patients (64.29%) had unfavorable outcome.

We found that the 7th postoperative day GCS is strongly and only correlated to the preoperative GCS where the other factors have no correlation with postoperative GCS. On the other hand, the Glasgow Outcome Scale is correlated with preoperative GCS, size of hematoma and presence of diabetes.

Cases presentation:

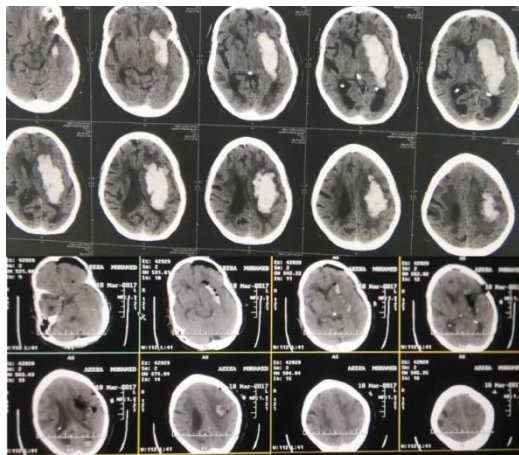


Fig. 3: Radiological findings in Case 1

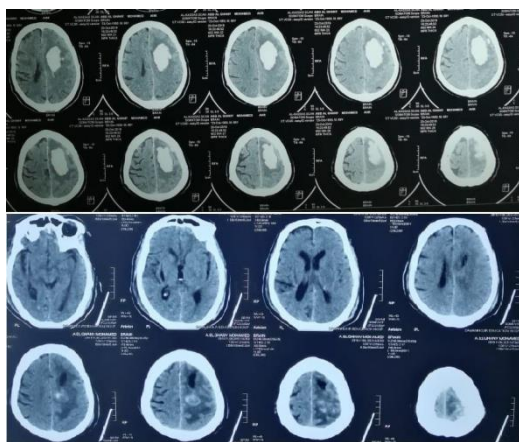


Fig. 4: Radiological findings in Case 2

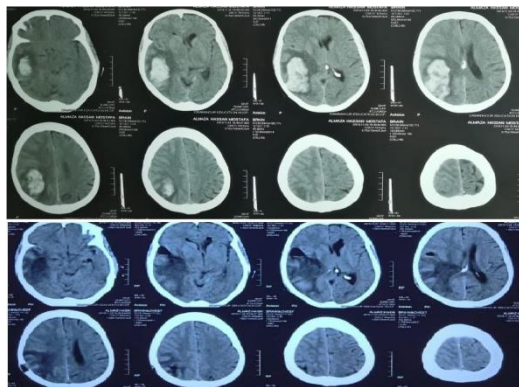


Fig. 3: Radiological findings in Case 3

DISCUSSION

The main aim of surgical interventions is to reduce hematoma volume, prevent further hemorrhage, relieve mass effect, and reduce intracranial pressure rapidly, thereby preventing secondary neurologic deterioration by relieving local ischemia or removal of noxious chemicals.⁵

Evacuation of supratentorial ICH by standard craniotomy might be considered for patients who have lobar ICH >30 mL and within 1 cm of the surface.⁶ Craniotomy has been speculated as an appropriate treatment for ICH evacuation.⁷ A number

of surgical trials have confirmed that craniotomy tends to be more harmful than beneficial and without improved clinical outcomes.⁸ Therefore, a minimally invasive surgery treatment related to clot evacuation has been under focus in treating ICH over craniotomy.⁹

The Surgical Trial in Intracerebral Hemorrhage (STICH) was the largest prospective, randomized study to date to compare early surgery, within 24 hours of randomization (n = 503), to conservative management (n = 530), for the treatment of supratentorial ICH. This trial showed no overall difference in the rates of favorable outcomes between the two groups (26% surgical group versus 24% medical group; p = 0.414).⁶

Male constituted 71.4% of the patients of this study while females constituted 28.6% of them. This higher male incidence correlated with the findings of Lichao Ma et al, 2017 where males represented 71% of the patients of the study; also it is correlated with the findings of Weijun Wang et al, 2017 where males constituted 74.28% of the study patients. This is also correlated with the findings of NitinGoyal et al, 2019 where males constituted 73.70% of the patients in the study.^{10, 11, 18}

The mean age of the patients of our study was 60.43±8.95 years. This corresponded to Weijun Wang et al, 2017 who reported a mean age of 61.1±12.1 years; also it corresponded to QiangCai et al, 2019 where the mean age of the patients was 59.7 years.^{11, 12}

Guoqing Sun et al, 2019 reported a higher mean age of patients which was 66.6 ± 11.5 years and C.J. Przybylowski et al, 2015 also reported a higher mean age of patients which was 65 years.^{13, 14}

The sex and age data correlated with the literature's incidence of ICH in which the risk increases significantly after age 55 years and doubles with each decade of age and more common in men.¹⁵

In our study, 20 patients (71.4%) were hypertensive and 8 patients (28.6%) were not. These data were compatible with data reported by Eroglu U et al, 2018 where 12 patients (70.6%) were hypertensive, Lichao Ma et al, 2017 that reported 18 patients (75%) were hypertensive and Zhu H. et al, 2012 where 21 patients (75%) had history of hypertension. NitinGoyal et al, 2019 reported a little bit increase in the percentage of hypertensive patients 83.3%.^{10, 16, 17, 18}

Hypertension is the single greatest modifiable risk factor and the most significant cause for SICH. The relative risk for SICH in hypertensive individuals remains 3.9 to 13.3 times that for normotensive individuals.¹⁹

In our study there was no correlation neither between hypertension and 7th day postoperative GCS nor GOS; where the P-value was not significant. We believe that although the hypertension is the main risk factor for SICH, it is also can be controlled in the perioperative period in a manner not to affect the

postoperative GCS or the GOS unless the patient is under strict medical care.

We found that no correlation between the presence of diabetes and the 7th day postoperative GCS where the P-value was (0.274), but there was a correlation between the presence of diabetes and GOS where the P-value was (0.049). Braun K.F et al, 2012 confirmed that despite multiple comorbidities and risk factors no significant difference in hospital mortality was seen in diabetic patients as compared to non-diabetic patients as improved treatment strategies and early intervention may compensate for their poorer prognosis.²⁰

Regarding the mean preoperative hematoma volume, our results was 46.96 ± 11.494 ml and mean evacuation rate $90.98\% \pm 4.6\%$ which is consistent with other studies as shown in table 1.

	Xinghua Xu et al, 2018	Martin Rutkowski et al, 2019	Qiang Cai et al, 2019	Umit Eroglu et al, 2018
Preoperative Volume ml	55.2 ± 28.4	46	49.5	53.07±4.64
Evacuation Rate %	90.5 ± 6.5%	92%	90.1%	93.70±2.31%

Table 1: Comparison between mean preoperative volume and evacuation rate.^{12, 16, 21, 22}

There was no correlation between preoperative hematoma volume and 7th day postoperative GCS (p-value = 0.105) but there was a significant correlation between preoperative hematoma volume and GOS (p-value = 0.047). This might be due to that larger hematomas could cause more injurious effects on the neural cells causing more disabilities and morbidities on the long term.

The mean operative time in our study was 75 ± 18.65 minutes which is compatible with UmitEroglu et al, 2018 who reported a mean operative time 73.47 ± 5.75 ; higher than the study of QiangCai et al, 2019 who reported a mean operative time 63.1 minute; and lower than the study of Guoqing Sun et al, 2019 and XinghuaXu et al, 2018 who reported a mean operative time about 113 ± 14.3 min and 96 ± 42 min respectively.^{12, 13, 16, 22}

The mean operative time of endoscopic evacuation, in general, runs in the same track for most studies using the same method and this mean time is much lower than of the traditional craniotomy. For example, Yuqian Li et al, 2017 reported that patients in the craniotomy group experienced the longest operation time where the mean operative time was 234 minute. Another example shown by Wang et al, 2015 where the median operation time was 230 minutes ranging from 120 to 460 minutes using craniotomy approach.^{9, 11}

The mean preoperative GCS of patients in our study was 7.25, ranged from 6 to 11 while the mean

postoperative (7th day) GCS was 8.50 ranged from 3 to 15. There was statistically significant improvement in GCS at 7th day postoperative when compared to preoperative GCS (P-value < 0.001).

In our study, the median GOS was 3 ranging from 1 to 5 with 10 patients (35.71%) had a favourable outcome and 18 patients (64.29%) had unfavourable outcome. Our study is compatible with Wang et al, 2015 who reported the median GOS evaluated 6 months and 1 year postoperatively was 3, but when comparing with results in craniotomy group, good short-term surgical outcome for endoscopic surgery, but no benefit for long-term functional recovery.

The overall mortality rate in our study was 25% where the perioperative mortality was 0%. This data is compatible with Martin Rutkowski et al, 2019 who reported overall mortality rate 28% and with Weijun Wang et al, 2017 who reported overall mortality rate 20%. Our overall mortality rate was much lower than NitinGoyal et al, 2019 who reported a mortality rate 38%. But these results were higher than XinghuaXu et al, 2018, Guoqing Sun et al, 2019, Koichi Miki et al, 2018 and QiangCai et al, 2019 who reported a mortality rate 7.30%, 4.30%, 7.1% and 7.1% respectively.^{11, 21, 18, 22, 13, 23, 12}

The overall mortality rate is a multifactorial process where the postoperative ICU has the upper hand of it. For example, in our study 7 patients died from uncontrolled blood pressure, cardiac complications, severe pneumonia and septicemia although they showed initial improvement of GCS in the postoperative 3rd day than preoperative GCS.

In our study, a bleeder causing the ICH was identified in 4 cases (14.28%) where the other cases there was no bleeder identified; the bleeding source in those latter cases was just oozing from surrounding tissues stopped by simple hemostatic measures like Gelfoam and Surgical with irrigation and compression. This might be due to amyloid angiopathy which is a common cause of SICH.

CONCLUSION

The endoscopic evacuation of spontaneous intracerebral hemorrhage is better than traditional craniotomy. Although the two ways have the same outcome on the long term, endoscopic evacuation is less invasive, less destructive, less time consuming and provides better visualization to the cavity of the hematoma so better dealing with bleeding sources and higher evacuation ratios.

REFERENCES

1. M. A. Kirkman and W. Mahattanakul, B. A. Gregson, and A. D. Mendelow. The effect of the results of the STICH trial on the management of spontaneous supratentorial intracerebral haemorrhage in Newcastle. *British Journal of Neurosurgery*. 2008; vol. 22, (6): 739–46.
2. Christopher Beynon, Patrick Schiebel, Julian Bösel, et al. Unterberg and BerkOrakcioglu.

- Minimally invasive endoscopic surgery for treatment of spontaneous intracerebralhaematomas. *Neurosurg Rev.* 2015; 38:421–8.
3. Lu-Ting Kuo, Chien-Min Chen, Chien-Hsun Li, et al. Early endoscope-assisted hematoma evacuation in patients with supratentorial intracerebralhaemorrhage: case selection, surgical technique, and long-term results. *Neurosurg Focus.* 2011; 30 (4):E9.
 4. Auer LM and Ritschl E. Endoscopic evacuation of an intracerebral and intraventricularhaemorrhage. *Archives of Disease in Childhood.* 1987; 62(11):1163-5.
 5. Xi G, Keep RF and Hoff JT. Mechanisms of brain injury after intracerebralhaemorrhage. *The Lancet Neurology.* 2006; 5(1):53-63.
 6. Mendelow AD, Gregson BA, Rowan EN, et al. STICH II Investigators. Early surgery versus initial conservative treatment in patients with spontaneous supratentorial lobar intracerebralhaematomas (STICH II): A randomised trial. *Lancet.* 2013; 382:397-408.
 7. Bosel J, Zweckberger K and Hacke W. Haemorrhage and hemicraniectomy: refining surgery for stroke. *Current opinion in neurology.* 2015; 28(1):16-22.
 8. Li Q, Yang CH, Xu JG, et al. Surgical treatment for large spontaneous basal ganglia hemorrhage: retrospective analysis of 253 cases. *British Journal of Neurosurgery.* 2013; 27(5):617-21.
 9. Li Y, Yang R, Li Z, et al. Surgical Evacuation of Spontaneous Supratentorial Lobar Intracerebral Hemorrhage: Comparison of Safety and Efficacy of Stereotactic Aspiration, Endoscopic Surgery, and Craniotomy. *World Neurosurgery.* 2017; 105:332-40.
 10. Lichao ma, Hou Y, Zhu R, et al. Endoscopic Evacuation of Basal Ganglia Hematoma: Surgical Technique, Outcome, and Learning Curve. *World Neurosurgery.* 2017; 101:57-68.
 11. Wang W, Zhou N and Wang C. Minimally Invasive Surgery for Patients with Hypertensive Intracerebral Hemorrhage with Large Hematoma Volume: A Retrospective Study. *World Neurosurgery.* 2017;105:348-58.
 12. Cai Q, Guo Q, Li Z, Wang W, et al. Minimally invasive evacuation of spontaneous supratentorial intracerebral hemorrhage by transcranial neuroendoscopic approach. *Neuropsychiatr Dis Treat.* 2019;15:919–925.
 13. Guoqing Sun, Xiaolong Li, Xiangtao Chen, et al. Comparison of keyhole endoscopy and craniotomy for the treatment of patients with hypertensive cerebral hemorrhage. *Medicine.* 2019; 98:2.
 14. Colin J. Przybylowski, Dale Ding, Robert M. Starke, R. Webster Crowley, Kenneth C. Liu. Endoport-assisted surgery for the management of spontaneous intracerebral hemorrhage. *Journal of Clinical Neuroscience.* 2015: 1727-32.
 15. Howard G, Cushman M, Howard VJ, et al. Risk factors for intracerebral hemorrhage: the Reasons for geographic and racial differences in stroke (REGARDS) study. *Stroke.* 2013; 44(5):1282-7.
 16. Umit Eroglu, Gokmen Kahilogullari, Ihsan Dogan, et al. Surgical Management of Supratentorial Intracerebral Hemorrhages: Endoscopic Versus Open Surgery. *World Neurosurgery.* 2018; 114: Pages e60-5.
 17. Zhu H, Wang Z and Shi W. Keyhole endoscopic hematoma evacuation in patients. *Turkish neurosurgery.* 2012; 22(3):294-9.
 18. Goyal N, Tsivgoulis G, Malhotra K, et al. Minimally invasive endoscopic hematoma evacuation vs best medical management for spontaneous basal-ganglia intracerebral hemorrhage. *Journal of NeuroInterventional Surgery.* 2019;11:579-83.
 19. Woo D, Sauerbeck LR, Kissela BM, et al. Genetic and environmental risk factors for intracerebral hemorrhage: Preliminary results of a population-based study. *Stroke.* 2002; 33:1190-5.
 20. Braun KF, Otter W, Sandor SM, et al. All-cause in-hospital mortality and comorbidity in diabetic and non-diabetic patients with stroke. *Diabetes Research and Clinical Practice.* 2012; 98(1):164-8.
 21. Martin Rutkowski, Ivy Song, William Mack, et al. Outcomes after Minimally Invasive Parafascicular Surgery for Intracerebral Hemorrhage: A Single-Center Experience. *World Neurosurgery.* 2019; E1-9.
 22. Xinghua Xu, Xiaolei Chen, Fangye Li, et al. Effectiveness of endoscopic surgery for supratentorial hypertensive intracerebral hemorrhage: a comparison with craniotomy. *J Neurosurg.* 2018; 128: 553–9.
 23. Koichi Miki, Kenji Yagi, Masani Nonaka, et al. Spot sign as a predictor of rebleeding after endoscopic surgery for intracerebral hemorrhage. *J Neurosurg.* 2019; 130:1485–1490.