



4-1-2020

Uses of Laser Therapy in Management of Pilonidal Sinus

Haroon Allam

General surgery Department Al-Azhar Faculty of Medicine Cairo, harounallam@hotmail.com

Hisham Anwar

General Surgery department, Al-Azhar Faculty of Medicine in Cairo, Cairo, hisham.wefky@yahoo.com

Khaled Essa

General Surgery, Al-azhar Faculty of medicine in cairo, surgeonkhaledessa@gmail.com

Follow this and additional works at: <https://aimj.researchcommons.org/journal>



Part of the [Medical Sciences Commons](#), [Obstetrics and Gynecology Commons](#), and the [Surgery Commons](#)

How to Cite This Article

Allam, Haroon; Anwar, Hisham; and Essa, Khaled (2020) "Uses of Laser Therapy in Management of Pilonidal Sinus," *Al-Azhar International Medical Journal*: Vol. 1: Iss. 4, Article 4.

DOI: <https://doi.org/10.21608/aimj.2020.27137.1189>

This Case Series is brought to you for free and open access by Al-Azhar International Medical Journal. It has been accepted for inclusion in Al-Azhar International Medical Journal by an authorized editor of Al-Azhar International Medical Journal. For more information, please contact dryasserhelmy@gmail.com.

Uses of Laser Therapy in Management of Pilonidal Sinus

Allam Haroon Abd-Elkareem, Anwar Hisham Wefky & Essa Khaled Zaki

***Corresponding Author:**

Essa Khaled Zaki

Surgeonkhaledezza@gmail.com

Received for publication, April 2, 2020; Accepted, May 8, 2020; published online, May 9, 2020.

Copyright 2020 The Authors published by Al-Azhar University, Faculty of Medicine, Cairo, Egypt. All rights reserved. This an open-access article distributed under the legal terms, where it is permissible to download and share the work provided it is properly cited. The work cannot be changed in anyway or used commercially.

General Surgery Department, Faculty of Medicine, Al-Azhar University

DOI: [10.21608/aimj.2020.27137.1189](https://doi.org/10.21608/aimj.2020.27137.1189)

Abstract

Background: Background: Published results have shown that Laser pilonidoplasty may be effective in management of pilonidal sinus (PNS). We report the final results of a case series study evaluating the safety and efficacy Diode Laser 980 nm in management of PNS.

Material And Methods: this small case series study including twenty patient suffering from chronic primary PNS (single or branched) between 18 and 36 years old, we carried out laser pilonidoplasty usind diode laser 980nm on continuous mode (power of 5 watt with power density 994 W/cm²) with aradial fiber that emits heat energy in 3600 direction leading to photocoagulation of sinus tract by vaporization of water content of blood and tissues at rate 1.5 cm / min., the mean operative time was (27.2±4.18)minute., at Sayed Galal Hospital and Tanta Insurance Hospital Egypt between January 2019 and December 2019 with follow up for ten months. The outcome was evaluated by recurrence or not.

Results: All twenty patients were treated using diode laser 980nm, The mean time for complete healing was (28.5±3.87) day. after ten months follow up ; recurrence occurs in one case (5%)

Conclusion: Laser Pilonidoplasty is a simple, reasonable, feasible, minimal invasive, reproducible technique and competitive alternative to other surgical intervention. It is accompanied by a reduction in pain, early resuming work with decreased rate of recurrence. In spite of surgical approach is still the standard modality for PNS treatment.

Keywords: PNS; Diode laser 980nm; Laser pilonidoplasty.

Disclosure: The authors have no financial interest to declare in relation to the content of this article. The Article Processing Charge was paid for by the authors.

INTRODUCTION

Apilonidal sinus (PNS) is a small cyst or abscess that occurs in the the top on the natal cleft. PNS usually contains hair, dirt, debris and unhealthy granulation tissue. It causes severe pain and always become infected, leads to pus oozing and have a foul odour.¹

The exact cause of PNS is unobvious. It is thought that it caused by mal- direction of growing hair. Leading to a hair follicle rupture.²

Due to increased number of patients suffering from complications of PNS surgery, we will use diode laser 980 nm in this study as an alternative of surgery of PNS, for achieving many benefits from laser therapy in management of PNS as easily applied, minimal-invasive technique low recurrence

rate, non-toxic, painless, highly effective for many conditions, patient satisfaction is high, reduce the needs of pharmaceuticals, no drug interactions, quick return to work and daily activity and no known adverse effects.³

In 2011, Wilhelm was the first one to describe a new technique in management of peri-anal fistula as areplacement for traditional surgery and to preserve anal sphincters using a radial laser probe (fistula-tract laser closure, biolitec company, Germany). The probe destroys the epithelium lining the fistula and simultaneously obliterates the tract by vaporization and photocoagulation effect.⁴

LASER is a light amplification by stimulated emission of radiation. Laser is an easy, simple, effective and harmless clinical procedure used for treatment of chronic PNS, as an alternative to surgery.⁵

Laser types and components are ; chemical laser, dye laser , solid-state laser, gas laser, semiconductor laser, metal-vapor laser and medical laser .Medical lasers are of two types : Non- contact and Contact; the last work by sending laser light through a fiberoptic probe with crystal tip. The tip absorbs the radiant energy and becomes hot. contact among tissues and the heated tip leads to conduction of heat energy through the Fiberoptic probe till its tip and then to surrounding nearby tissues lead to vaporization of water content of blood and target cells Diode optical device is the direct type of contact lasers. Diode 30 Watt laser with 980 nm wave length was used for this procedure .⁶

A process and device for selective photothermolysis of a surgical target and neighbouring tissue. The target and the neighbouring tissue are heated to about 60° C may reach about 70° C. Then the target is heated to reach the destination point of photo-coagulation, preferably by monochromatic light. The heat difference between the coagulating target and the neighbouring tissue is sufficiently mild that heat diffusing out of the target does not hurt the neighbouring tissue, even in the case of a relatively large target such as varicose veins.⁷

Diode laser device offer nice advantages over several different lasers as a result of its little size ,diode laser additionally provides a large variety of spectrum of beam wavelength that will be employed in multiple medical fields . another privilege of diode laser device ; the fiber-optic probe that transmits heat energy in 3600 direction homogeneously, so it can be used in different locations with good results.⁸

Material And Methods

Twenty patients (12 male , 8 female) , age (18 : 36 years old) suffering from chronic primary PNS were treated by diode laser 980 nm (laser pilonidoplasty) ; we carried out this study at Al-Azhar University hospital (Sayed Galal Hospital) and Tanta Insurance Hospital over period from January 2019 to December 2019.

Preparation and Technique:

Methods of diagnosis:

Sinogram and MRI to detect if it is single tract or branching,

Inclusion criteria:

Chronic, primary sacrococcygeal PNS (single or branched),.

Exclusion criteria:

- Acute Abscess,
- Recurrent and umbilical or other site of PNS.

Points of outcome assessment of technique:

Safety and efficacy of laser pilonidoplasty.,

Period of study:

Eleven months, Length of follow up: Ten Months, Written informed consent : An approval of the study was obtained from Al- Azhar University academic and ethical committee. Every patient signed an informed written consent for acceptance of the technique., Diode laser 980 nm device (Biolitec Biomedical Technology, Jena, Germany ;2011) :

semiconductor device that emits Laser light as electric current (electromagnetic radiation) through process of amplification , these radiation are of continuous type ,

Mechanism of action:

The heat energy delivered from diode laser through fiberoptic probe acts on vaporization of water content of blood (resulting from curettage of the sinus tract after cleaning) leads to photocoagulation and ablation of sinus tract leads to steaky sensation during exit of the probe from the tract with the obliteration of sinus tract is palpated. ,Fiberoptic probe :Flexible, radially emitting laser fiber that emits laser beams in 360o as in fig. 1 .



Fig.1 : Fiberoptic probe

Laser Pilonidoplasty :

The procedure was performed under local or general anesthesia with the patient lying prone,

Antibiotic prophylaxis was given before the procedure, Iodine antiseptic solution was applied on the shaved skin of the buttocks and sterile drapes were used to expose the whole natal cleft,

The whole sinus tract, pockets and side branches if present were curetted through the midline pits and lateral pits if present by a small Volkmann's spoon to remove hair, debris and unhealthy granulation tissue. Cleaning of sinus tract from hair debris necrotic tissues as in fig.2,

Care was taken to extract all debris from the sinus to avoid remaining hair and unhealthy granulation tissue after laser pilonidoplasty, which could potentially lead to further acute infection., this is done by curettage of tract and side branches if present and washing the sinus more than one time by saline 0.9% and Iodine 10% with curettage also more than one time and cleaning by washing several times to get rid of hair, debris necrotic tissue and unhealthy granulation tissue as in fig. 3,

The 220 um fiberoptic probe introduced through the tract till reach the tip of tract then retrogradely force in a very rate of 1.5 cm/min applying continuous power of (5 W) , power density (994 W/cm²), The procedure continuing at this rate till the total fiber out of the sinus apart from the Orb tip that was left for additional ten seconds at the external Pits before actuation it out terminating the procedure as in fig. 4a,b,c.,

We did laser pilonidoplasty using diode laser 980 nm (Biolitec Biomedical Technology, Jena, Germany ;2011) with fiberoptic probe and the optical output is 15 or 30 watt at the distal end of the optical fiber (7.5 watt with a 220 micrometer fiber) and radially emitting laser fiber that emits laser energy in a 360 degree that ensures homogenous photothermal destruction of the tract. , Finally, cold fomentation and dressing. ,

Time of operative technique: ranged from 20 to 30 minutes with mean of 25.2 ± 5.1 minutes.

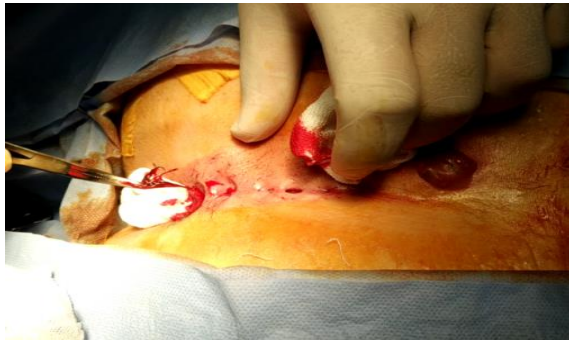


Fig. 2: cleaning of sinus tract from hair, debris and necrotic tissues.

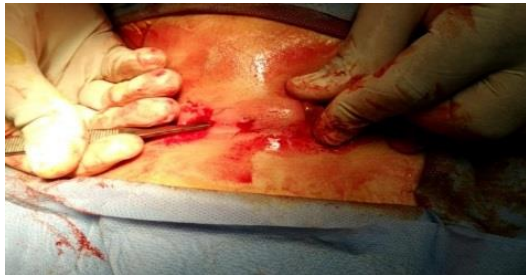

Fig. 3: curettage of sinus tract to remove unhealthy granulation tissues.

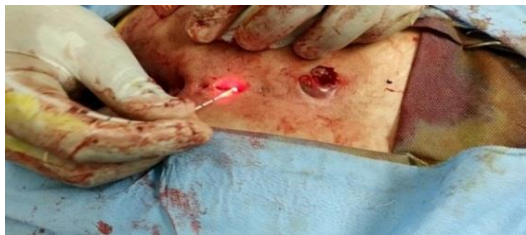

Fig.4 a: Laser Pilonidoplasty(destruction of sinus opening)

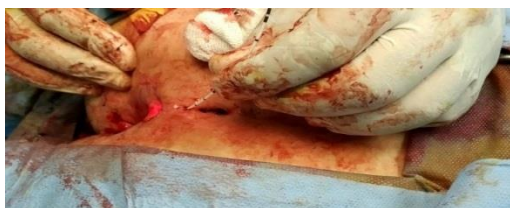

Fig. 4b: Laser pilonidoplasty (destruction of sinus wall) .

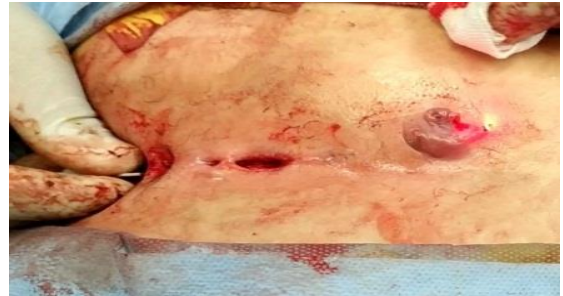

Fig 4 c: Laser pilonidoplasty (destruction of sinus tract).

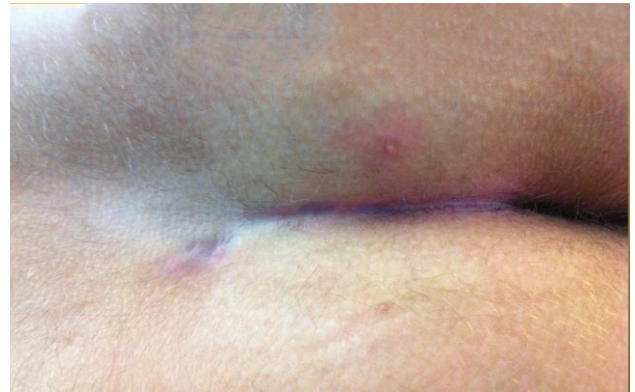

Fig.5: Three months Post operative Pilonidoplasty.

Statistical methods

Data management and statistical analysis were done using SPSS. Numerical data were summarized as means and standard deviations or medians and ranges. Categorical informations was summarized as numbers and percentages.

Results

Twenty patients have been done laser pilonidoplasty with diode laser980 nm in our study and the collected results were statistically analyzed taking the following in consideration:

Age: ranged between 18 to 36 years with mean of (28.5 ± 5.98) , Sex: include 12 males (60%) and 8 females (40%),

In comparison between age and sex; we found that there was no significant difference in our results.

Post-operative complications: include infection (3 cases), seroma (1 case), ischemia and necrosis (1 case), Time of return to normal activity: ranged from 7 to 13 days with mean of 10.6 ± 2.26 days,

Time of complete healing: ranged from 22 to 34 days with mean of 28.5 ± 3.87 days., Follow up 3month: recurrence occurred in 1 case (5%), infections occurred in 3 cases (15%) and 16 cases (80%) were normal.,

Follow up 3 months, 6 months and 10 months: recurrence occurred in 1 case (5%), 19 cases (95%) were normal., Post-operative recurrence: recurrence rate was 5% (1 case only).

Complications	No.	%
None	15	75.0%
Infection	3	15.0%
Seroma	1	5.0%
Ischemia and necrosis	1	5.0%
Total	20	100.0%

Table (1): showing postoperative complications

Follow up		No.	%
After 3 months	Normal	16	80.0%
	Recurrence	1	5.0%
	Infection	3	15.0%
After 6 months	Normal	19	95.0%
	Recurrence	1	5.0%
After 10 months	Normal	19	95.0%
	Recurrence	1	5.0%

Table (2): showing follow up 3 month, 6 months and 10 months.

Discussion

Pilonidal sinus is a process of chronic inflammation that most typically arises in the follicles of hair at the natal cleft. Age distribution of a peak incidence between 16 and 26 years, PNS is rare after 40 years.⁹

Management begin from depilation of hair meticulously and native hygiene for actually symptomless to aggressive surgery just in chronic cases. The best medical care ought to be directed to treat the underlying aetiological issue and would be a quick cure that allowed patients to come back quickly to the daily activity, with least morbidity and an occasional risk of complications¹⁰. Sadly, surgery is associate degree invasive methodology with a high recurrence rate.¹¹

Recurrence rate with surgical procedures have according to be between one and thirty five percent.¹²

The sinus ablative technique by diode laser optical device and laser catheter fiber optic probe (Biolitic Biomedical Technology, Jena, Germany) aims to destroy solely the Pockets and also the unhealthy granulation tissues.in addition to optical device thereby inflicting borderline invasion to the encircling healthy tissues. In our study we have been used diode optical device 980 nm in treatment of PNS, Diode optical device 980 nm that possesses a deeper power of penetration concerning about one and half millimeter.¹³

Application of diode optical device 980 nm in 8w power in defocused continuous mode can rise temperature of affected tissues higher than fifty degree and a fewer than one hundred degree, this temperature can cause macromolecules denaturation.¹⁴

The sign of macromolecule denaturation is that the blanching of the treated tissues. Denaturation of macromolecule at the affected space suggest that destruction of the pathologic epithelial tissues with its surface substance. Additionally, all the immunologic response elements gift within the vary of diode laser optical device 980nm management, as cytotoxic proteins, antigen antibodies and subepithelial lymphocytes. Square measure all denaturated because of its deeper penetration.¹⁵

In our study the age ranged between 18 to 36 years with the mean age was 28.5 ± 5.98 years which is slightly different to results reported by Dessily et al.¹⁶ where the mean age was 24.5 ± 7.2 , Georgiou¹⁷ where the mean age was 19.5 ± 3.8 years, Pappas et al.¹⁸ where the median age was 24 years.

In our study, the results regarding to gender type 12 male (60%) and 8 female (40%) slightly similar to those reported by Dessily et al.¹⁶ who used 72 Male (72%) & 28 Female (28%), Georgiou¹⁷ used 40 male (83%) and 8 female (17%), Pappas et al.¹⁸ used 183 male (77.2 %) and 54 female (22.8%).

In our study, regarding to the Clinical presentations all cases are primary pilonidal sinus similar to the study done by Dessily et al.¹⁶ but different to studies done by Georgiou¹⁷ and Pappas et al.¹⁸ as these studied done on primary and recurrent pilonidal sinus.

In our study, regarding to time of operative technique, it ranged from 20 : 30 minutes with mean of 25.2 ± 5.1 minutes which is longer than results reported by Dessily et al.¹⁶, operative time was about 9 minutes, but is the same as to the study reported by Pappas et al.¹⁸, operative time also ranged from 20 : 30 minutes, while it is shorter than results reported by Georgiou¹⁷ which was about 40 minutes.

In our study the post-operative complications included infection in 3 cases (15%), seroma in 1 case (5%) and ischemia and necrosis in 1 case (5%) which are all eventually healed using oral antibiotics and cleaning in complicated cases while recurrence occurred in 1 case (5%) and there for healing rate is 95% strongly similar to results reported by Dessily et al.¹⁶ which is 94% and Georgiou¹⁷ which is 92%, but is slightly different from results reported by Pappas et al.¹⁸ which is 90.3%.

In our study, time required for complete healing ranged from 22 : 34 days with mean of 28.5 ± 3.87 days that is slightly different from the mean time reported by Dessily et al.¹⁶ which is 19.5 ± 14.4 days, while average time reported by Georgiou¹⁷ is about 35 days, but is strongly different from results reported by Pappas et al.¹⁸ that ranged from 45 : 65 days with average time about 60 day., but time needed to return to normal activity is about 7 : 10 days in all studies.

The diode optical device 980nm has most the benefits of alternative lasers (the simply transferring of the beam by fiber-optic probe, the movability of the device and easy of its use) while not the disadvantages just like the device price. Once we study the surgical technique;incision and lay open technique was longer compared to alternative techniques like primary closure (partial or complete). however considering the complexness of these surgical techniques, consumption of patient resources in hospital, long time keeping inhospital after operation, uses of antibiotics for long time and the complications are common after surgical technique like wound dehiscence, infection with pus collection and recurrence.¹⁹

Additional utility of laser optical device is that it can be used and selected to manage the chronic PNS when working on a gap without presence of any collection.¹⁹

In our study, we have some points of weakness first; lack of comparison with more classical techniques also, recent device like diode optical device 1470 nm, second; long term follow up was not complete, finally; number of patients are not enough for accuracy of results and needs more studies.

Conclusion

Laser pilonidoplasty is a simple, easy, reasonable, feasible, reproducible technique and competitive alternative to other surgical intervention.

It is accompanied by a reduction in pain, reducing hospital stay, minimal tissue injury, with early back to work and with lower recurrence rate.

In spite of the surgical approach is still the standard modality for pilonidal sinus management, this study suggested laser pilonidoplasty procedure as the first-line management of PNS patients who have no history of infection and have only 1-5 sinuses. We welcome larger, preferably randomized and controlled trials to confirm the results of this study in the future.

References

1. Galan N, Akin M, Gokbayir H. Treatment of Pilonidal Sinus using Limberg flap after rhomboid excision. *Diseases of the colon & rectum*. 2015;10(9):945-8.
2. Turgut HT, Yucak A, Yildiz T, Ilce Z, Elmas B. Teenagers Risk factors for pilonidal sinus. *The Journal of India in Pediatrics*. 2017;84(2):134-8.
3. Søndena K, Søreide JA, Andersen E, Nesvik I. Patient characteristics and symptoms in chronic pilonidal disease. *International journal of colorectal disease*. 1995;10(1):39-42.
4. Wilhelm A. A new technique for sphincter-preserving peri-anal fistula using a radial emitting laser probe. *Techniques in coloproctology*. 2011;15(4):445-9.
5. Zimmet SE, Min RJ, Isaacs MN, Forrestal MD. Endo-venous laser ablation of the incompetent great saphenous vein. *Journal of Vascular and Interventional Radiology*. 2001;12(10):1167-71.
6. Salfi R, Giamundo P, Tibaldi L, Geraci M, Valente M, Murru L. Laser Haemrridoplasty technique vs ligation of rubber band: a randomized trial comparing 2 mini-invasive treatments for third-degree hemorrhoids. *Diseases of the Colon & Rectum*. 2011;54(6):693-8.
7. Azar Z, inventor; Azar, Zion, assignee. Method of selective photothermolysis. *United States patent US 5,759,200*. 1998.
8. Maloku H, Lazovic R, Gashi Z, Juniku-Shkololli A, Islami H. Laser hemorrhoidoplasty vs surgical hemorrhoidectomy: a trial comparing 2 treatments for hemorrhoids of third and fourth degree. *Acta Informatica Medica*. 2014;22(6):365.
9. Walls R, Marx J, Hockberger R. Rosen's Emergency Medicine and Clinical Practice E-Book. Elsevier Health Sciences; Elsevier; 2013.
10. Lindholt-Jensen CS, Beyer M, Lindholt JS, Lindholt JS. Nd-YAG laser treatment of chronic pilonidal sinus. *Lasers in medical science*. 2012;27(2):505-8.
11. Khan MA, Siddiqui SS. Pilonidal sinus: Following the Aristotelian middle. *Pak J Med Sci*. 2008;24:845-8.
12. Oram Y, Koyuncu E, Kahraman F, Karuncaoglu YE. Evaluation of 40 patients with chronic pilonidal disease treated with laser epilation after surgery. *Dermatologic Surgery*. 2010 ;36(1):88-91.
13. Soliman M, Saafan A, El Kharbotly A. Uses of diode laser 980 nm in management of oral lichen planus : a clinical study. *Egyptian dermatology online journal*. 2005;1(1):3.
14. Hollberg L, Oates CW, Hoyt CW, Wilpers G, Barber ZW, Oskay WH, Diddams SA, Bergquist JC. Optical frequency/wavelength references. *Journal of Physics B: Molecular, Atomic and Optical Physics*. 2005;38(9):S469.
15. Birang, R., Yaghini, J., Adibrad, M., Kiany, S., Mohammadi, Z., & Birang, E. The Effects of Diode Laser (980 nm Wavelength) and Chlorhexidin Gel in the Treatment of Chronic Periodontitis. *Journal of Lasers in Medical Sciences*; 2011, 2(4).
16. <https://doi.org/10.22037/jlms.v2i4.2389> Dessily M, Ralea S, Charara F, Allé JL. Pilonidal sinus management with a radial laser probe: technique and first Belgian experience. *Acta Chirurgica Belgica*. 2017;117(3):164-8.
17. Georgiou GK. Outpatient laser treatment of primary pilonidal disease: the PiLaT technique. *Techniques in coloproctology*. 2018;22(10):773-8.
18. Pappas AF, Christodoulou DK. A new minimally invasive treatment of pilonidal sinus disease with the use of a diode laser: a prospective large series of patients. *Colorectal Disease*. 2018;20(8):O207-14.
19. Lewis AT, Benedetto AV. Sacrococcygeal Pilonidal sinus managed by hair epilation using diode laser 800 nm and review of the literature. *Dermatologic surgery*. 2005 ;31(5):587-91.